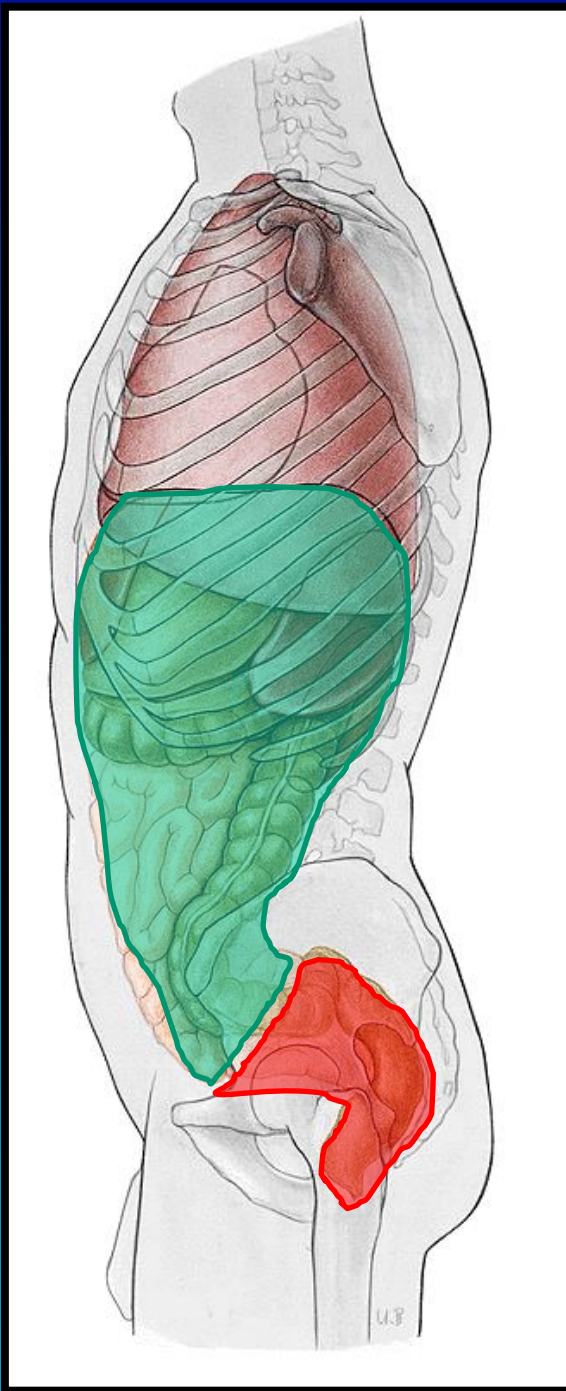
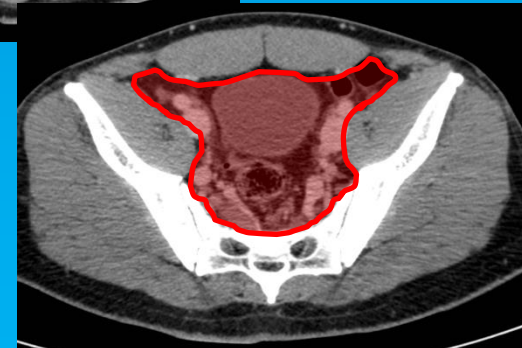
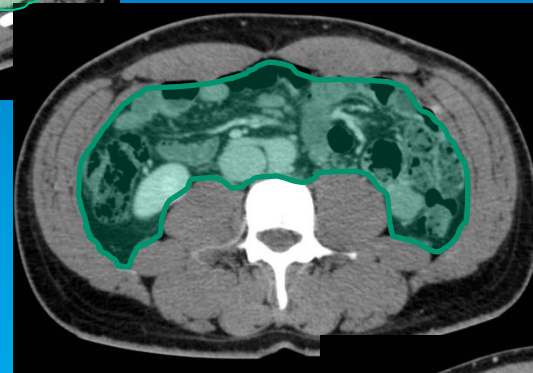
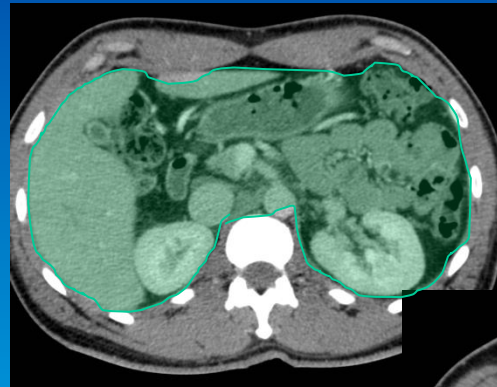
# Abdomen 1

*Michel Bach Hellfritzsch*

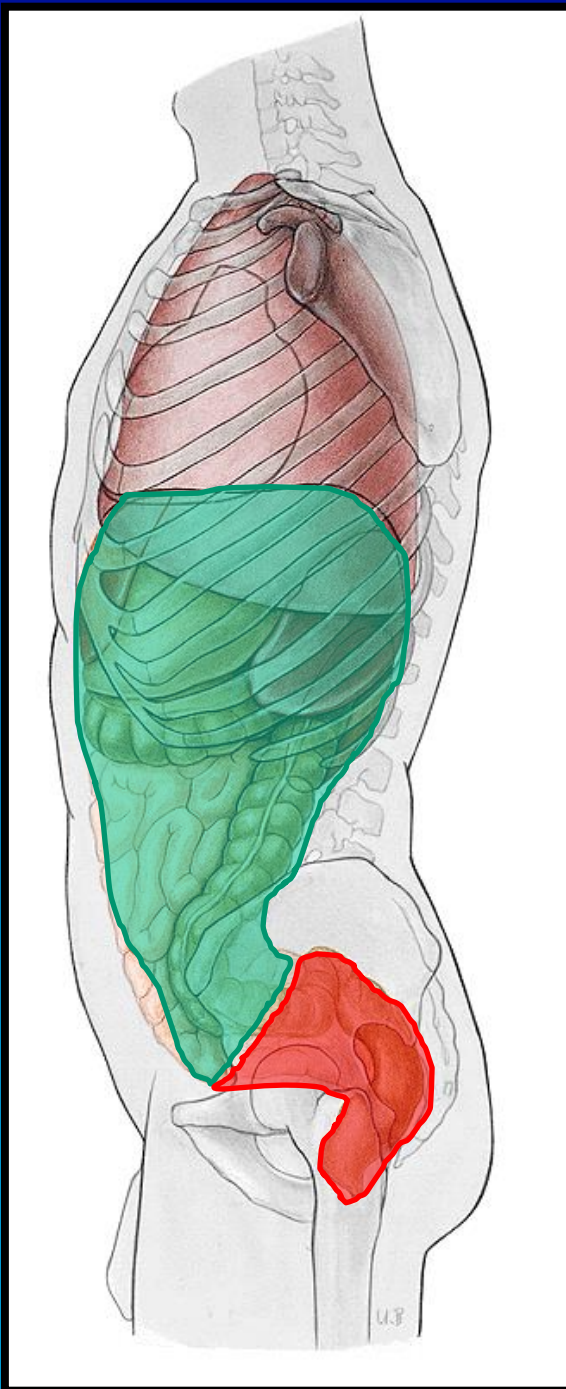
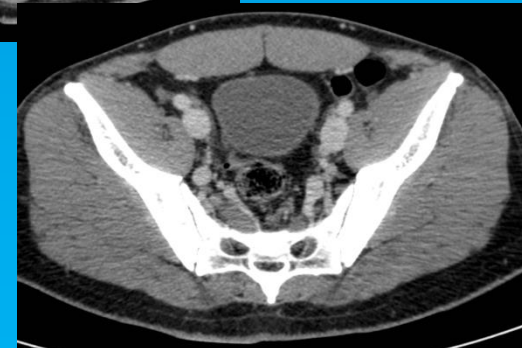
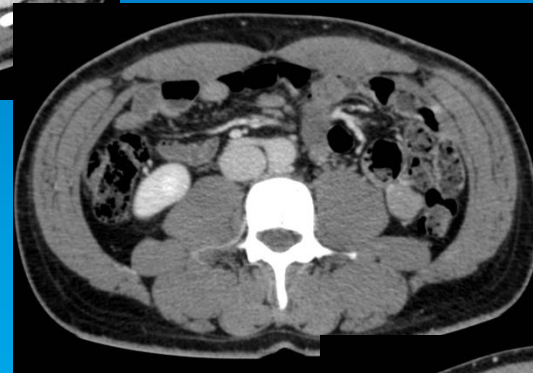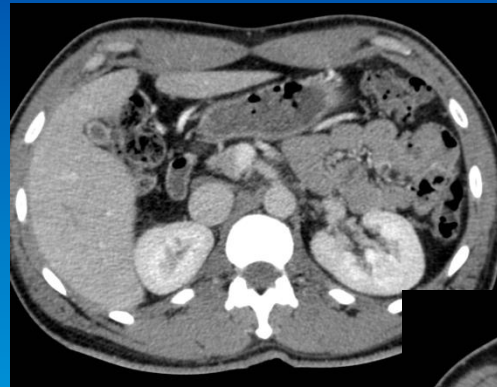
## Cavitas abdominalis:

- Cavitas abdominalis propria
  - Linea terminalis
- Cavitas pelvis



## Cavitas abdominalis:

- Cavitas abdominalis propria
  - Linea terminalis
- Cavitas pelvis

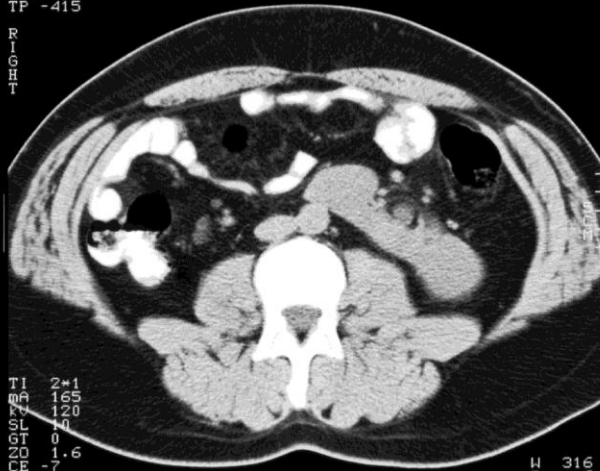


# Bughulens afgrænsninger.

Image 26  
15:18:30  
Scan 26  
TP -415

ANTERIOR

R  
I  
G  
H  
T



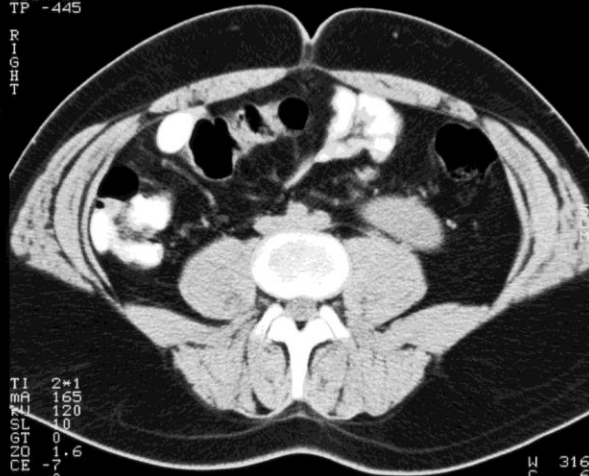
TI 2+1  
MA 165  
SL 120  
NG 0  
GT 1.6  
CR -7  
CE 0  
AB 7555 oral  
AUG-00

W 316  
M -681

Image 27  
15:19:22  
Scan 27  
TP -445

ANTERIOR

R  
I  
G  
H  
T



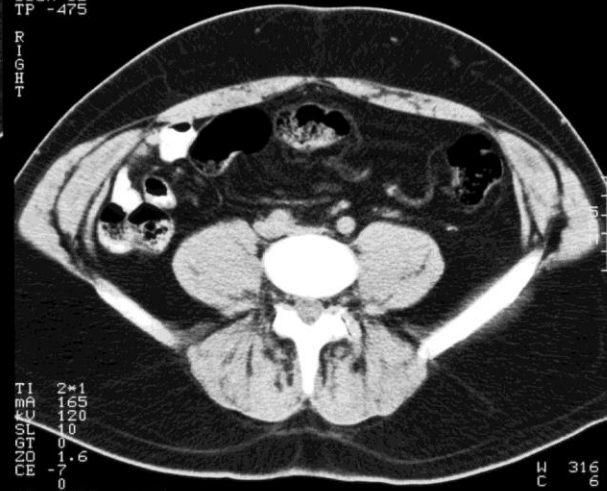
TI 2+1  
MA 165  
SL 120  
NG 0  
GT 1.6  
CR -7  
CE 0  
AB 7555 oral  
AUG-00

W 316  
M -681

Image 28  
15:19:32  
Scan 28  
TP -475

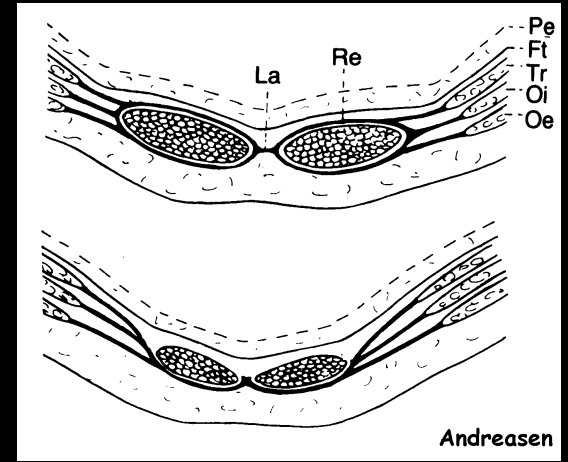
ANTERIOR

R  
I  
G  
H  
T



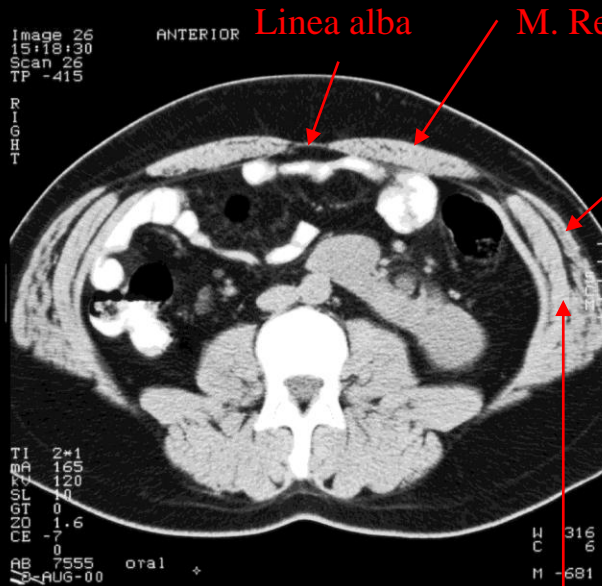
TI 2+1  
MA 165  
SL 120  
NG 0  
GT 1.6  
CR -7  
CE 0  
AB 7555 oral  
AUG-00

W 316  
M -681



Andreasen

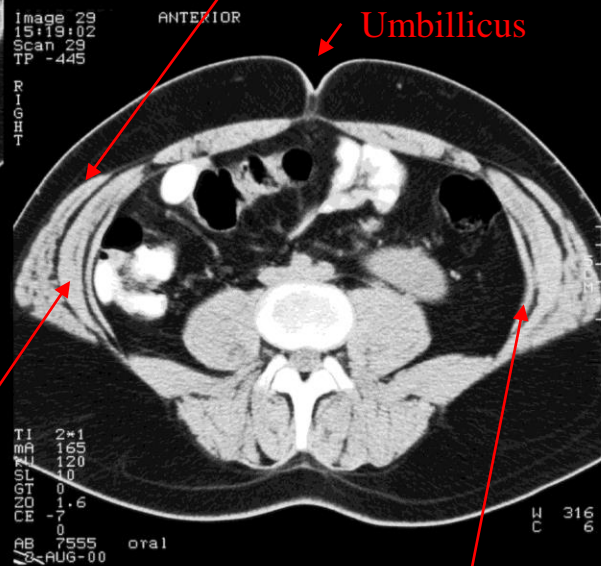
CT



Linea alba

M. Rectus abdominis

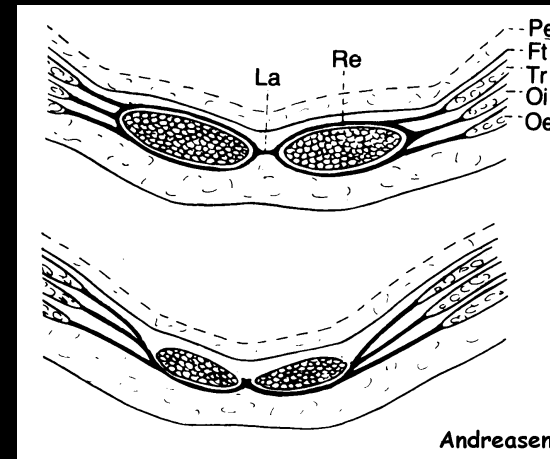
M. obliquus externus abdominus



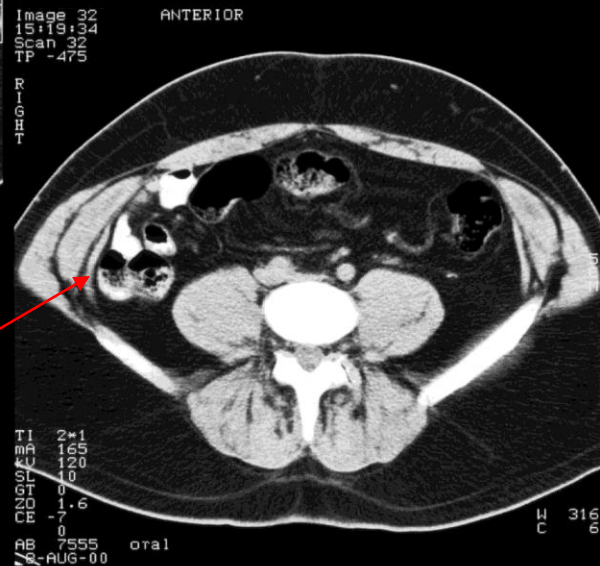
Umbilicus

M. obliquus internus abdominus

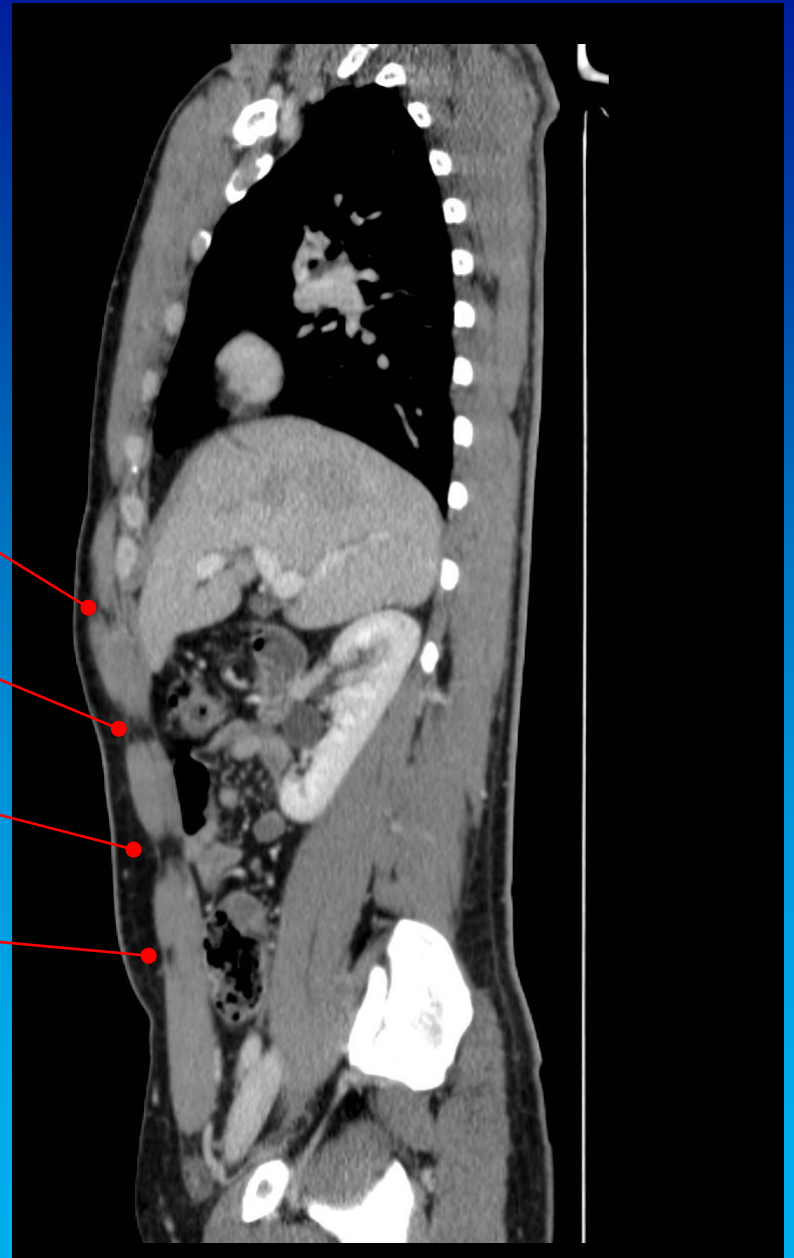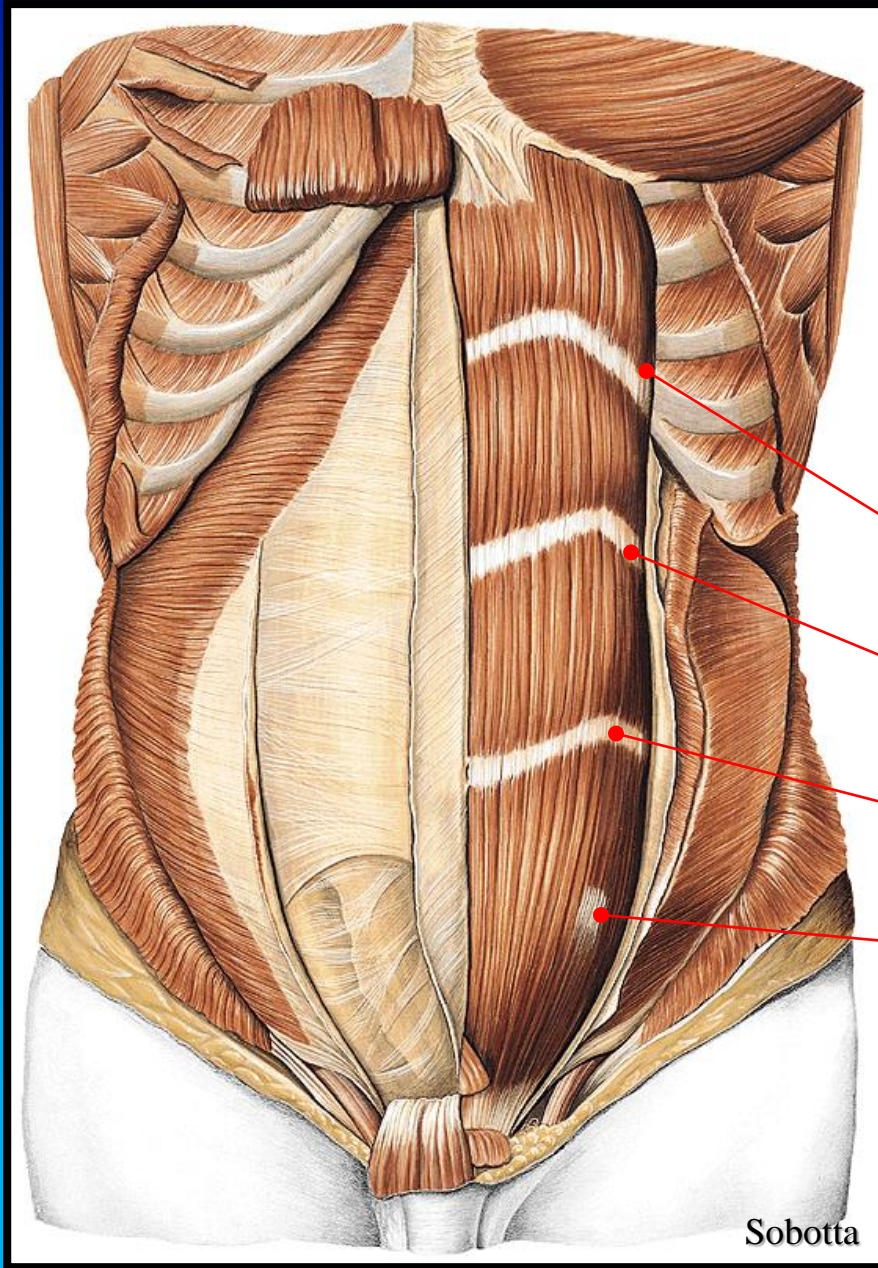
M. transversus abdominus



Andreasen



CT

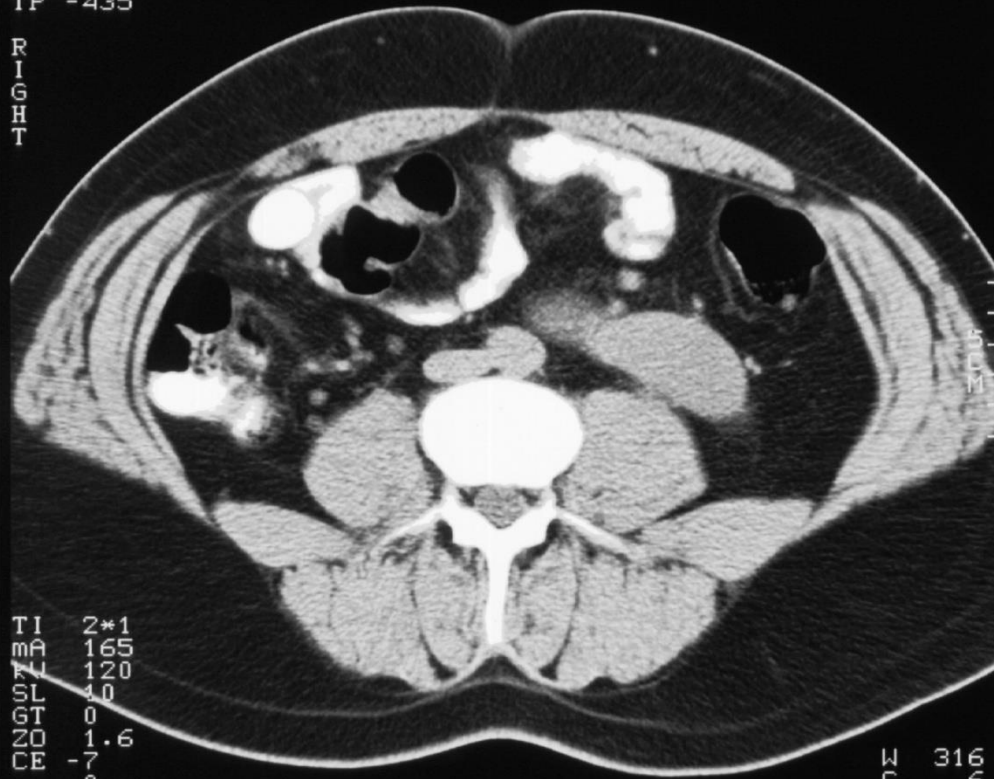


Sobotta

Image 28  
15:18:52  
Scan 28  
TP -435

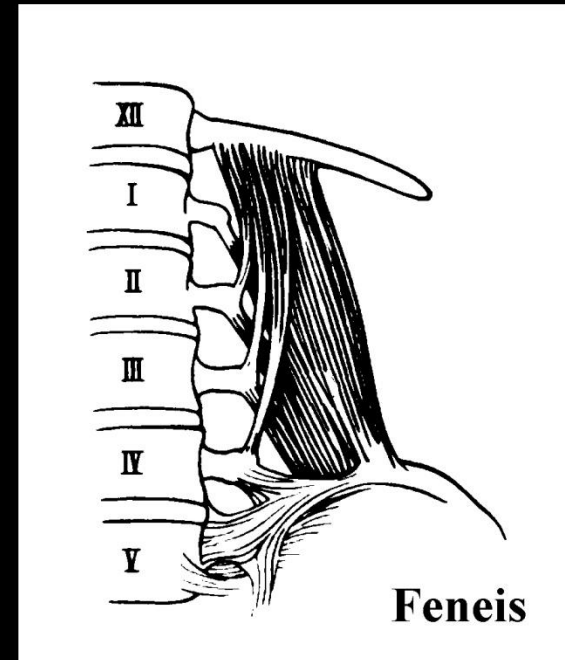
ANTERIOR

R  
I  
G  
H  
T



TI 2\*1  
MA 165  
KV 120  
SL 10  
GT 0  
ZD 1.6  
CE -7  
AB 7555 oral  
2-AUG-00

W 316  
C 6



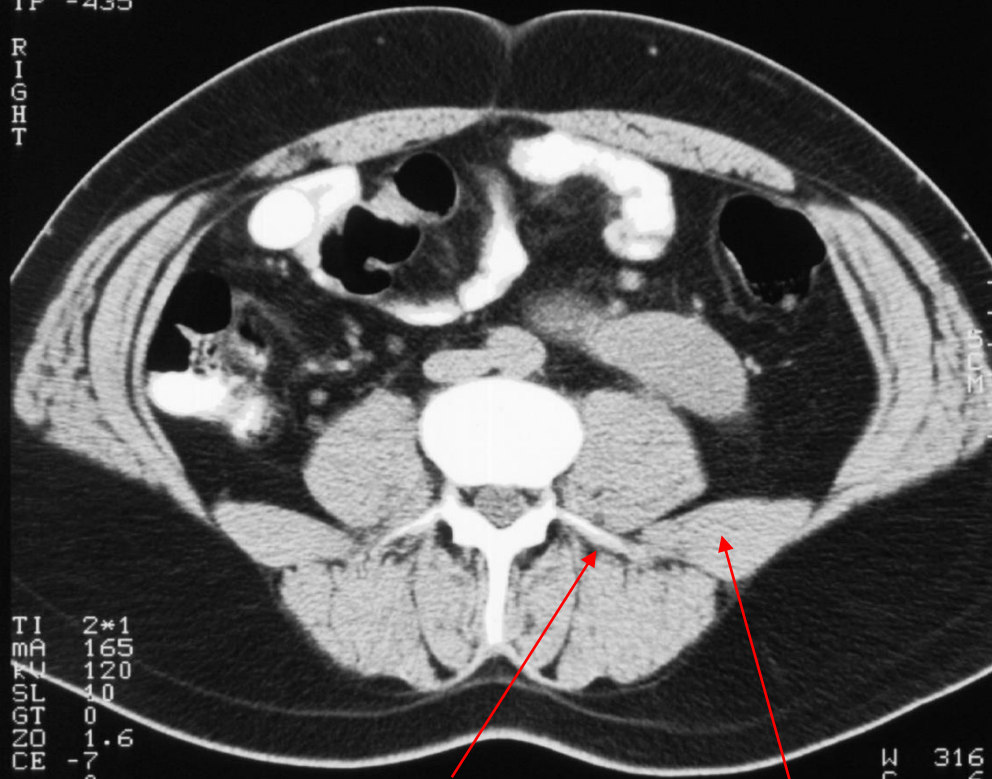
CT



Image 28  
15:18:52  
Scan 28  
TP -435

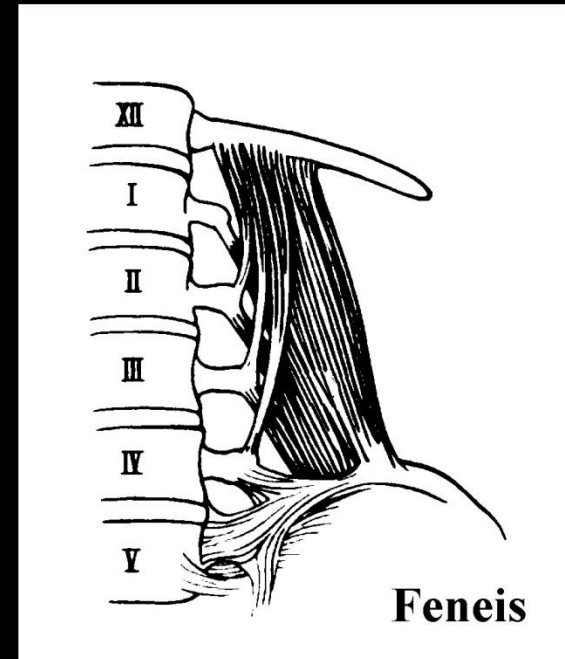
ANTERIOR

R  
I  
G  
H  
T



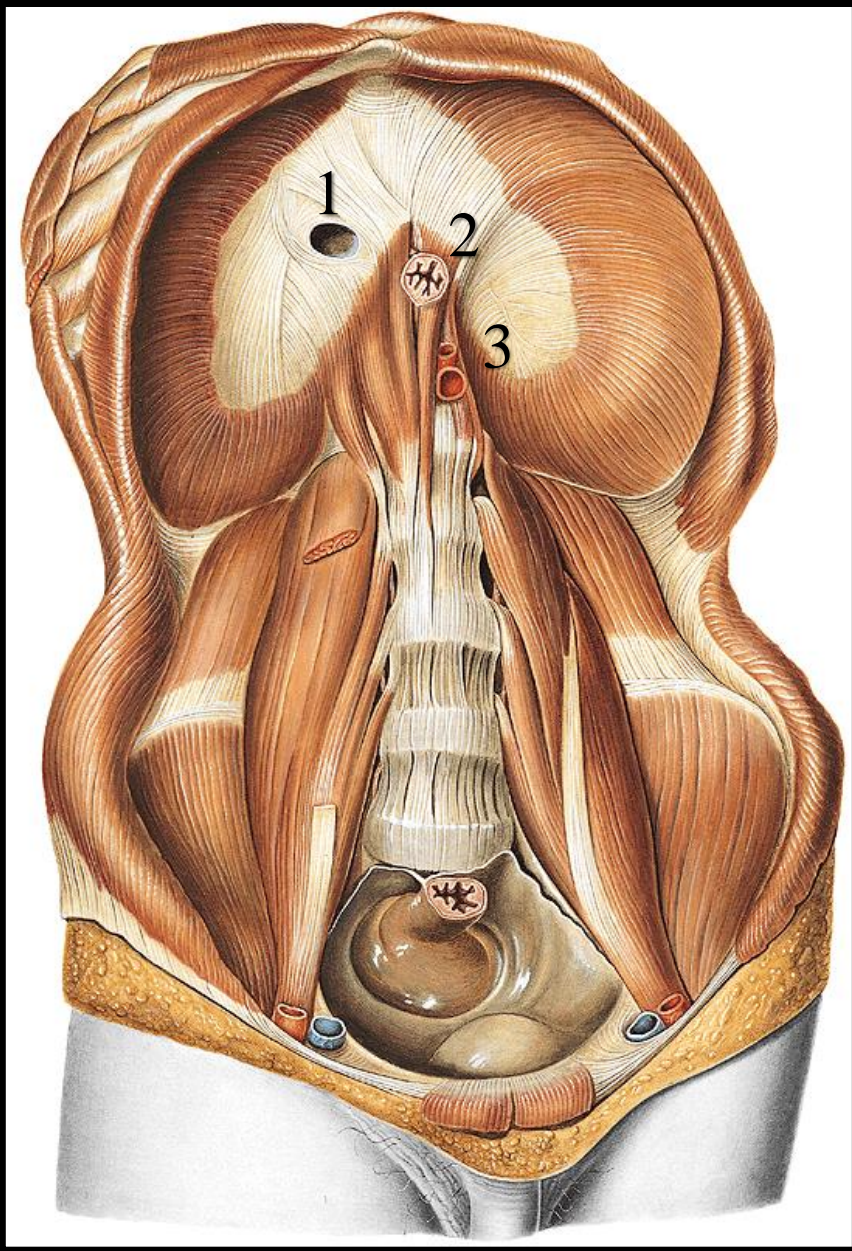
oral **Processus transversus**

**M. quadratus lumborum**

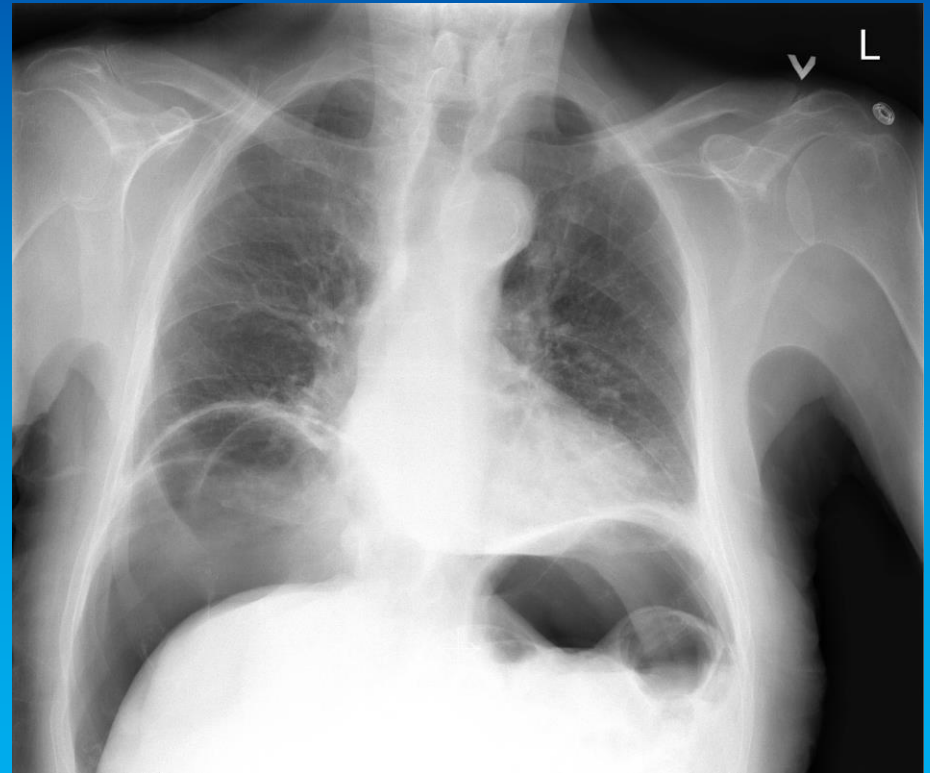


CT

# Diaphragm



- 1) Foramen venae cavae
- 2) Hiatus esophageus
- 3) Hiatus aorticus



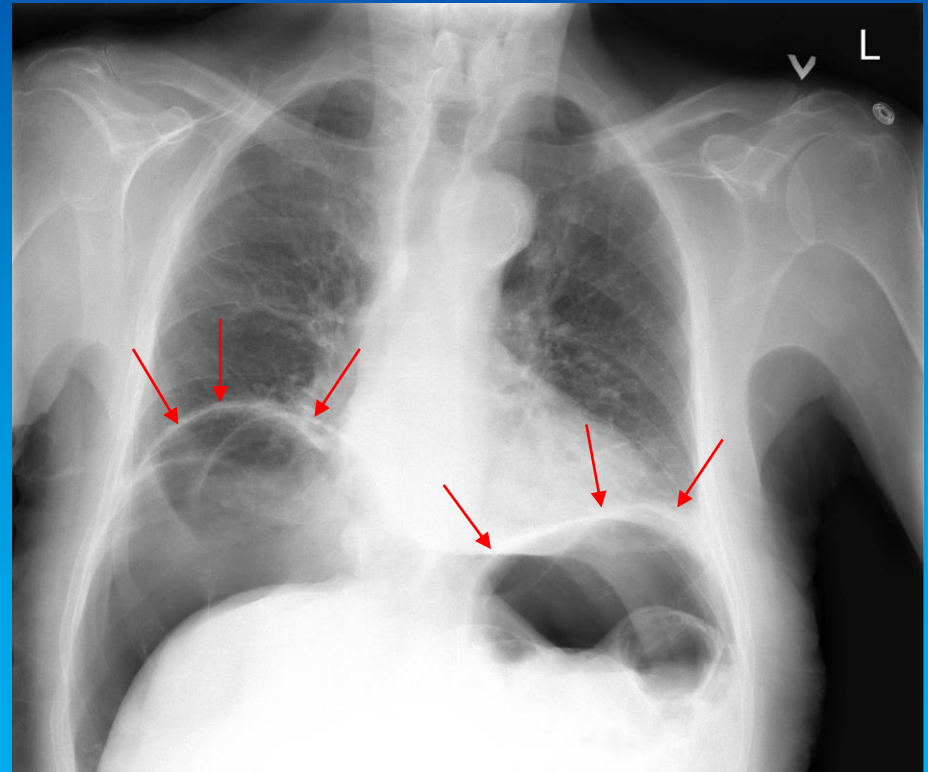
Pneumoperitoneum after ERCP

# Diaphragma

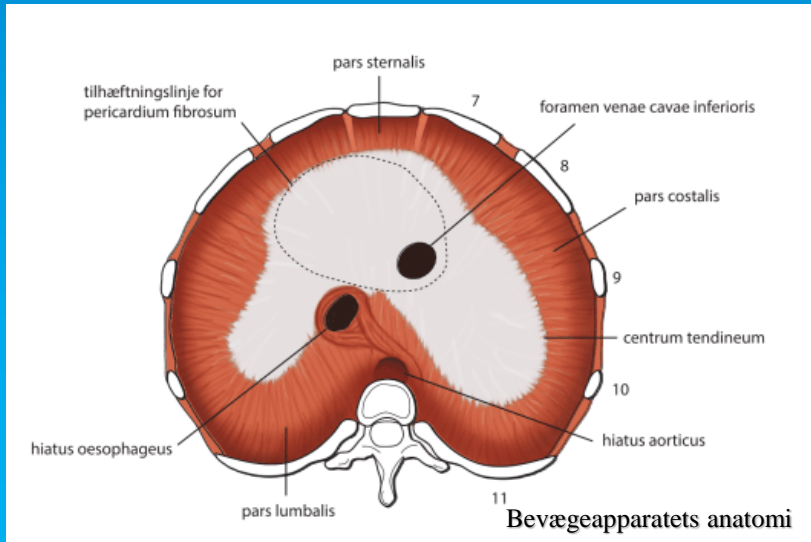
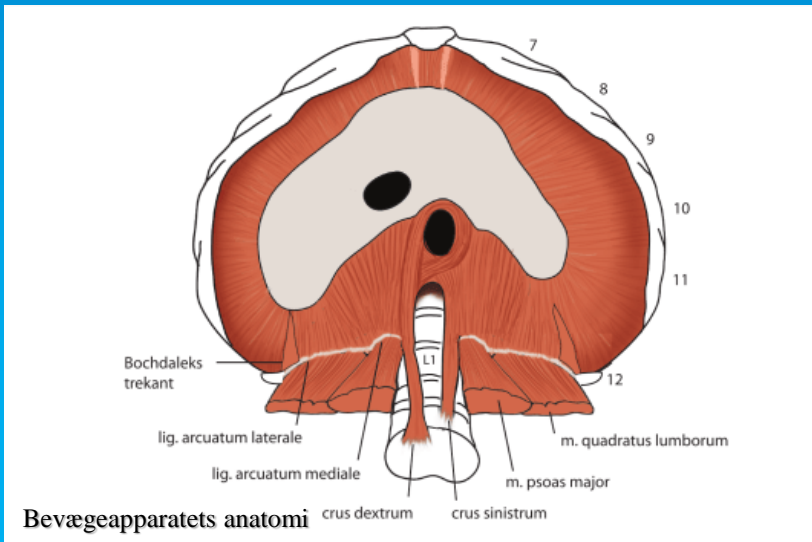
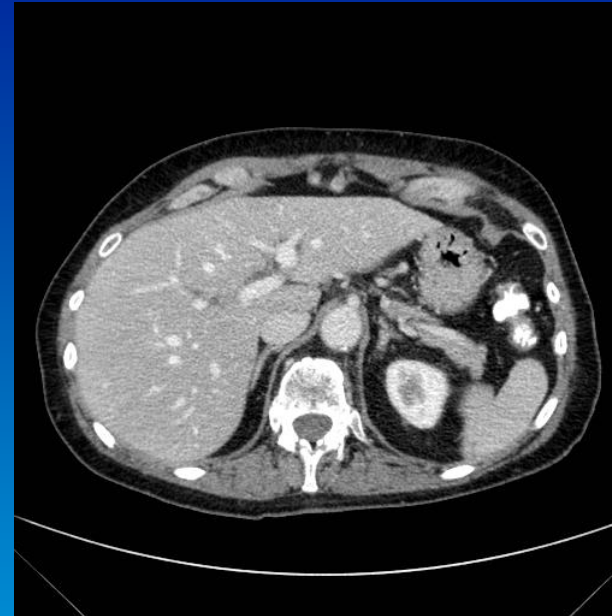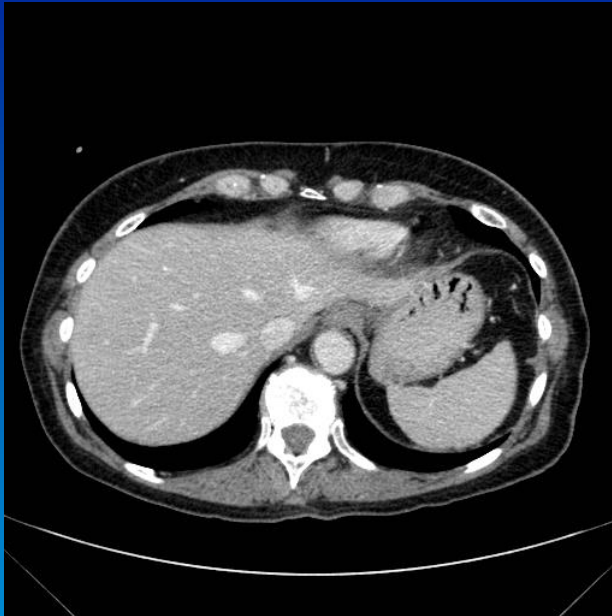
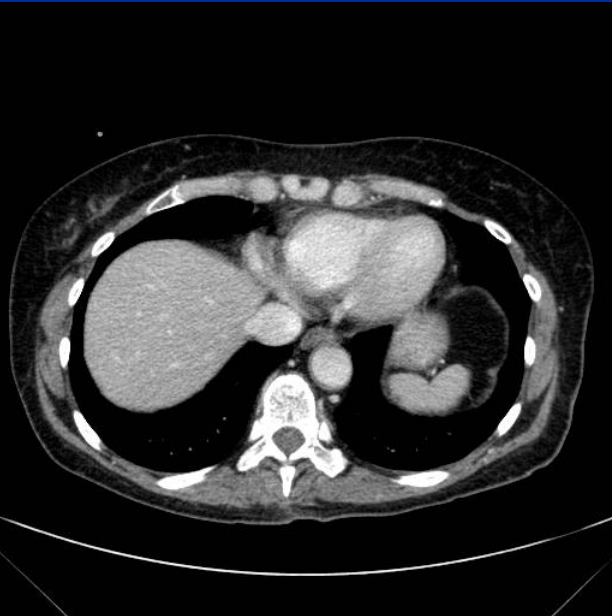
Under normale omstændigheder, ses ikke pneumoperitoneum. Der skal således altid være en god forklaring på fundet, eksempelvis de første dage efter en abdominal operation. Ellers må man mistænke perforation af et hulorgan, (ventrikel, tynd- eller tyktarm). Luften i sig selv vil blive resorberet igen, men der kan også lække tarmindehold med bakterier ud i peritoneum, således der opstår betændelse kaldet peritonit.

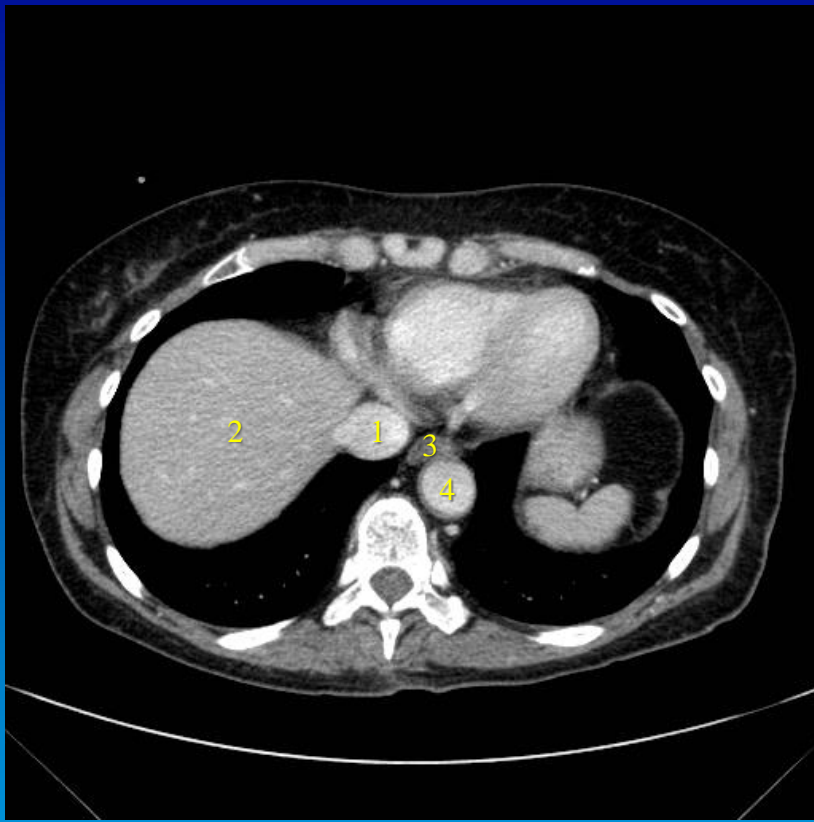
På den foreliggende stående røntgenoptagelse af thorax, ses diaphragma kuplerne tydeligt, da der er de luftholdige lunger kranielt og luften i peritoneum kaudalt herfor.

Pneumoperitoneum, luft i bughinden, opstået efter en kikkertundersøgelse af galdevejene og pancreas (Endoskopisk retrograd cholangio-pancreaticoskopi).

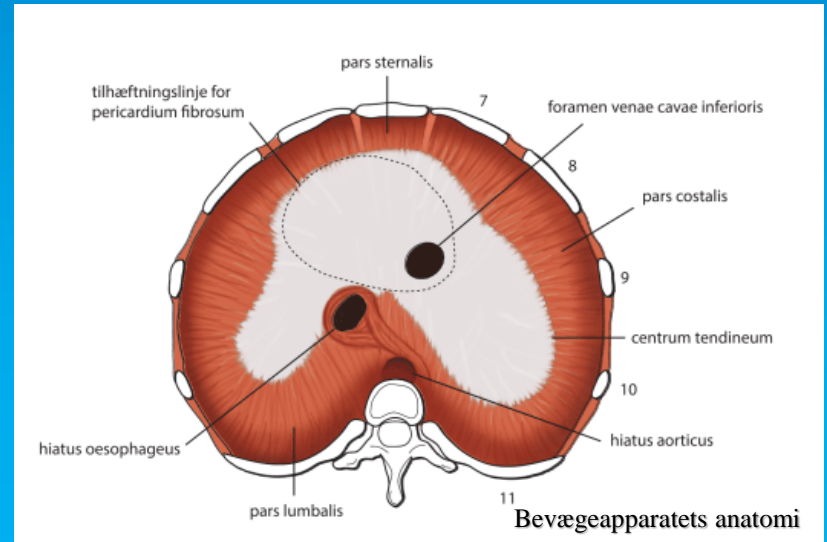
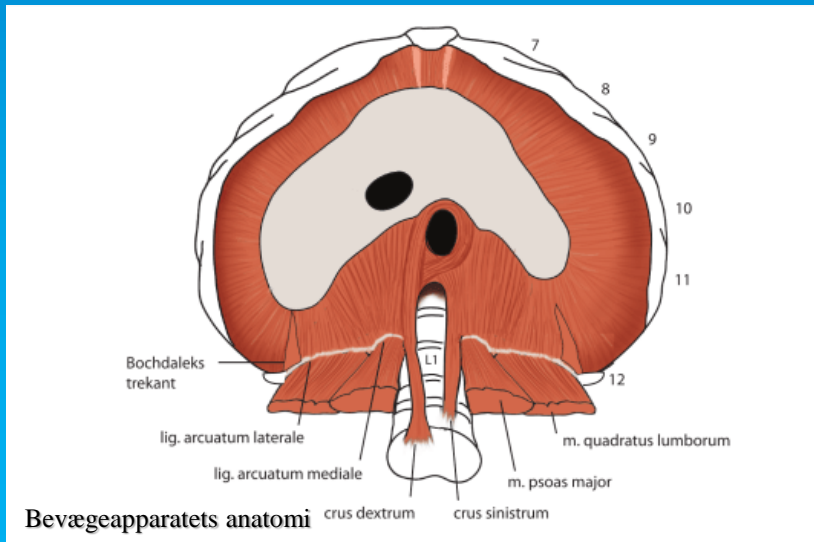


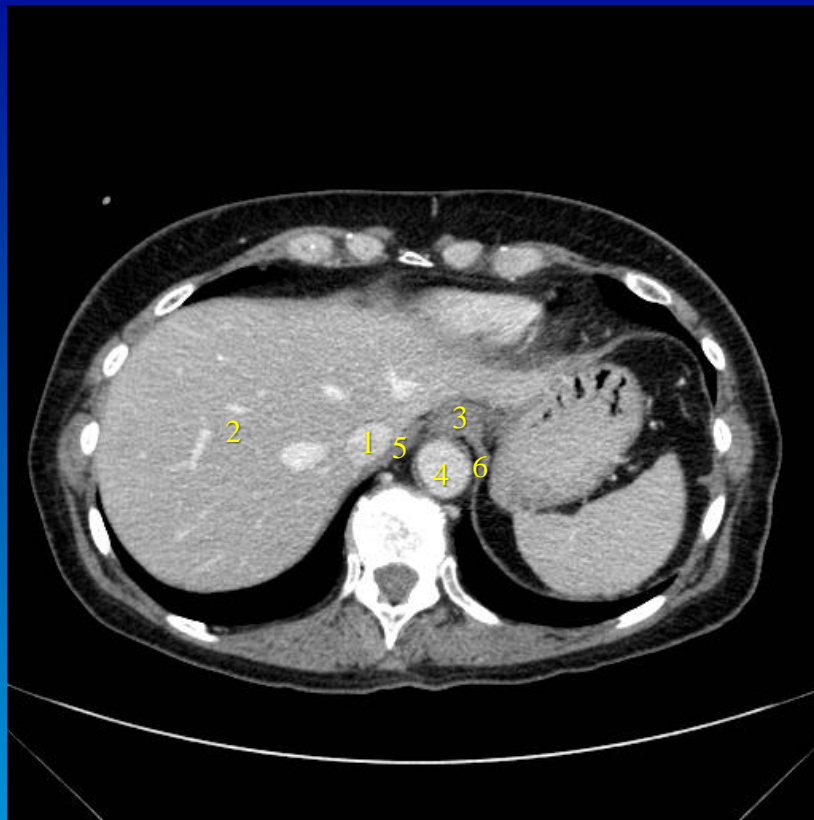
Pneumoperitoneum efter ERCP



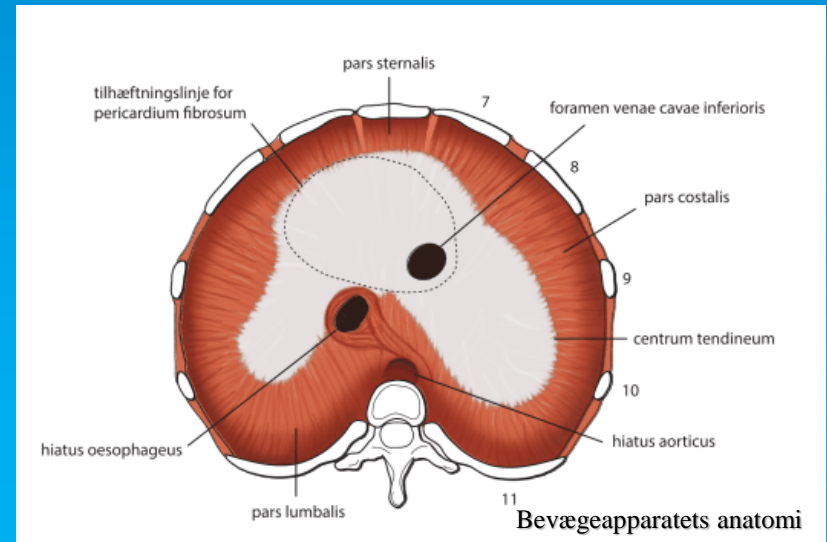
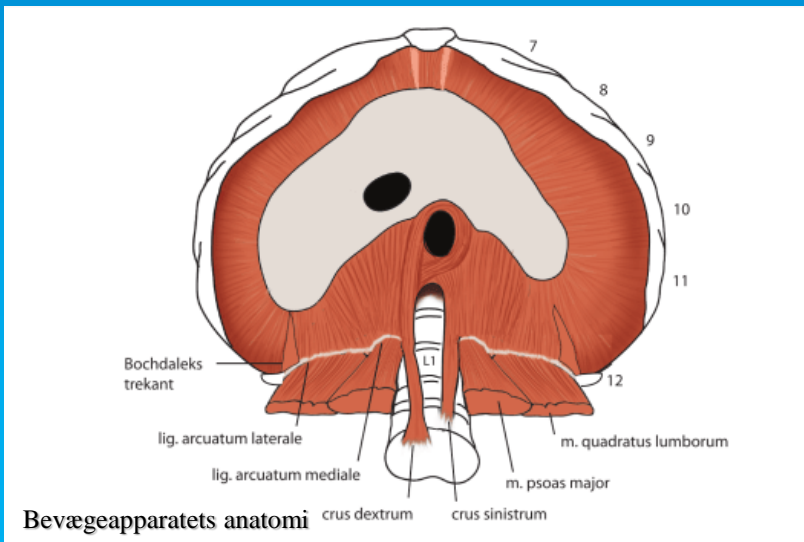


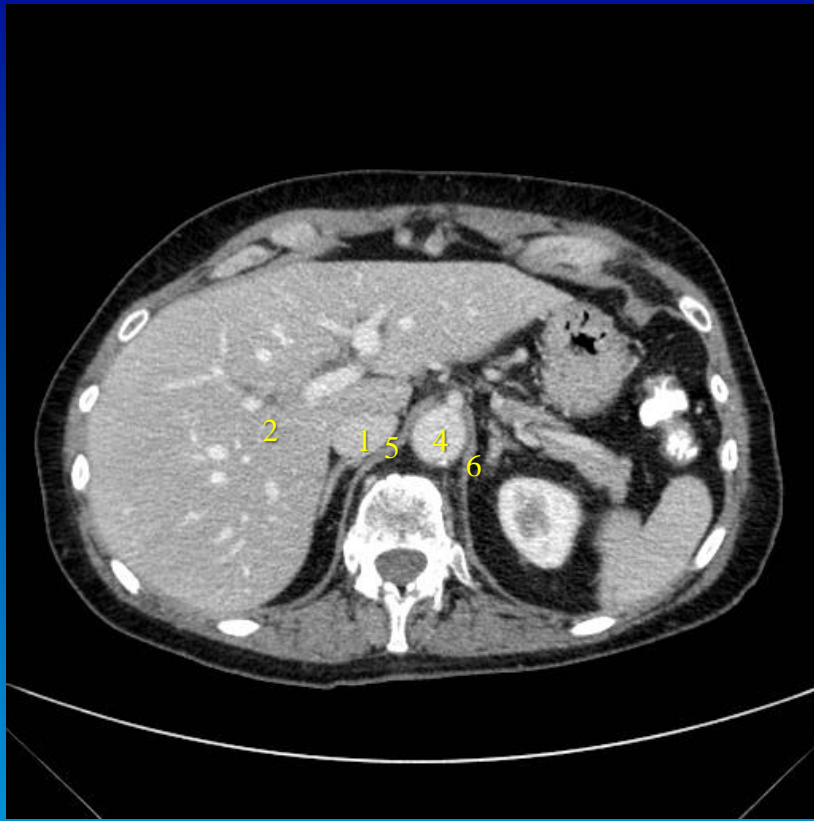- 1) V. cava inf.
- 2) Hepar
- 3) Esophagus
- 4) Aorta
- 5) Crus dextrum
- 6) Crus sinistrum



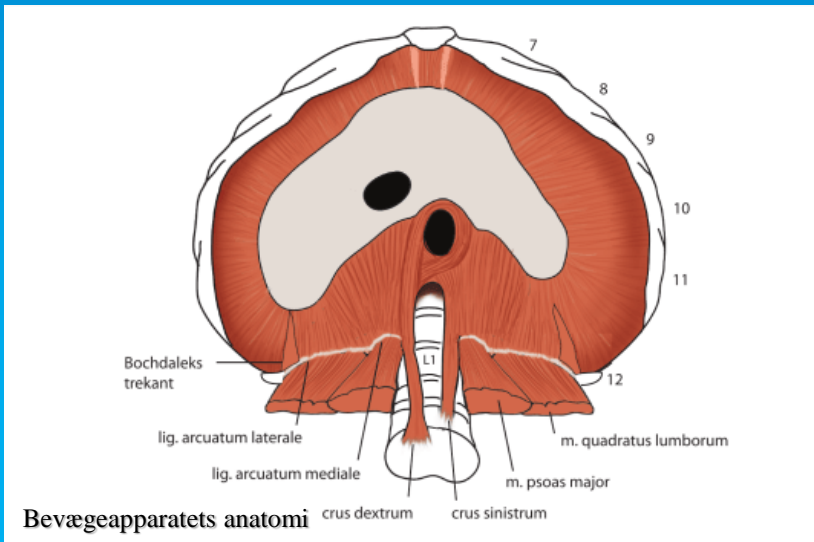


- 1) V. cava inf.
- 2) Hepar
- 3) Esophagus
- 4) Aorta
- 5) Crus dextrum
- 6) Crus sinistrum

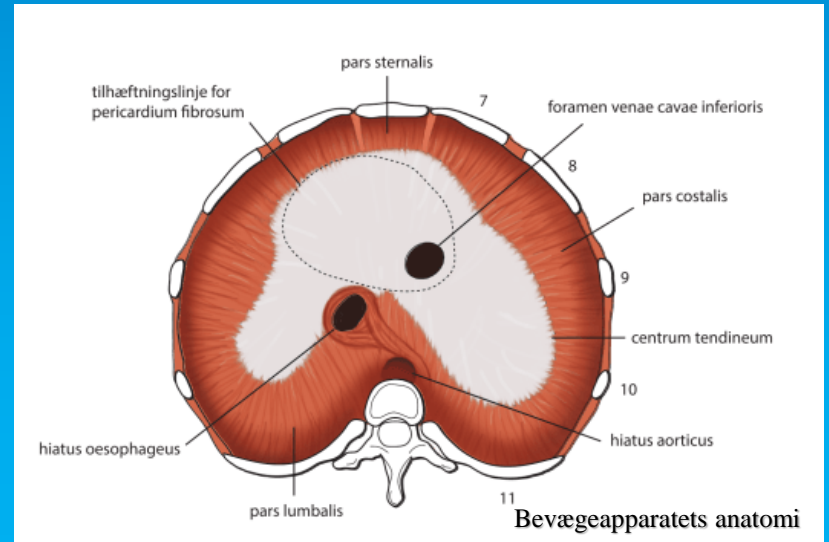




- 1) V. cava inf.
- 2) Hepar
- 3) Esophagus
- 4) Aorta
- 5) Crus dextrum
- 6) Crus sinistrum



Bevægeapparatets anatomi



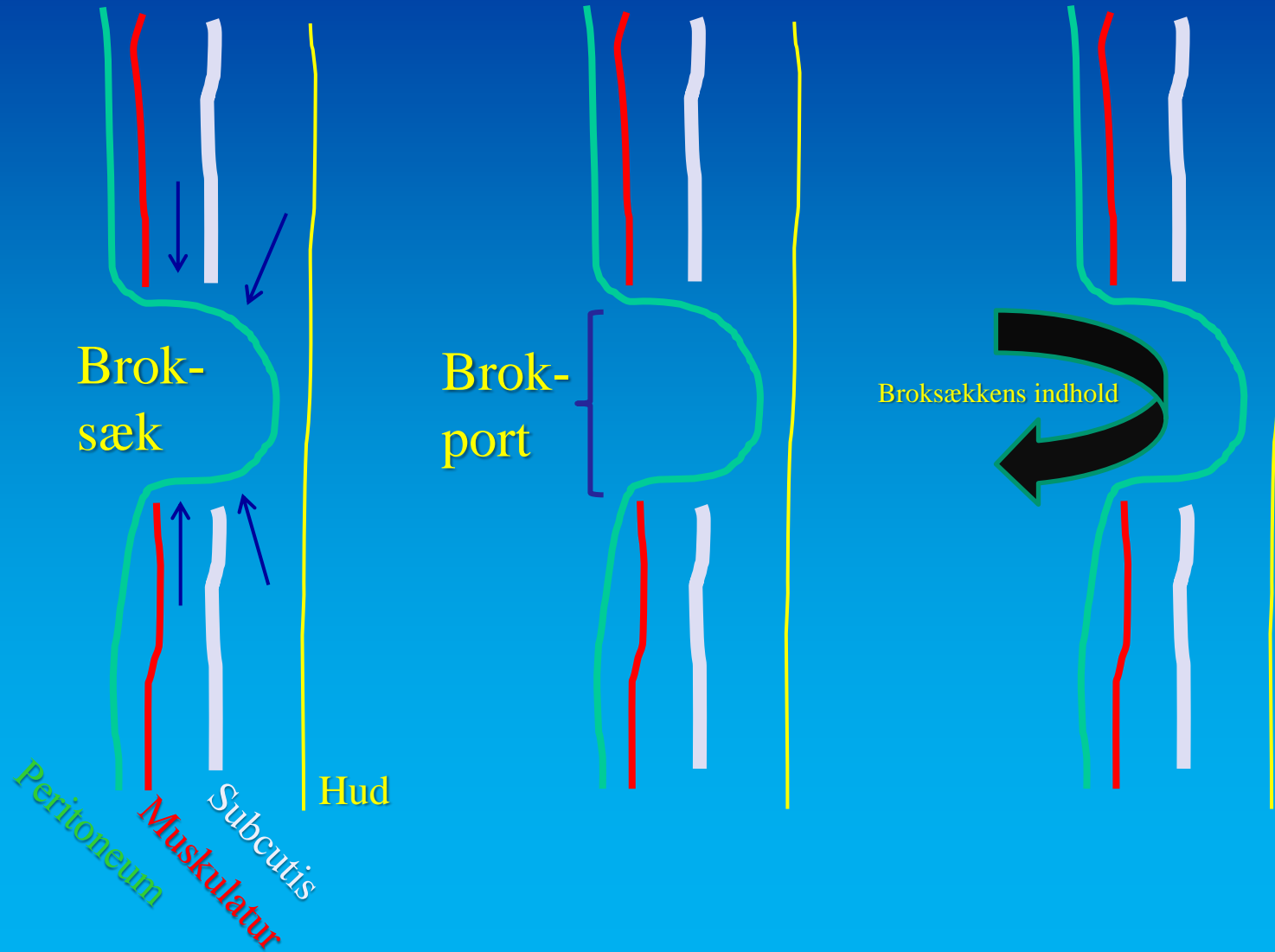
Bevægeapparatets anatomi

# Hernia (Brok)

Abnorm fremtrængen af et organ (eller en del deraf) gennem væggen af en legemshule, almindeligvis peritonealhulen

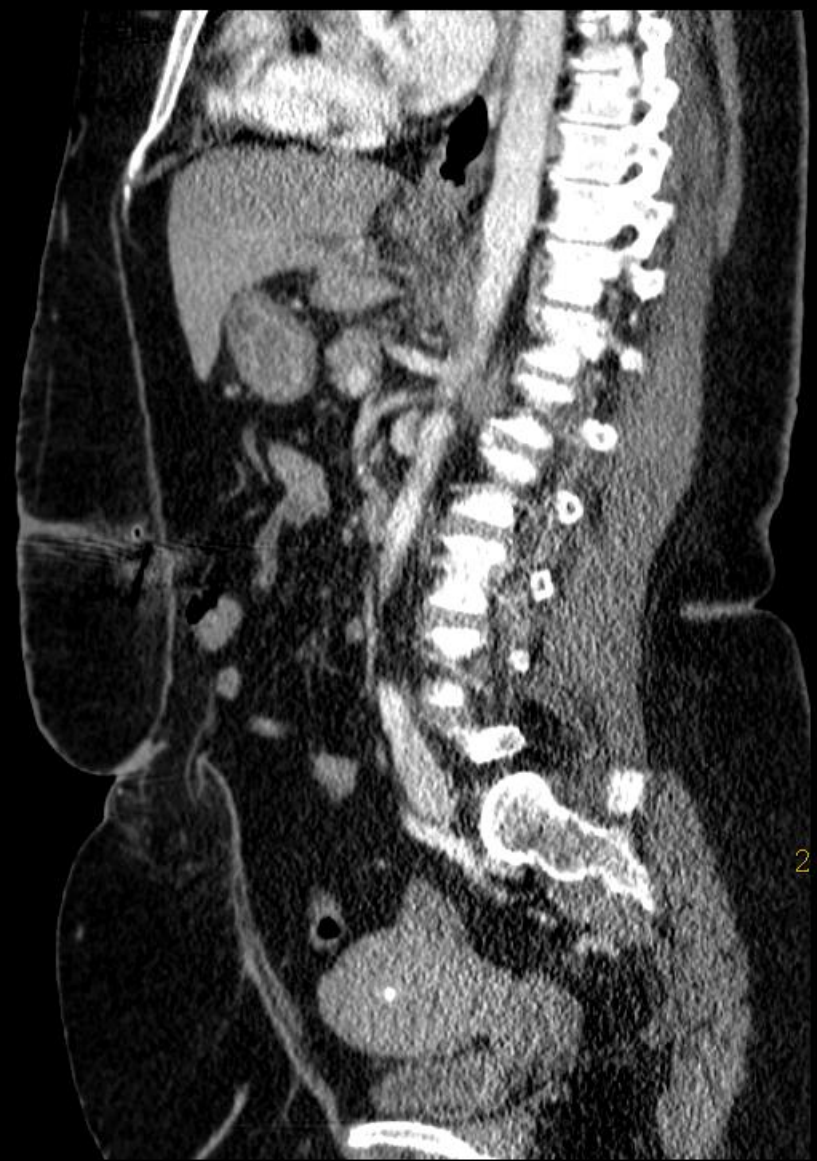

# Hernia (Brok)

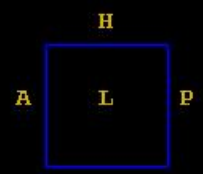


Meget adipøs kvinde med  
umbilicalhernie

A



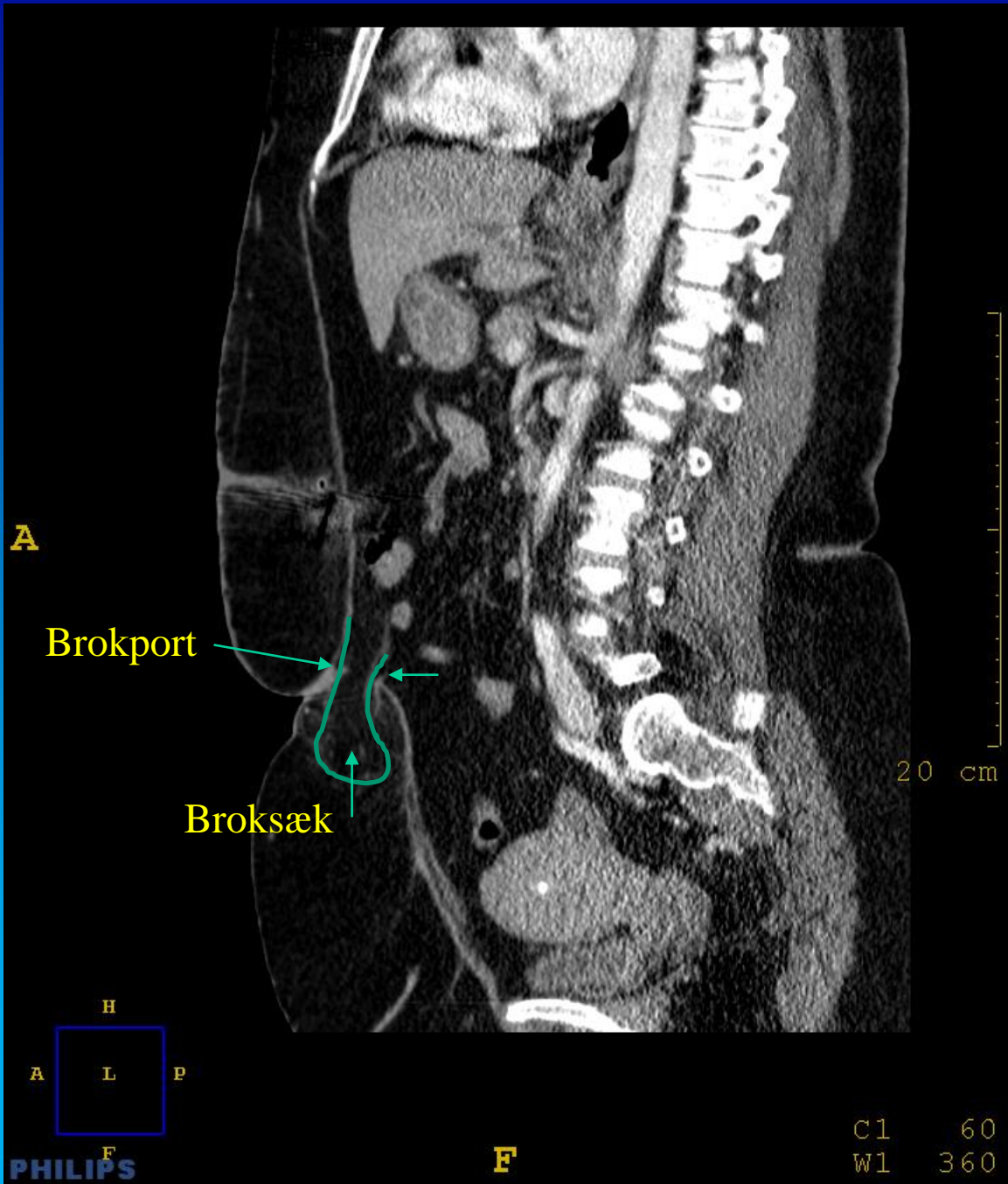
20 cm

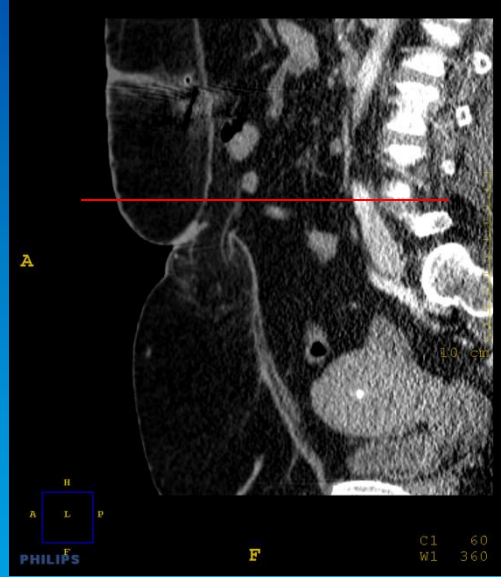
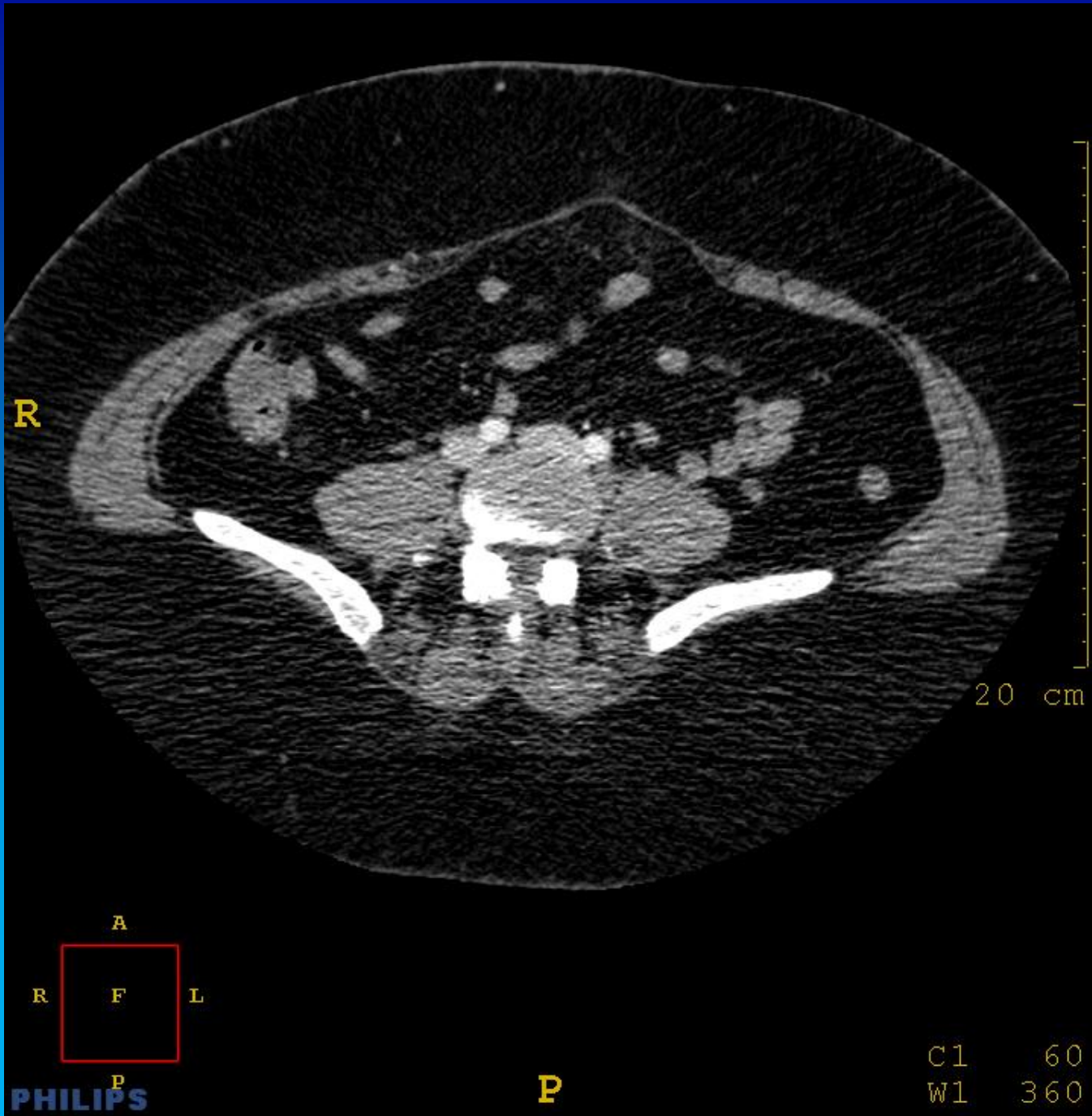

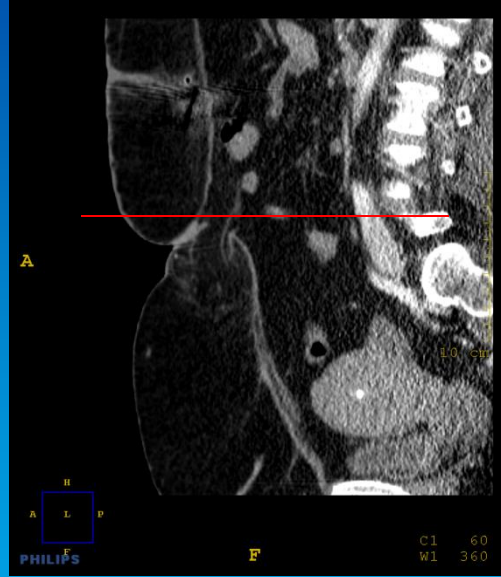
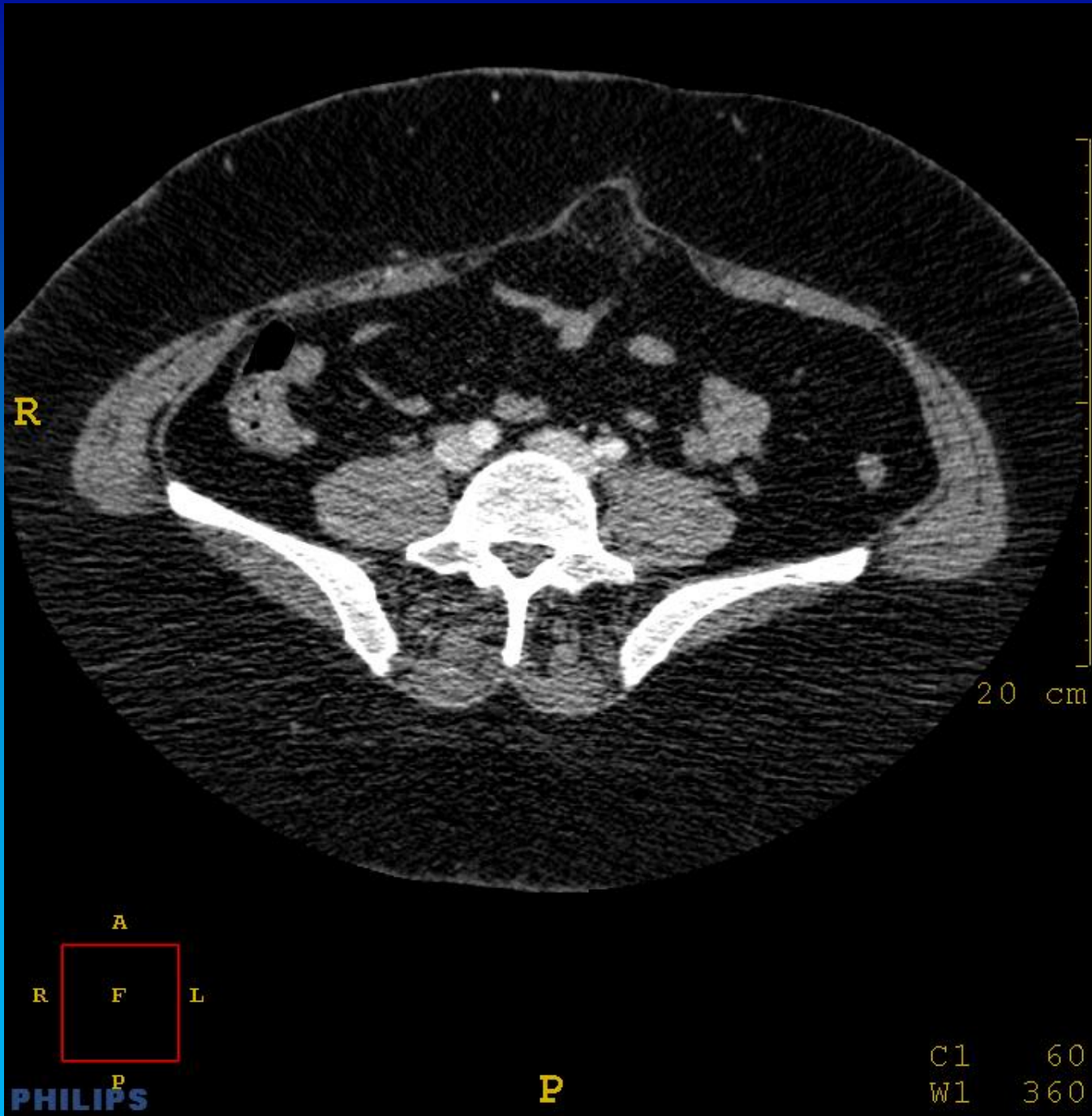
PHILIPS

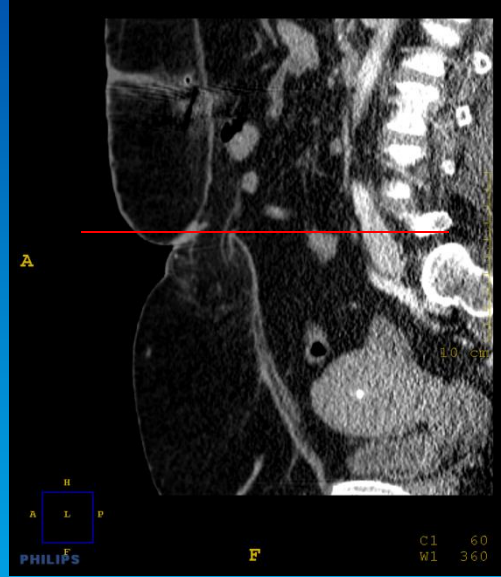
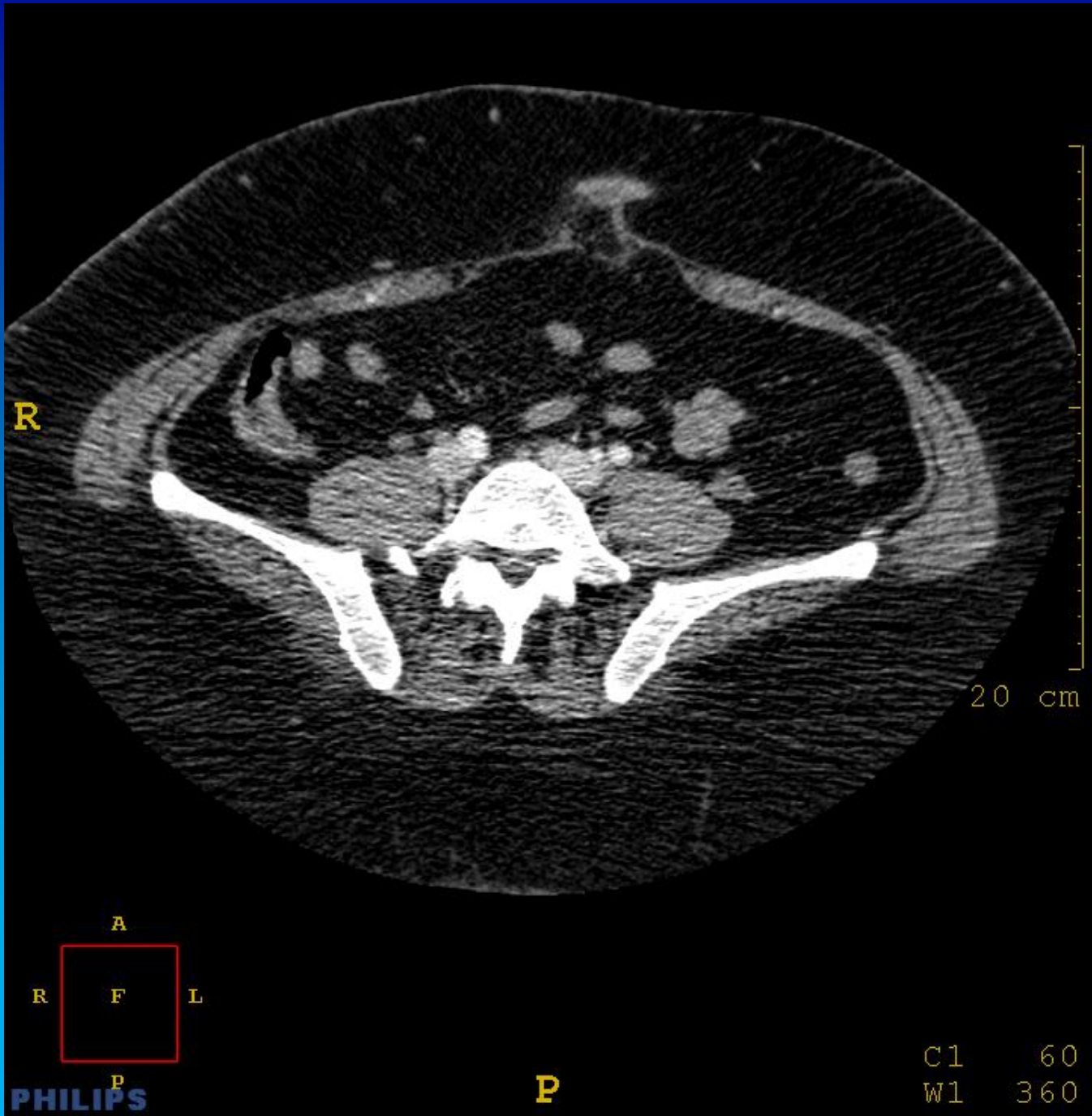
F

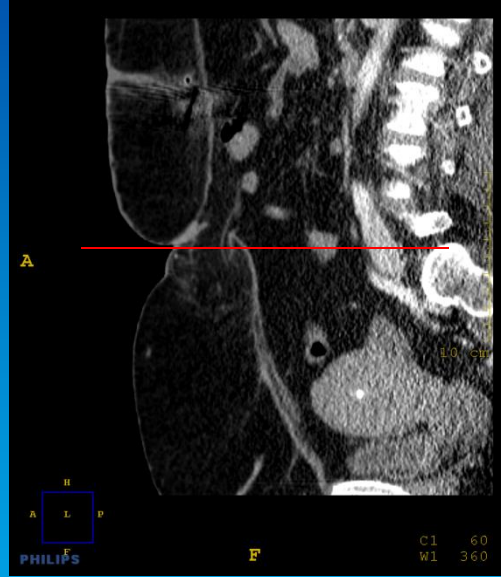
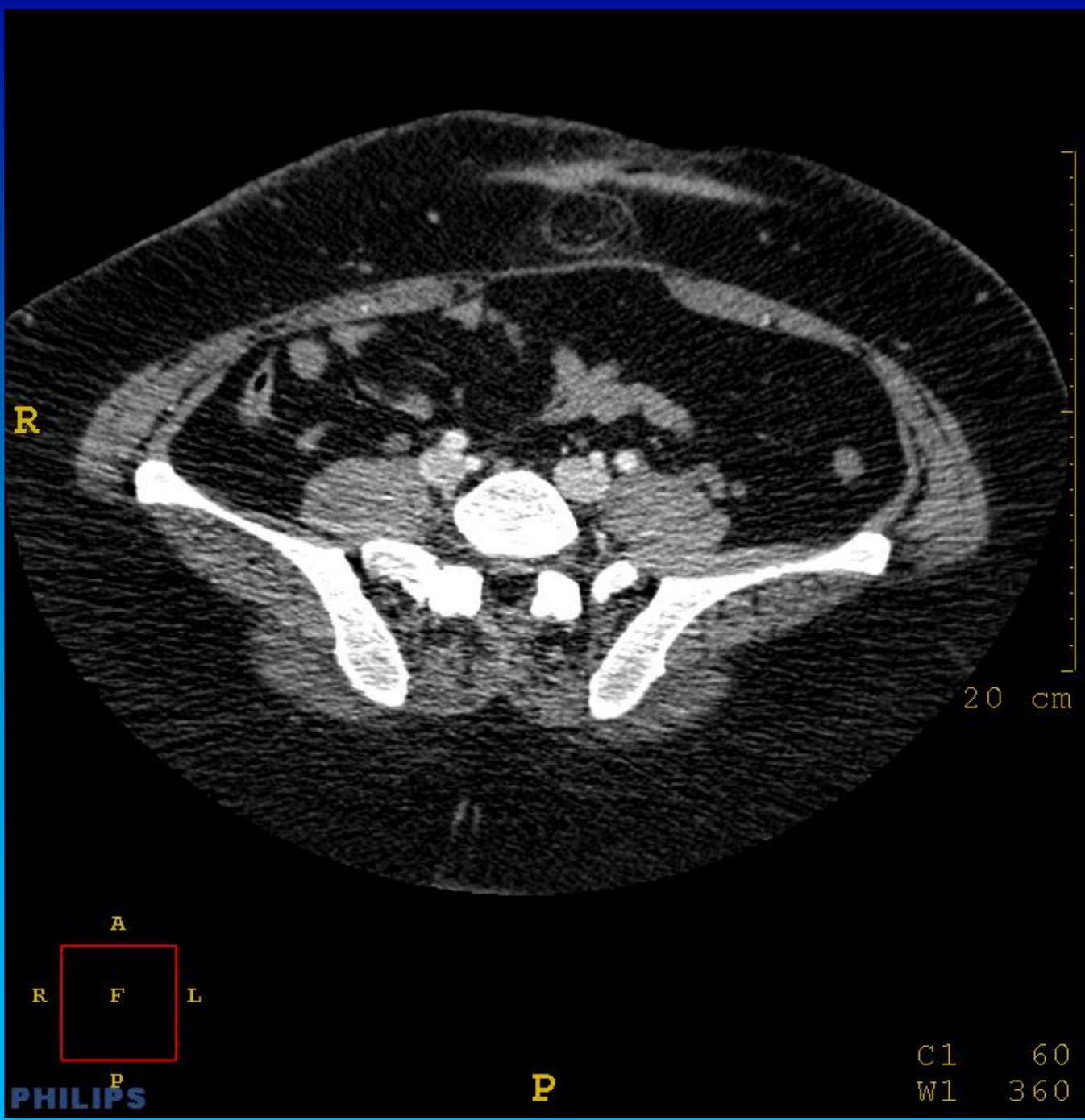
C1 60  
W1 360



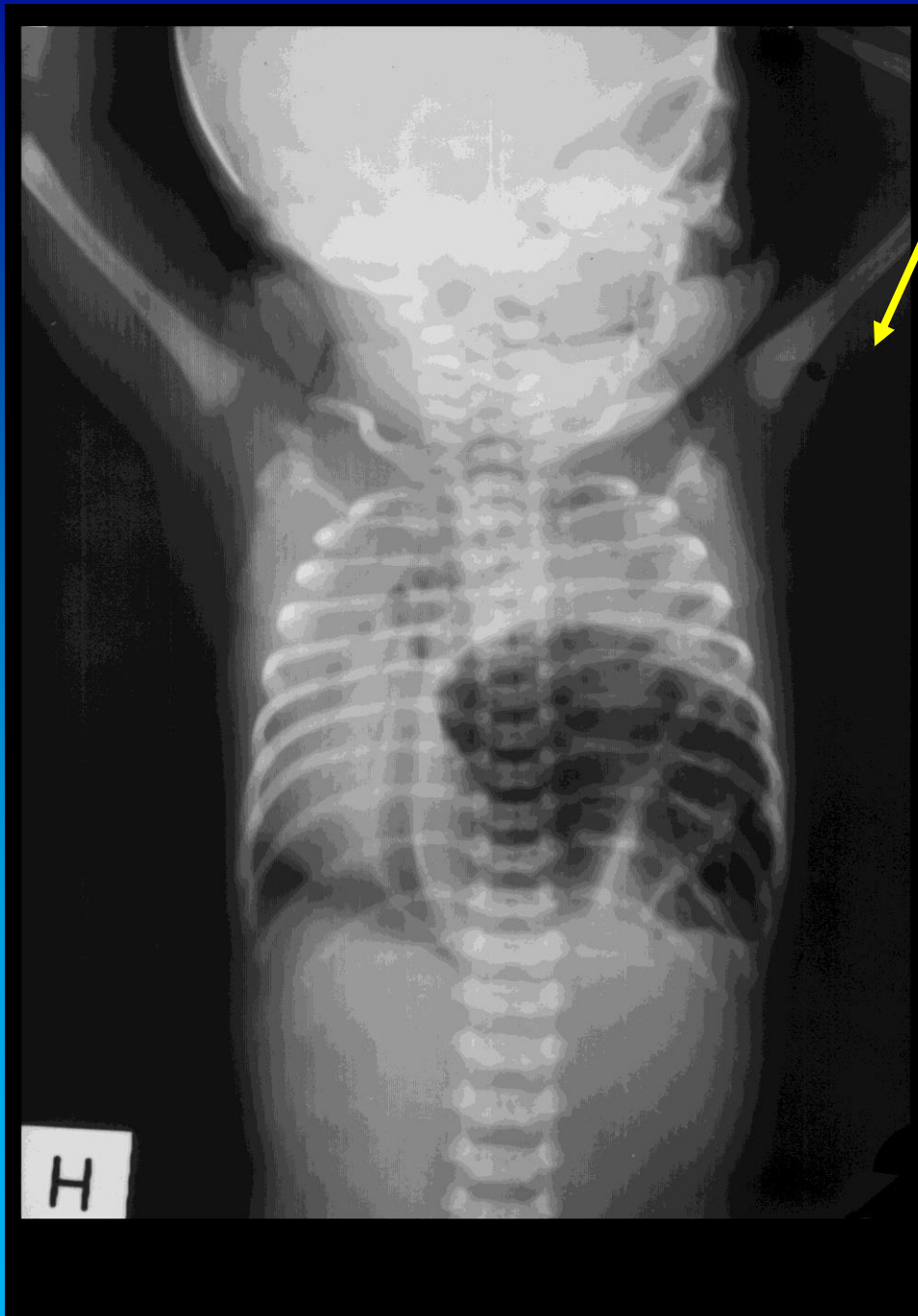



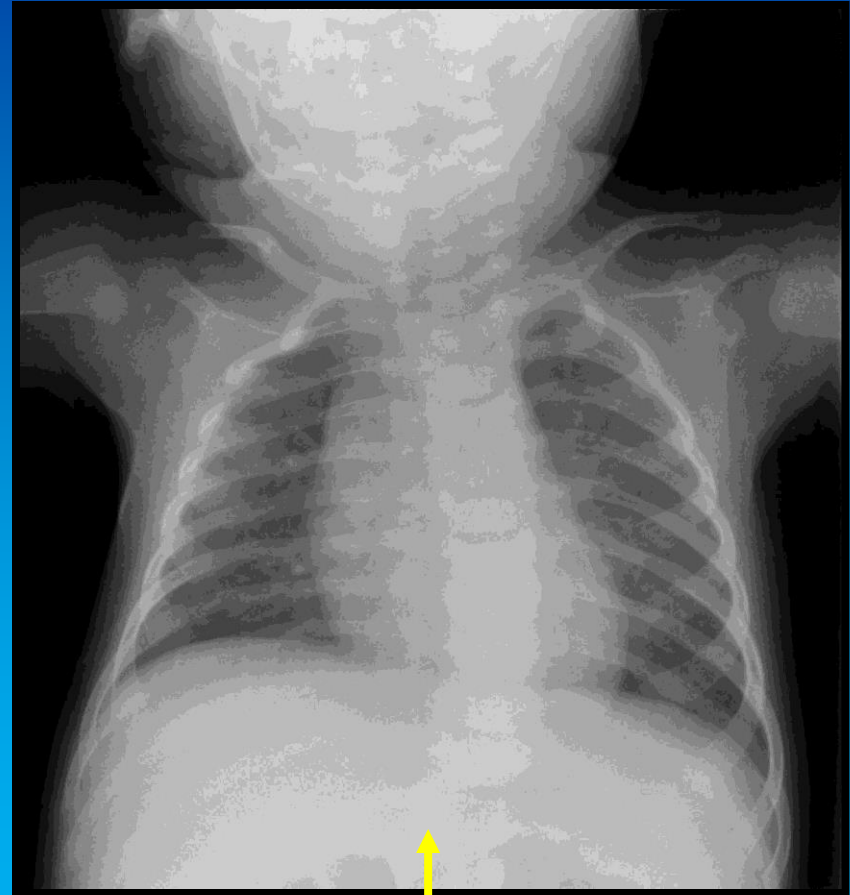




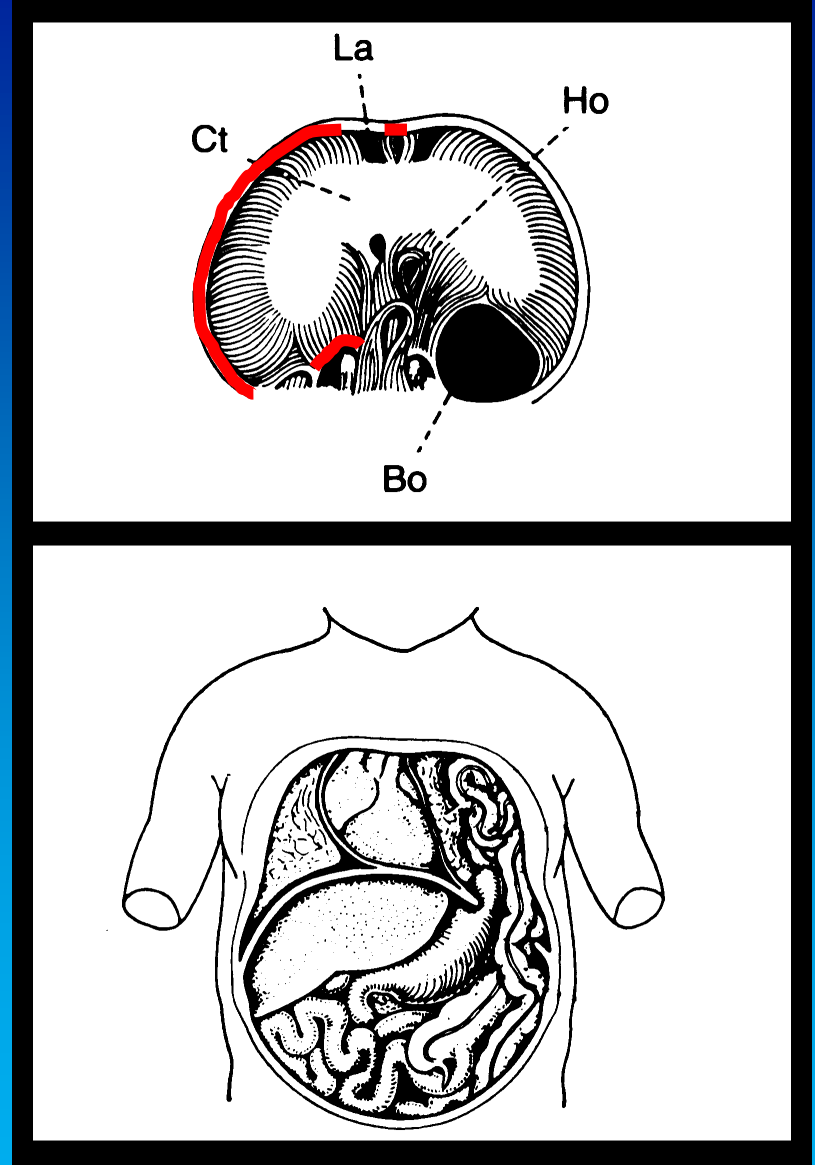

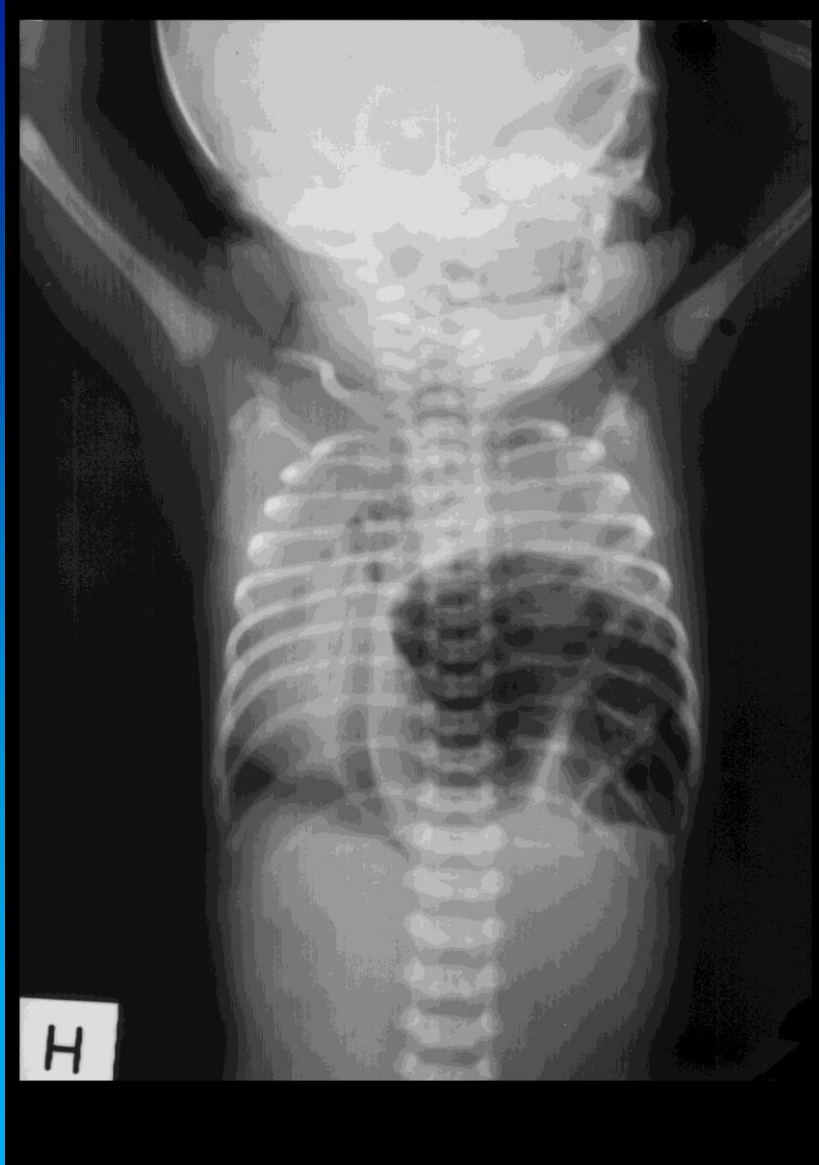


Nyfødt med respiratoriske problemer. Røntgen af thorax kort tid efter fødslen.



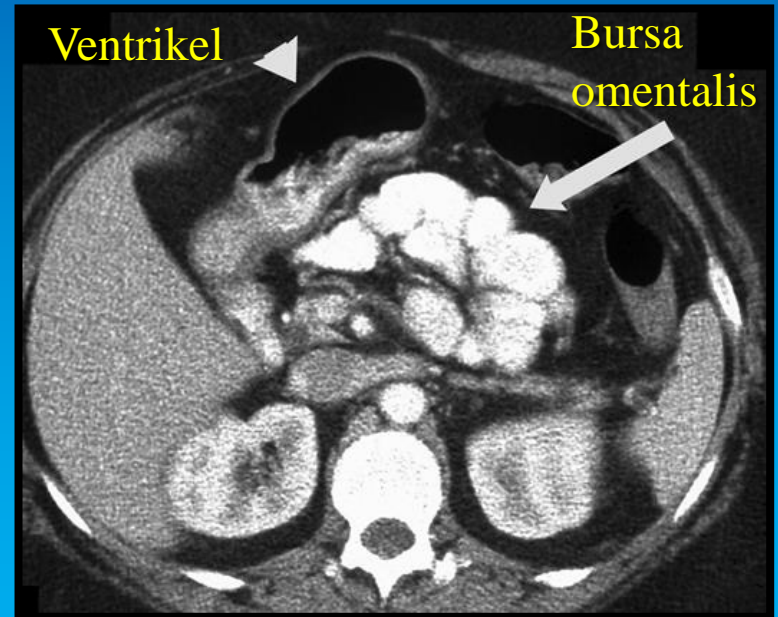
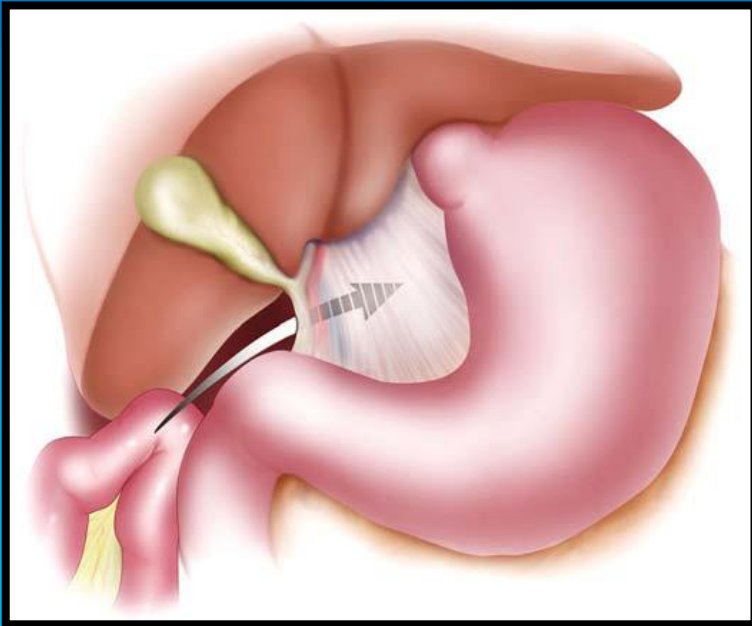
Til sammenligning: Rask, 5 måneder gammel.



Kongenit diaframahernie

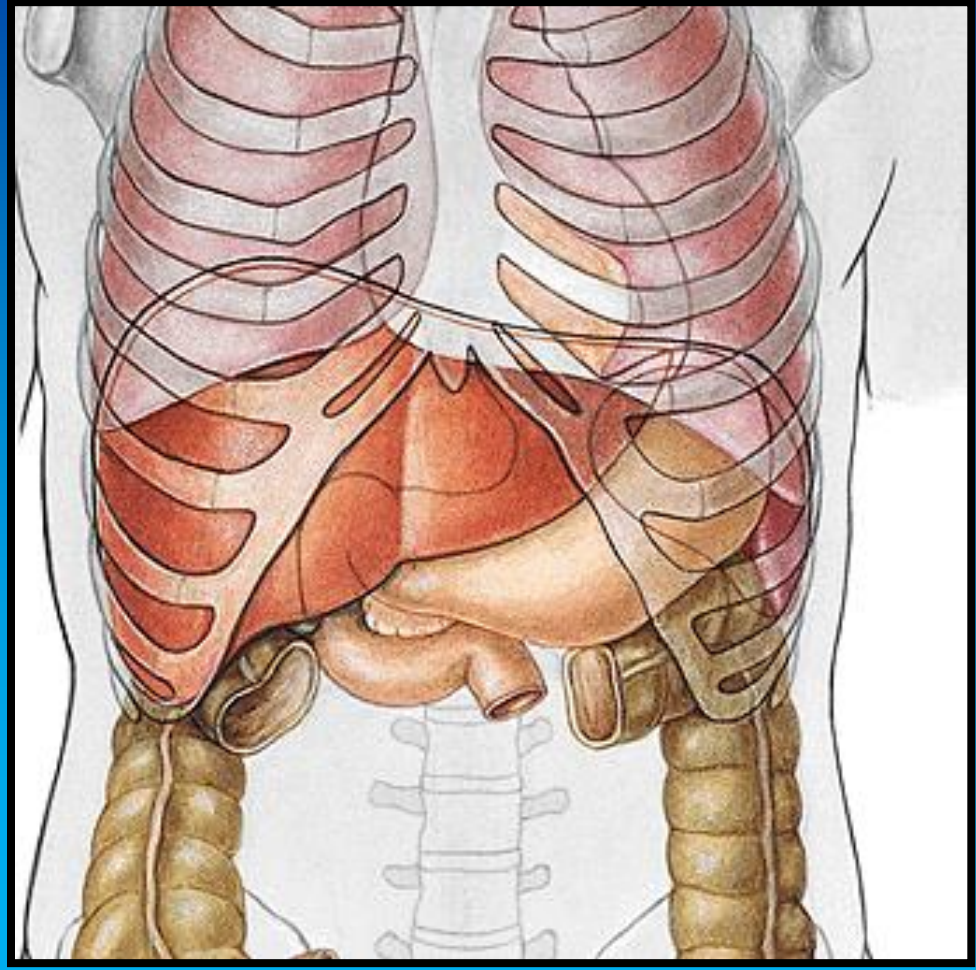
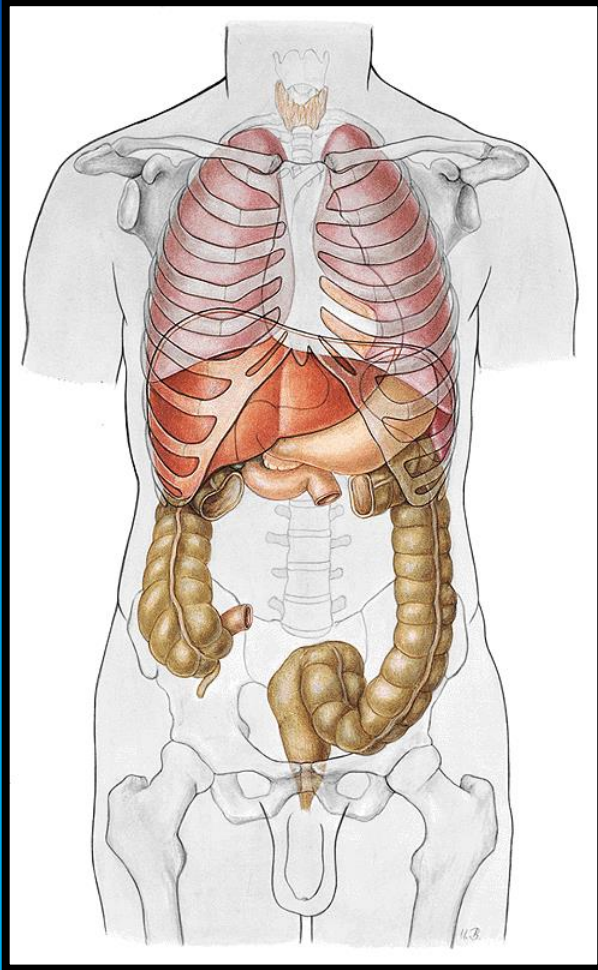
# Interne hernier:

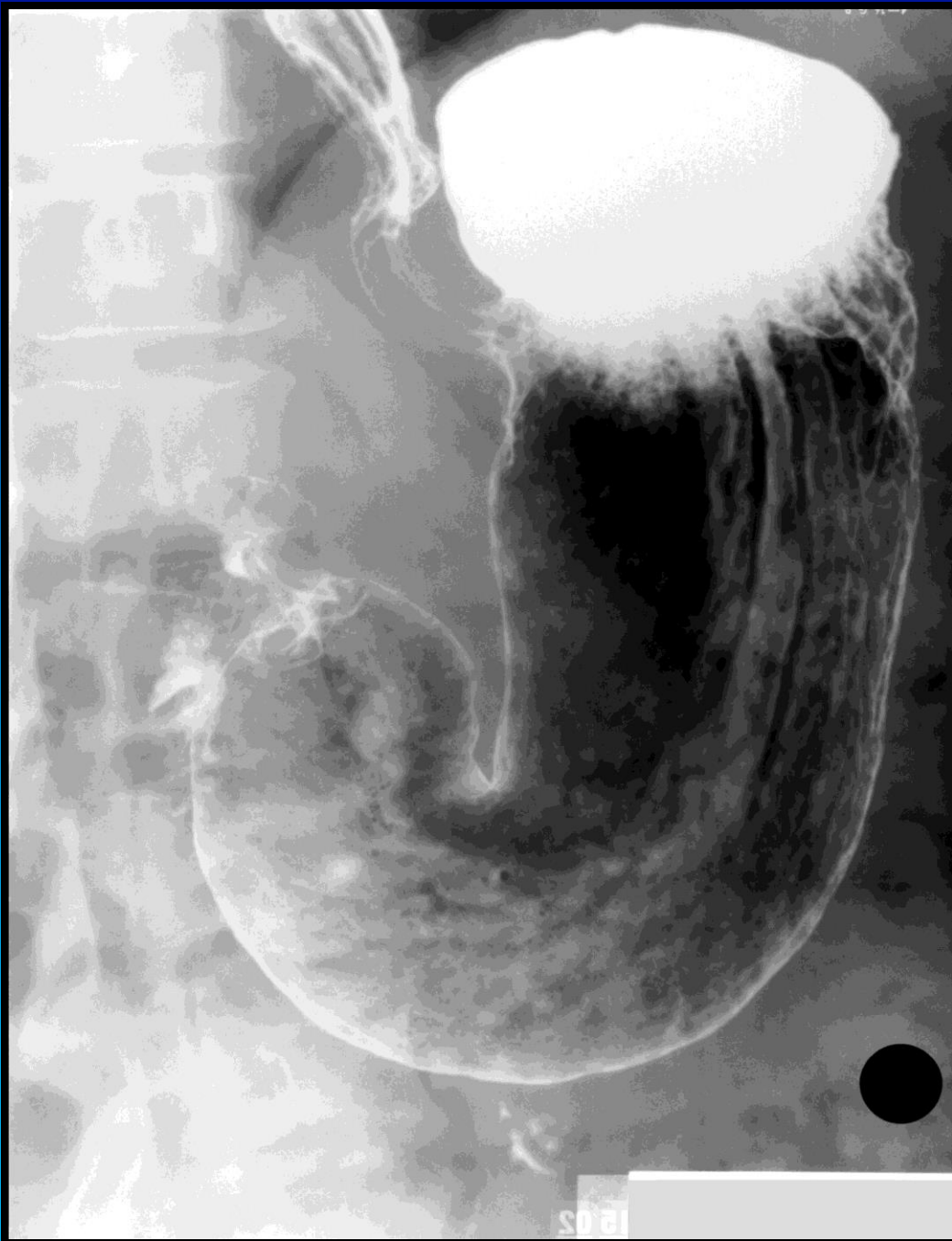## Foramen epiploicum



L. C. Martin et al. AJR:186, March 2006

# Gaster (s. ventriculus)





Esophagus.

Ventriculus/gaster:

Cardia med incisura  
cardiaca.

Fundus gastricus  
(ventriculi).

Corpus ventriculi med  
plicae gastricae.

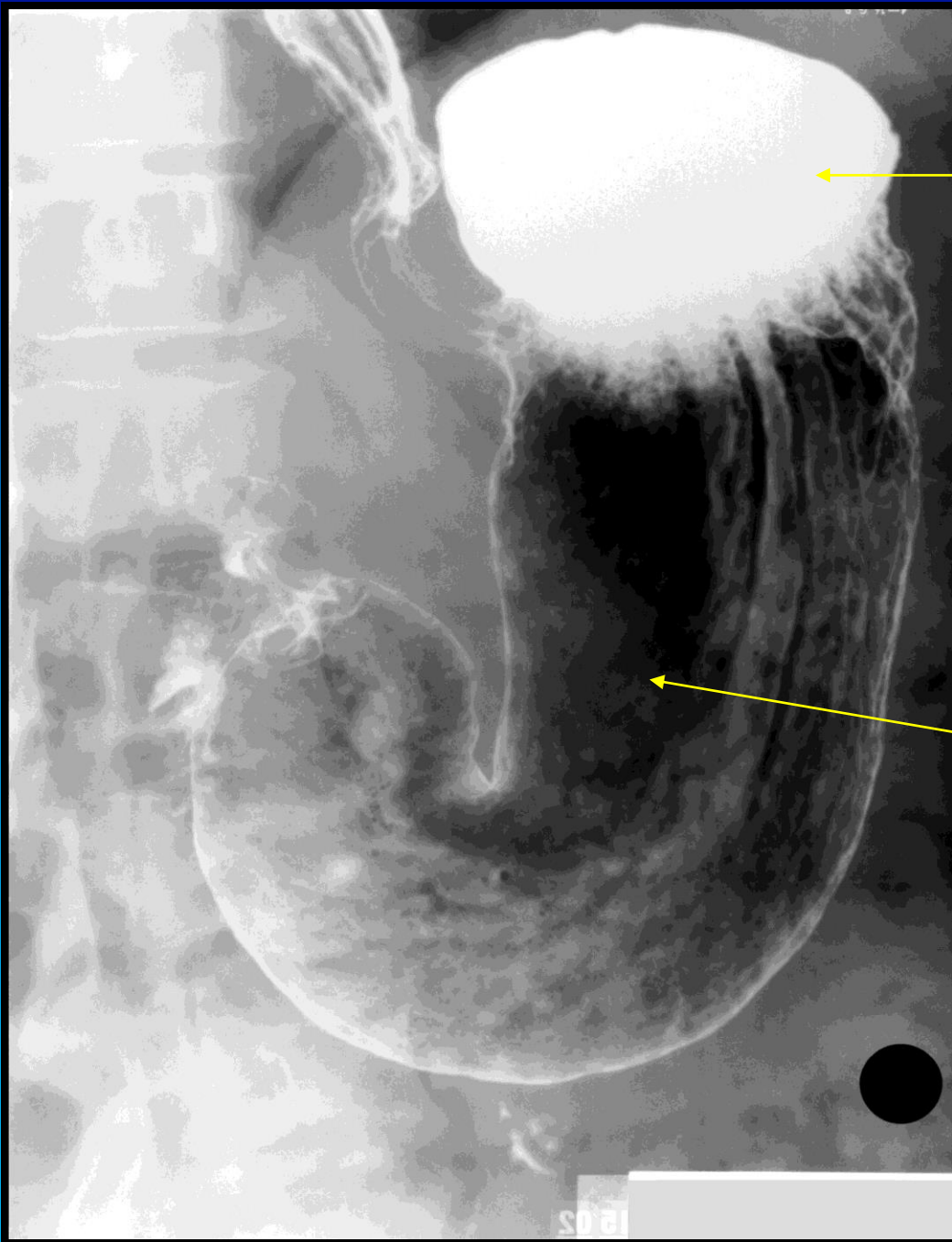Curvatura ventriculi major  
et minor.

Incisura angularis.


Pars pylorica

Antrum pyloricum

Canalis pyloricus



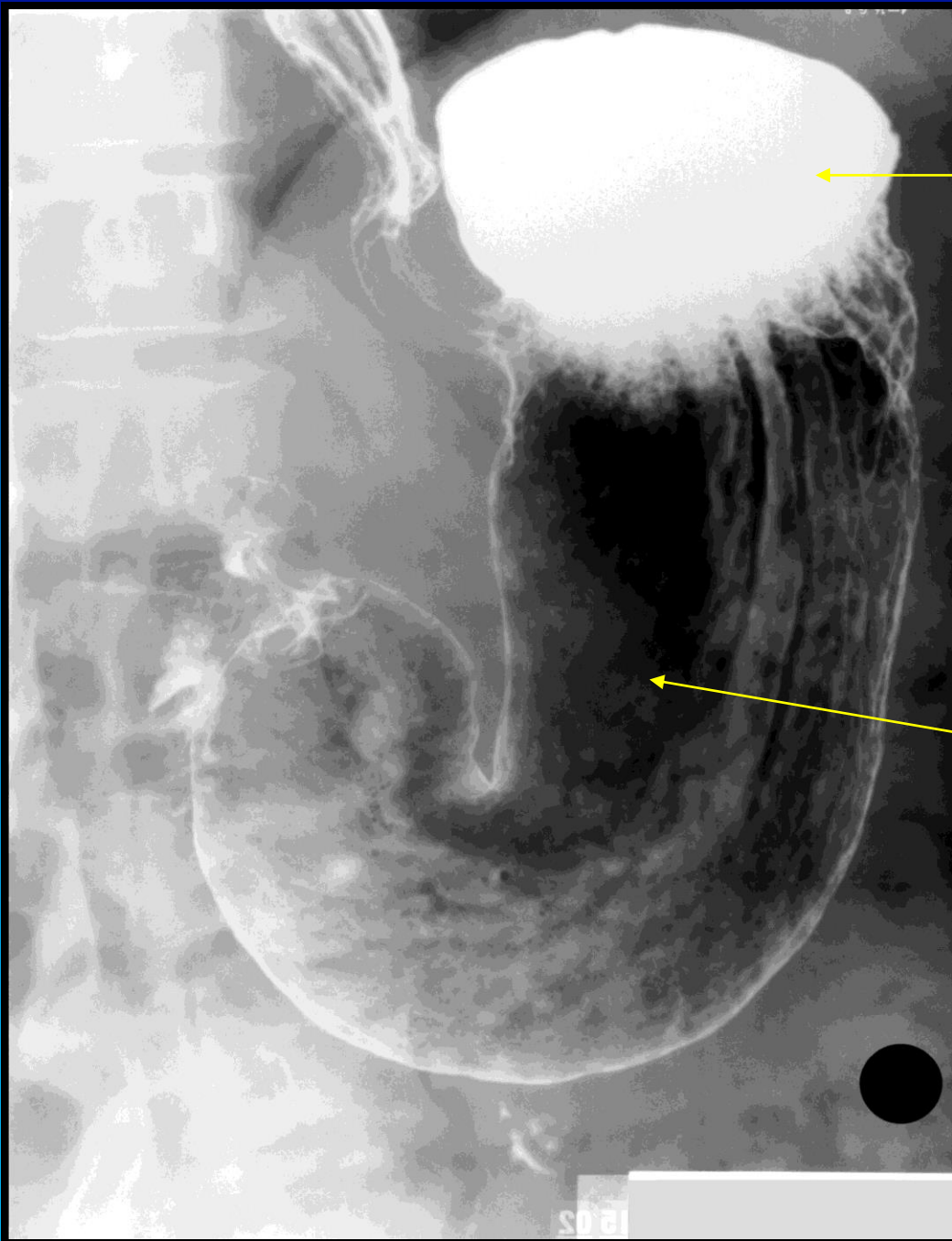
Røntgenkontrast (Bariumsulfat)




Luft/gas (Kuldioxid fra brusetabletter)



Hvordan vender patienten?



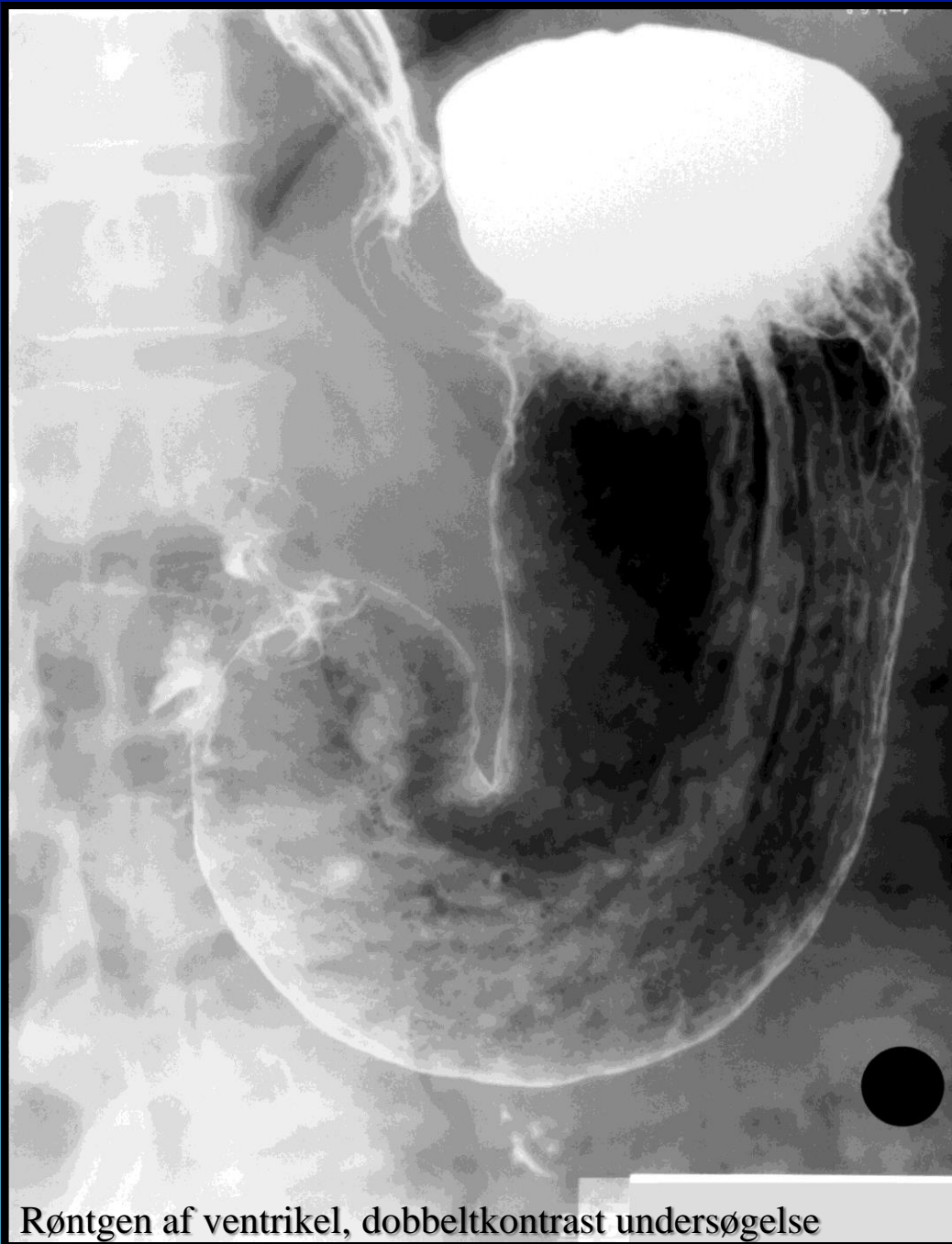Røntgenkontrast (Bariumsulfat)



Luft/gas (Kuldioxid fra brusetabletter)



Hvordan vender patienten:  
Bariumsulfat er tungere end luft, så  
det lejres deklivt, dvs. personen har  
hovedet nedad.



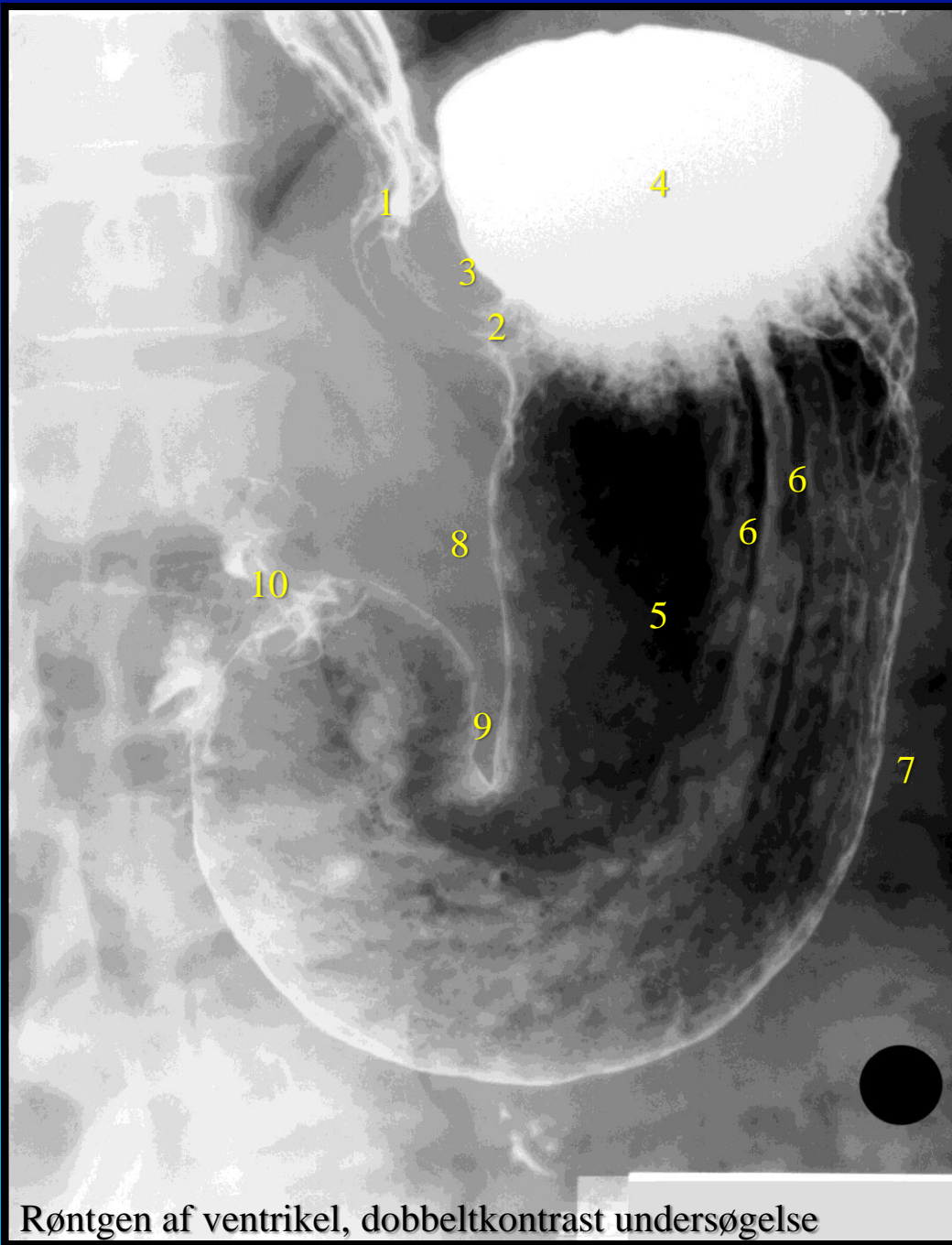Røntgen af ventrikel, dobbeltkontrast undersøgelse

Dobbelt kontrastundersøgelse af ventriklen, med såvel bariumsulfat kontrast (hvidt) og luft (i dette tilfælde fra brusetabletter).

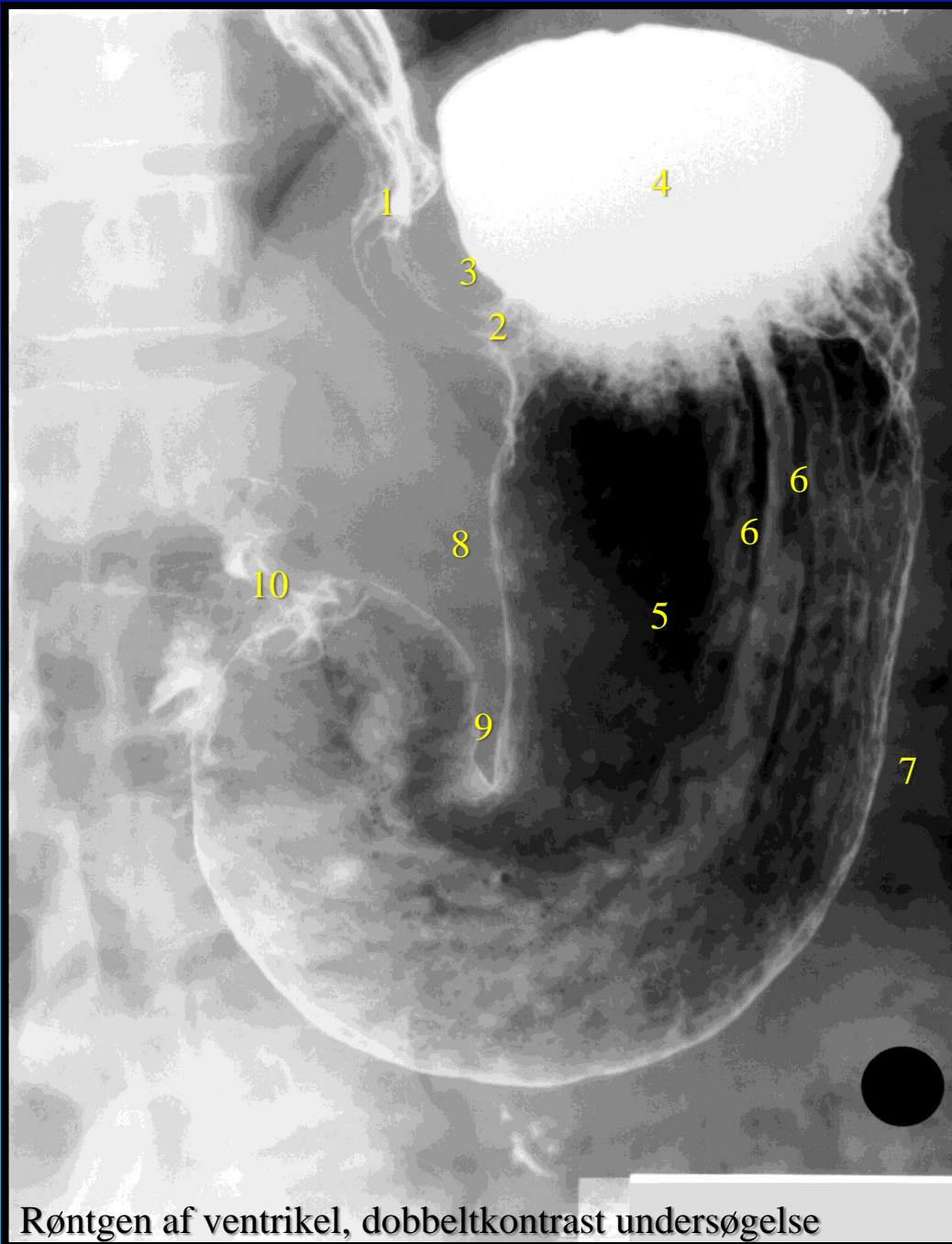Med denne teknik fås et godt indblik til slimhinden mhp. diagnostik af ventrikel ulcer (mavesår) og kræft i ventriklen.

Metoden er blevet erstattet af gastroskopi (kikkertundersøgelse af ventrikler), billedet er dog medtaget fordi det giver et godt overblik over ventriklens anatomi.





Røntgen af ventrikel, dobbeltkontrast undersøgelse



Esophagus (1).

Ventriculus/gaster:

Cardia (2) med incisura cardiaca/cardialis (3).

Fundus gastricus (4) (ventriculi).

Corpus ventriculi (5) med plicae gastricae (6).

Curvatura ventriculi major (7) et minor (8).

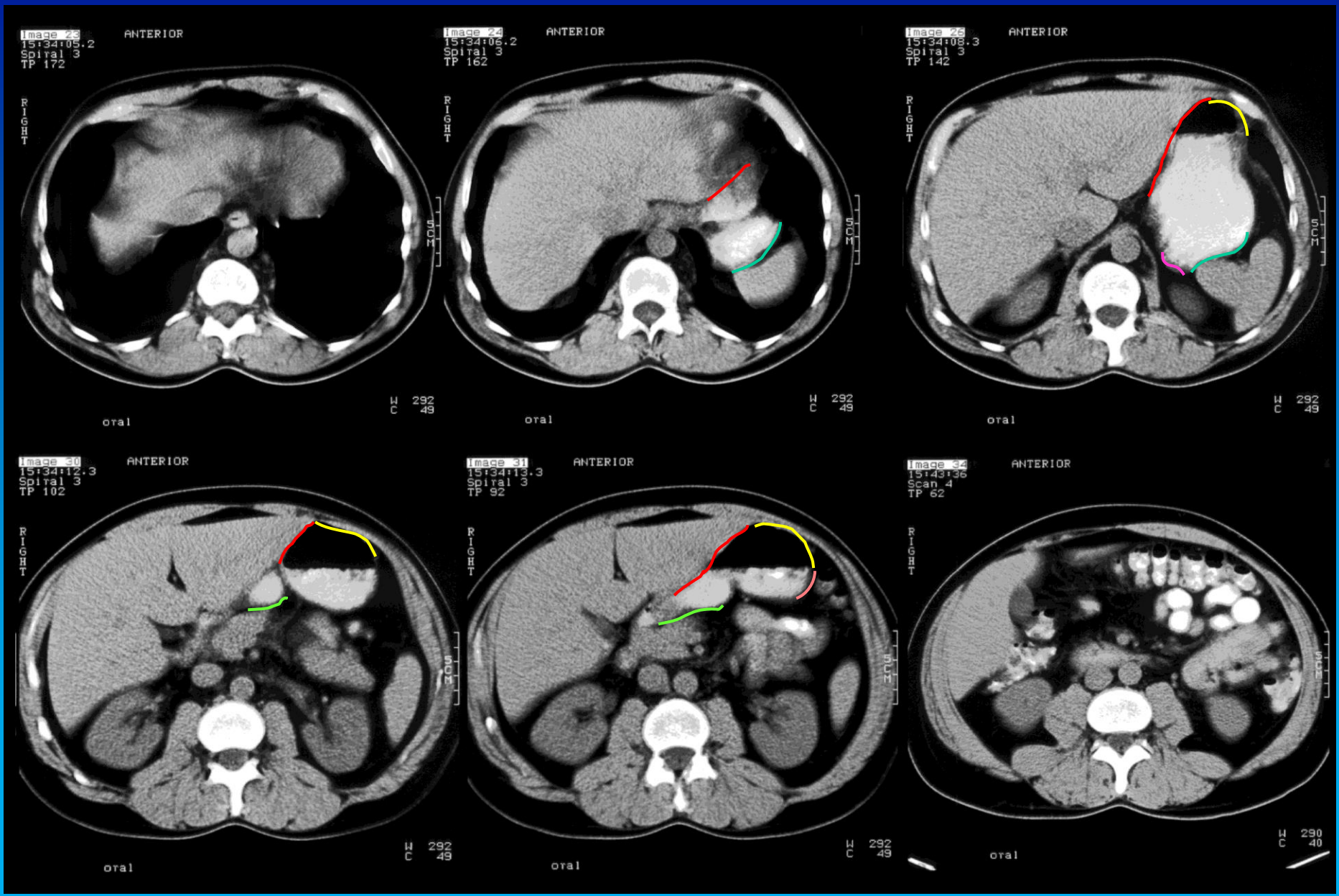
Incisura angularis (9).

Pars pylorica

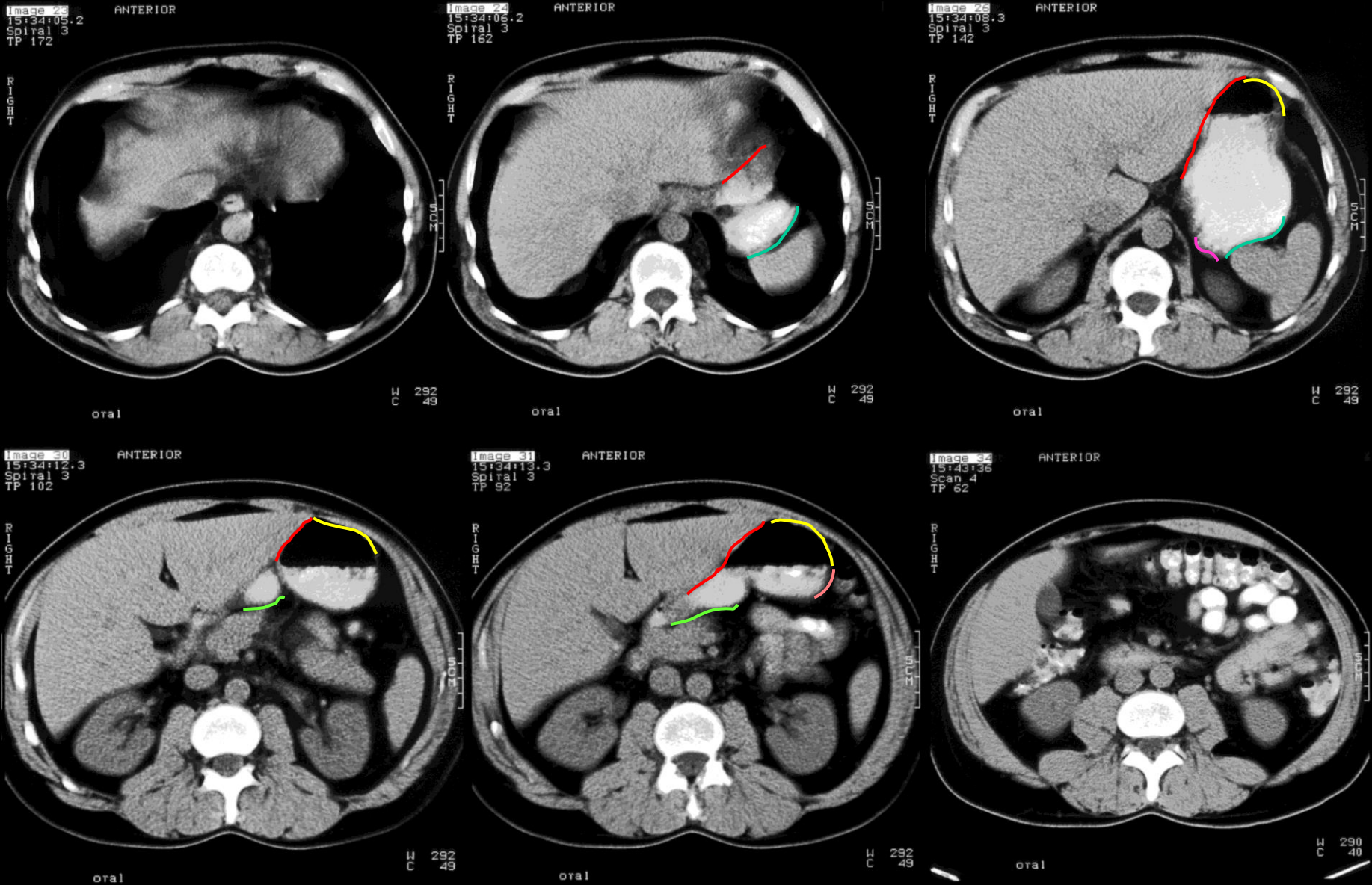
Antrum pyloricum

Canalis pyloricus (10)

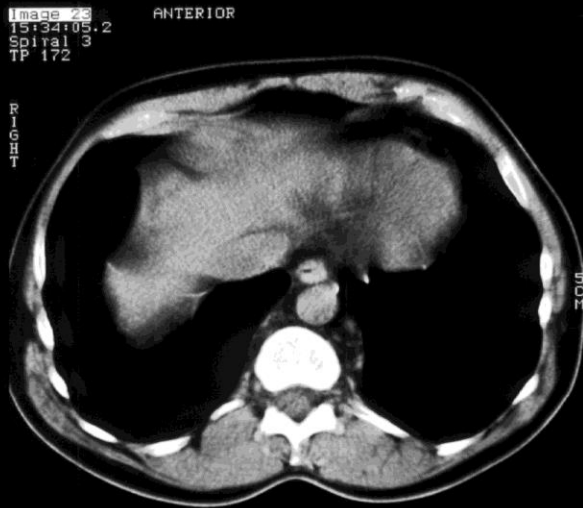
Røntgen af ventrikel, dobbeltkontrast undersøgelse



CT skanning af øvre abdomen med peroral kontrast

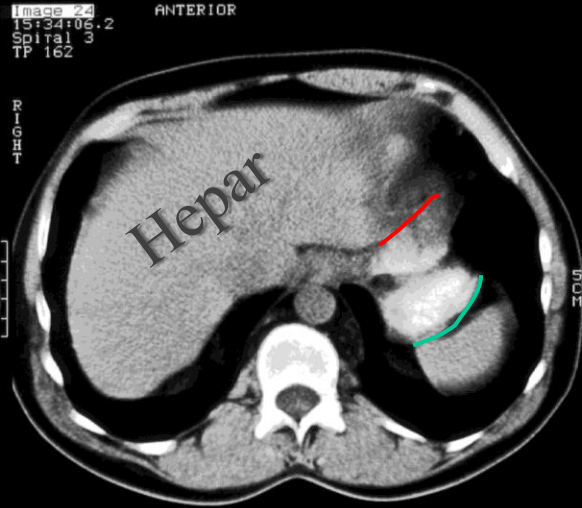


På næste billede kan ses de markerede relationer.



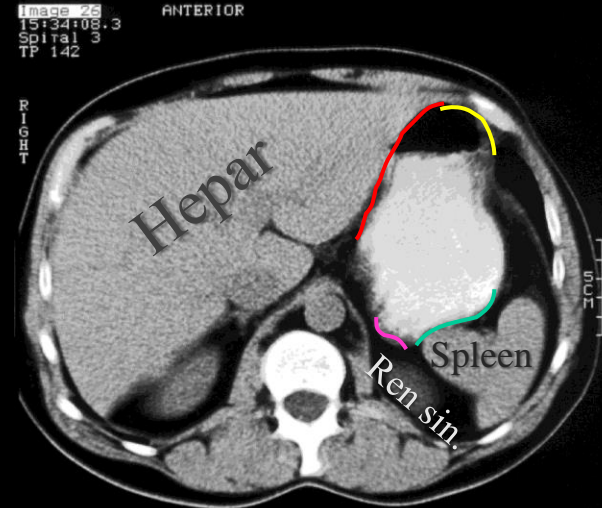
H C 292  
49

oral



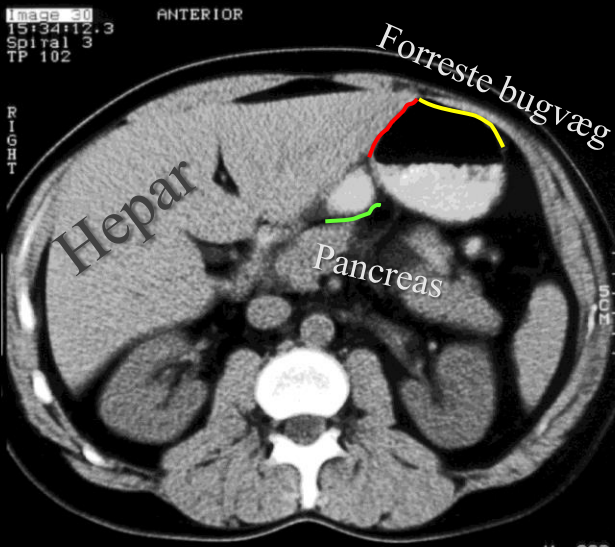
H C 292  
49

oral



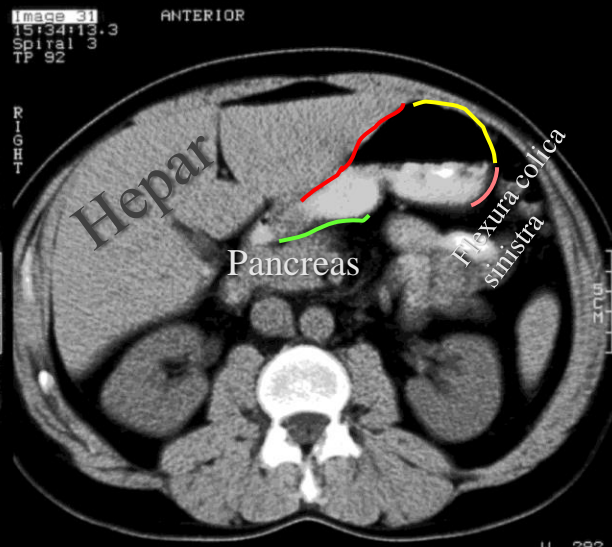
H C 292  
49

oral



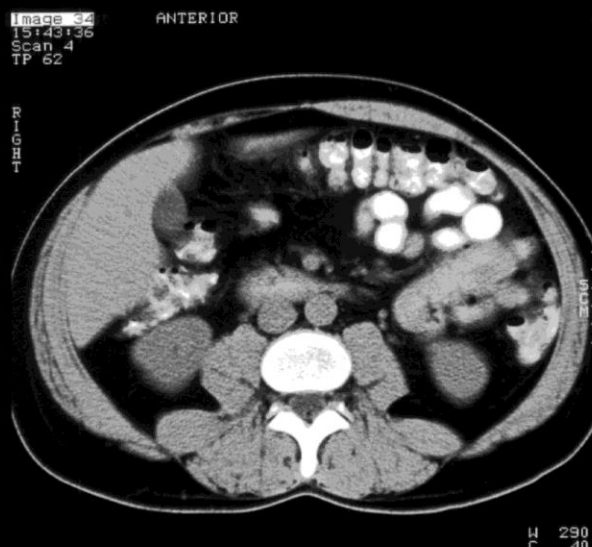H C 292  
49

oral



H C 292  
49

oral

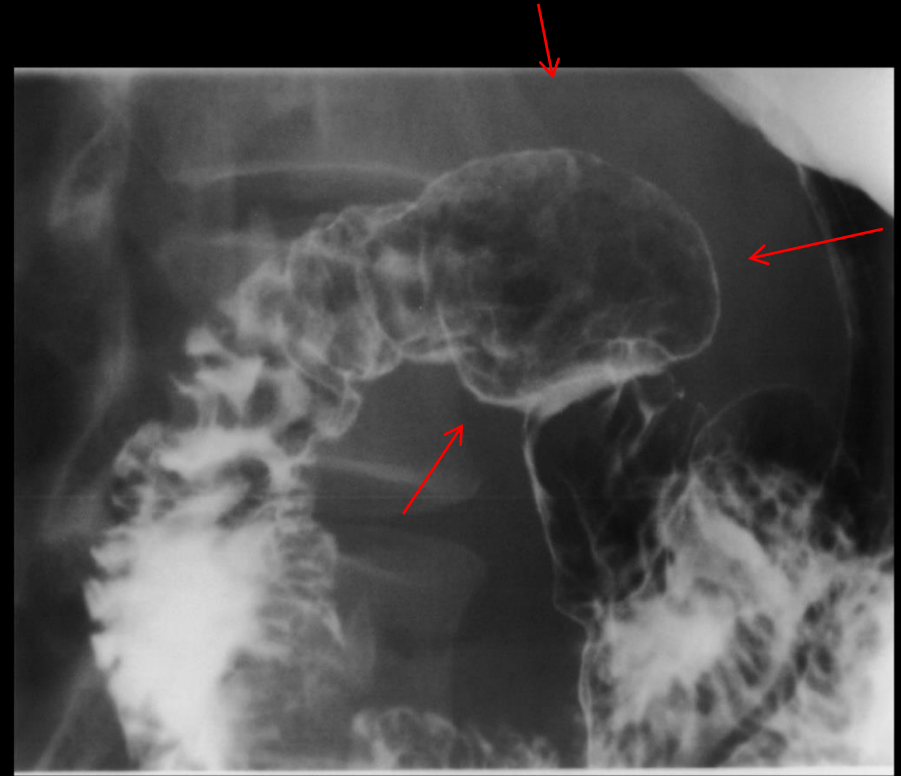
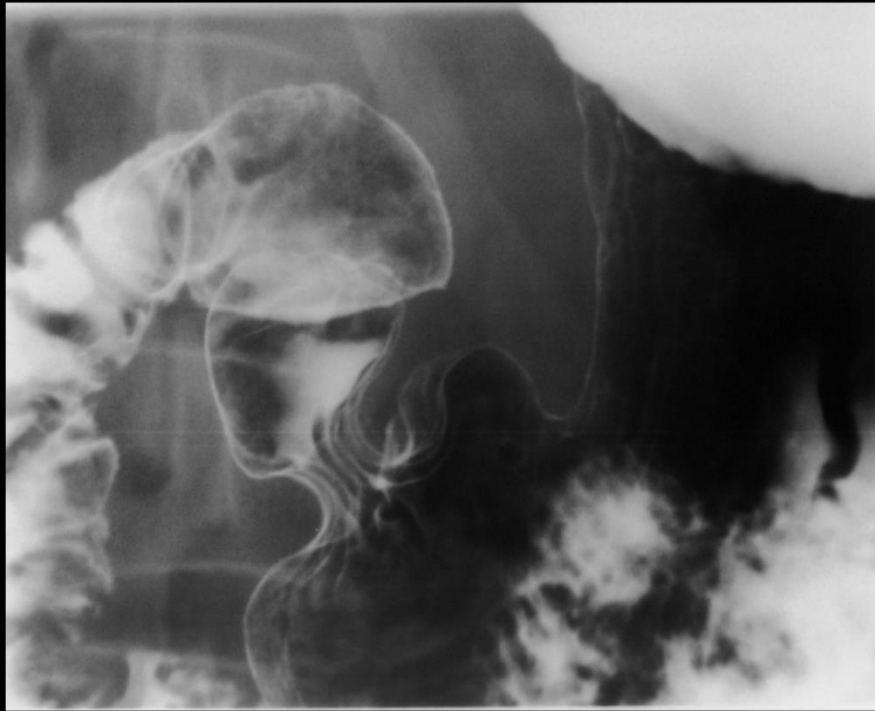
H C 290  
40

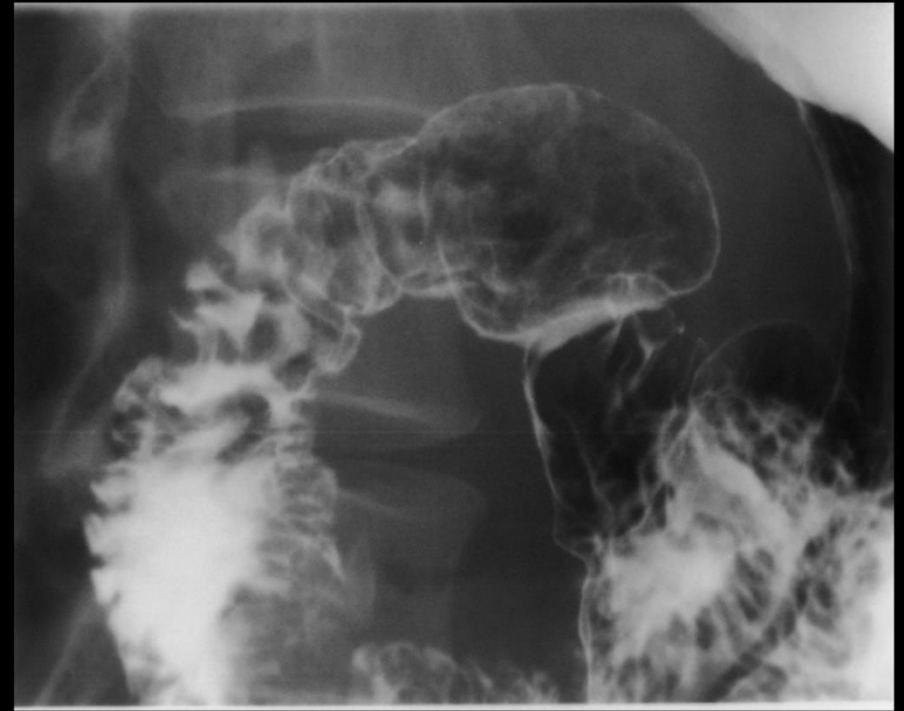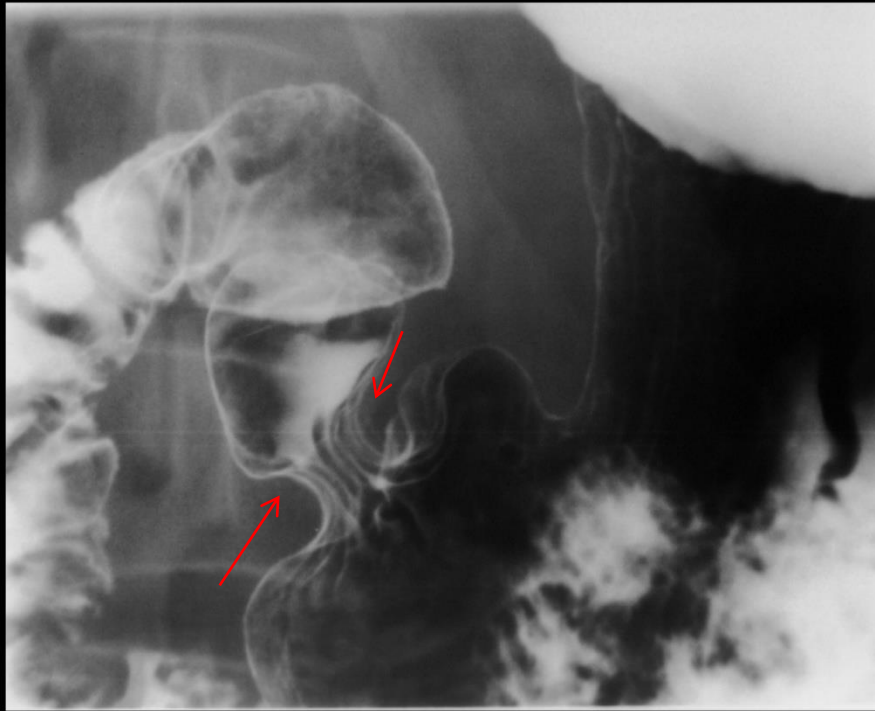oral

# Intestinum tenue

Pars superior med bulbus (ampulla) duodeni  
mangler plicae circulares

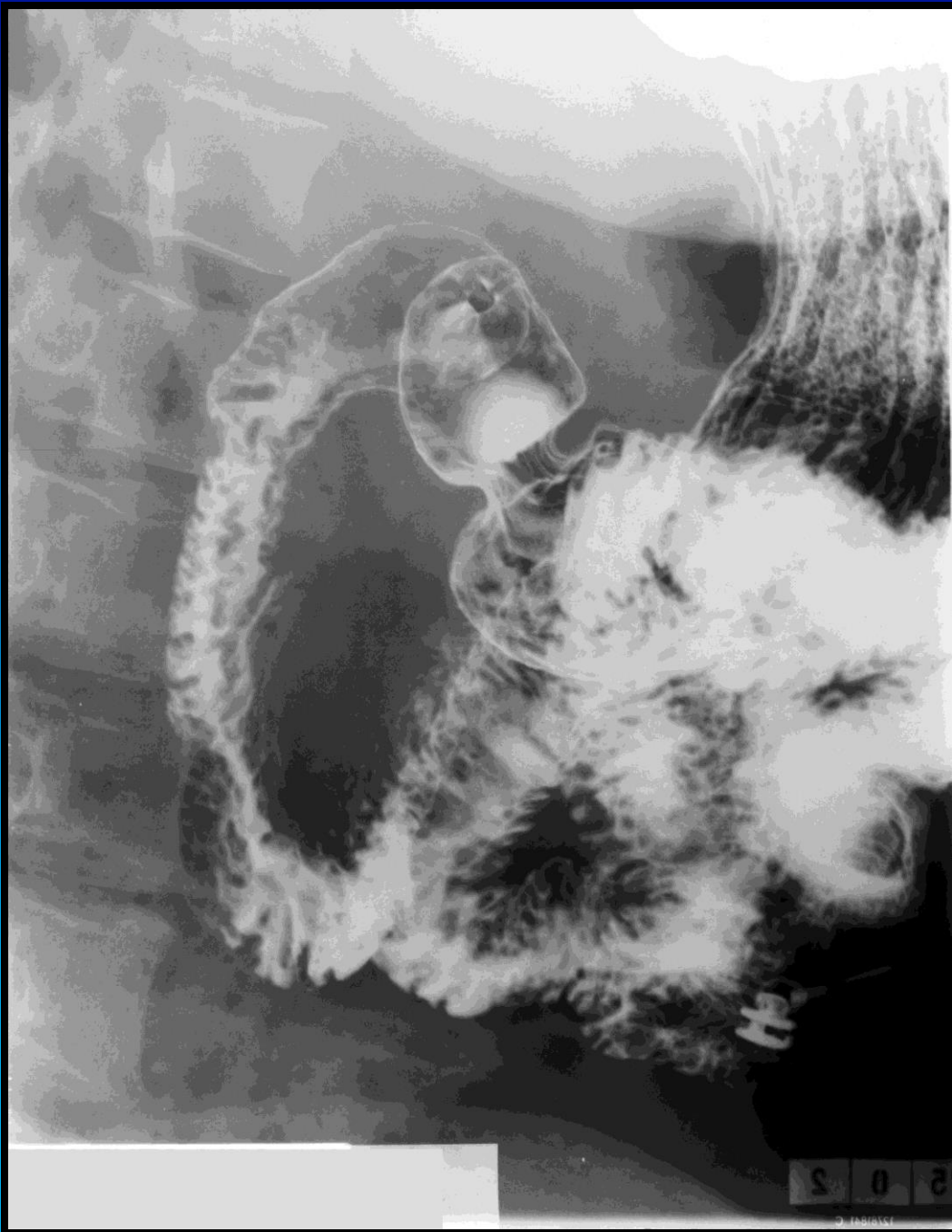

Røntgen dobbeltkontrast undersøgelse



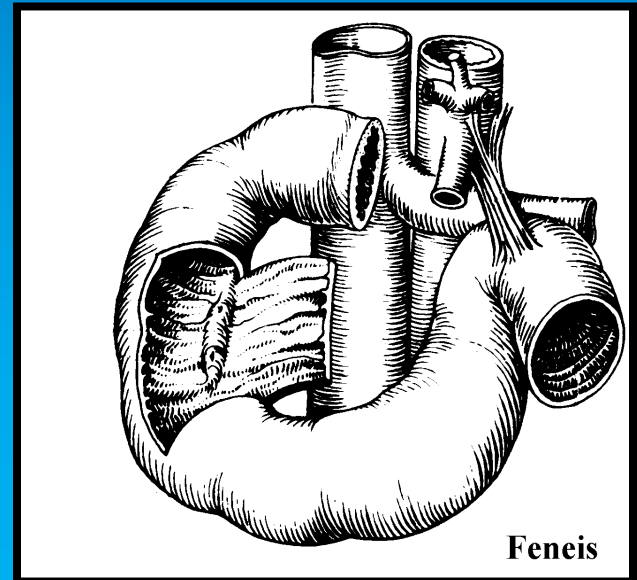
Peristaltisk kontraktion i pylorus regionen

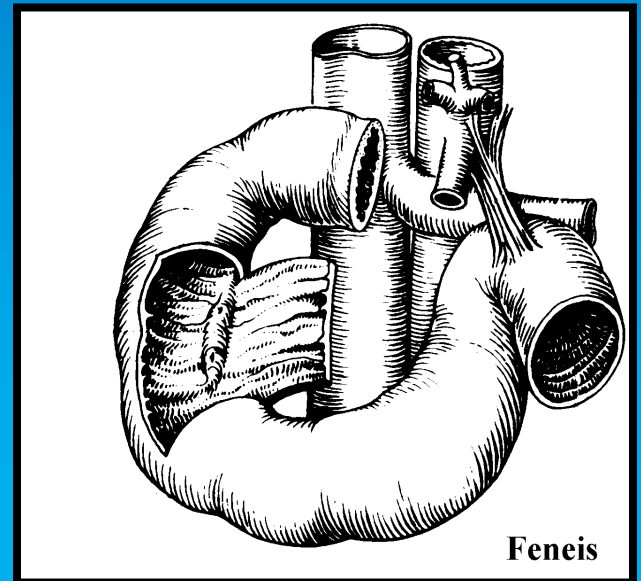
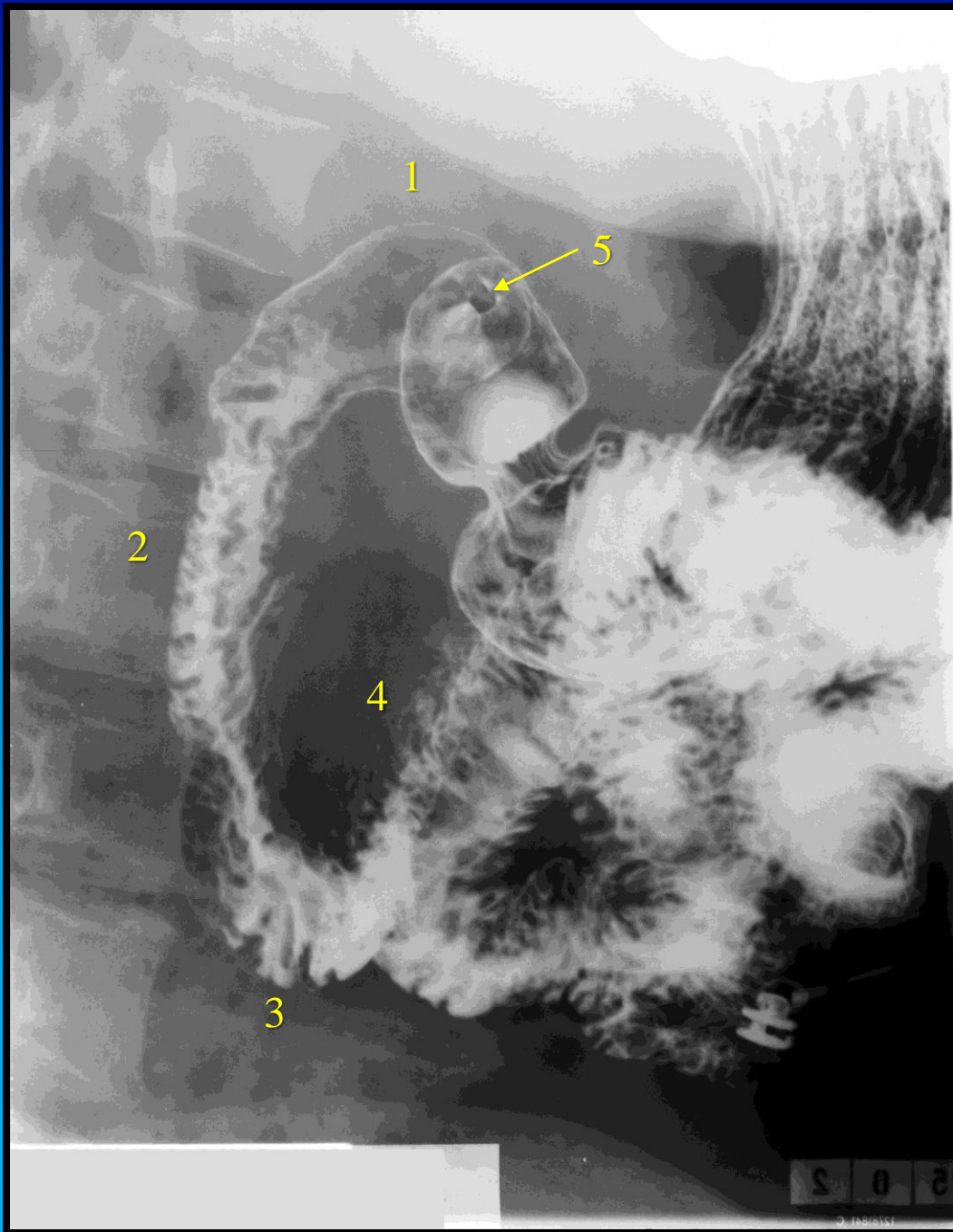


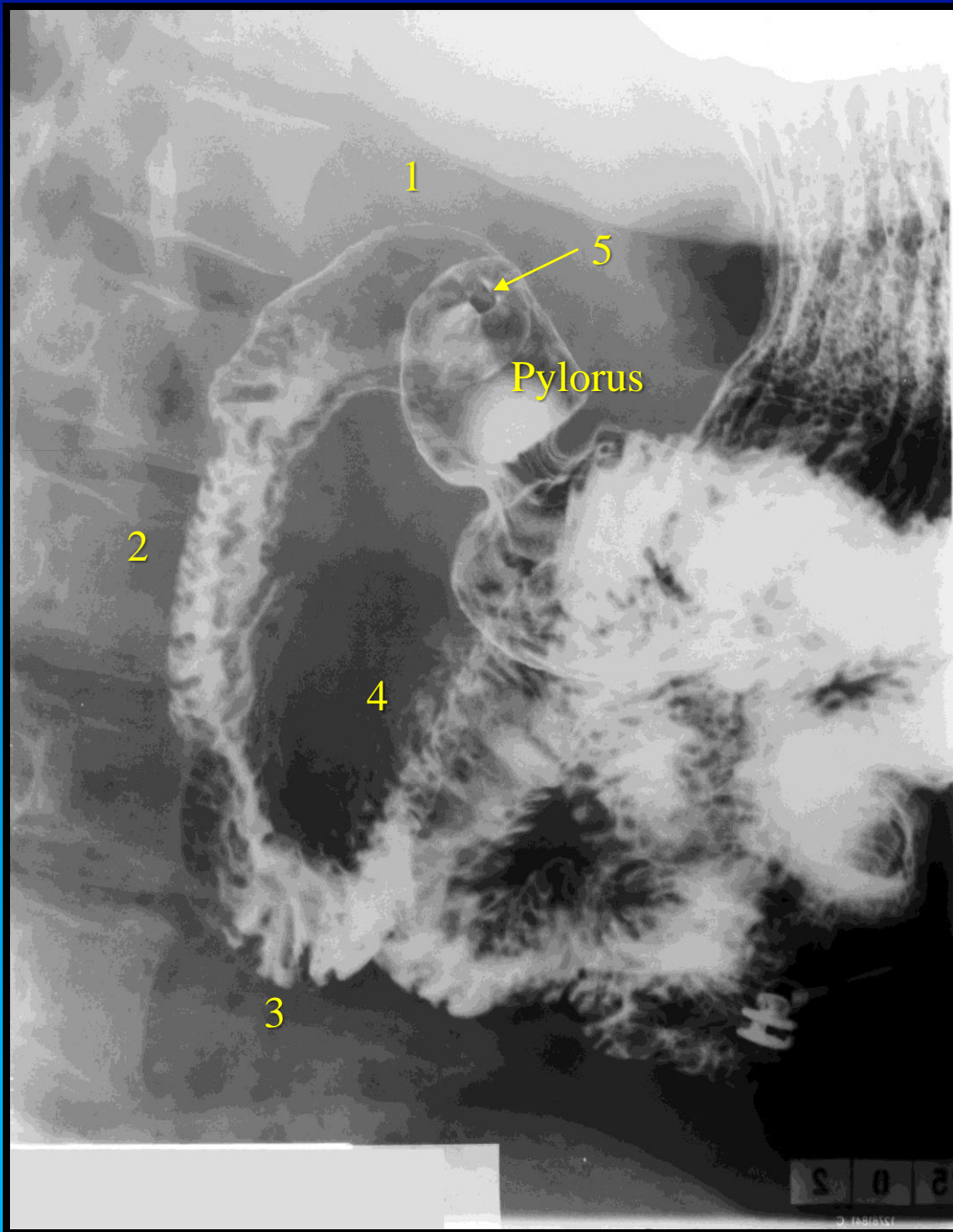


## Duodenum:

- 1) Pars superior med bulbus (ampulla) duodeni.
- 2) Pars descendens.
- 3) Pars horizontalis (inferior).
- 4) Pars ascendens.
- 5) Canalis pyloricum

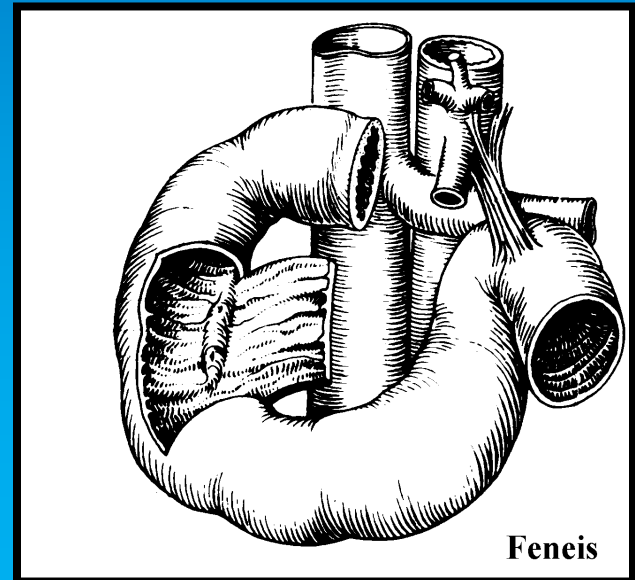




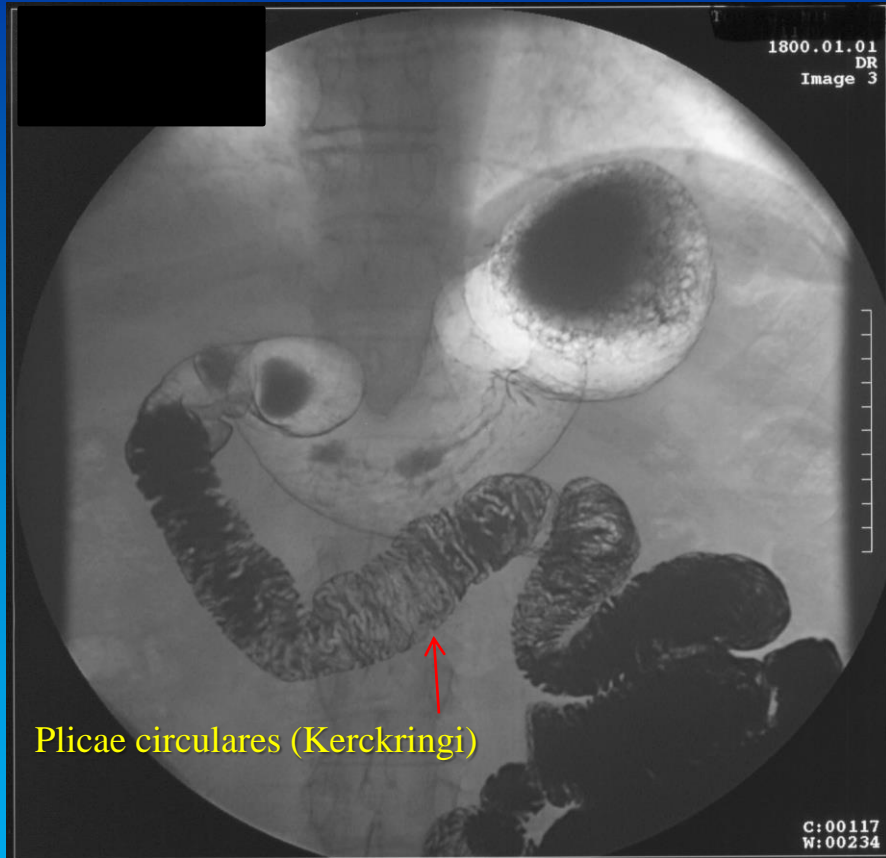


## Duodenum:

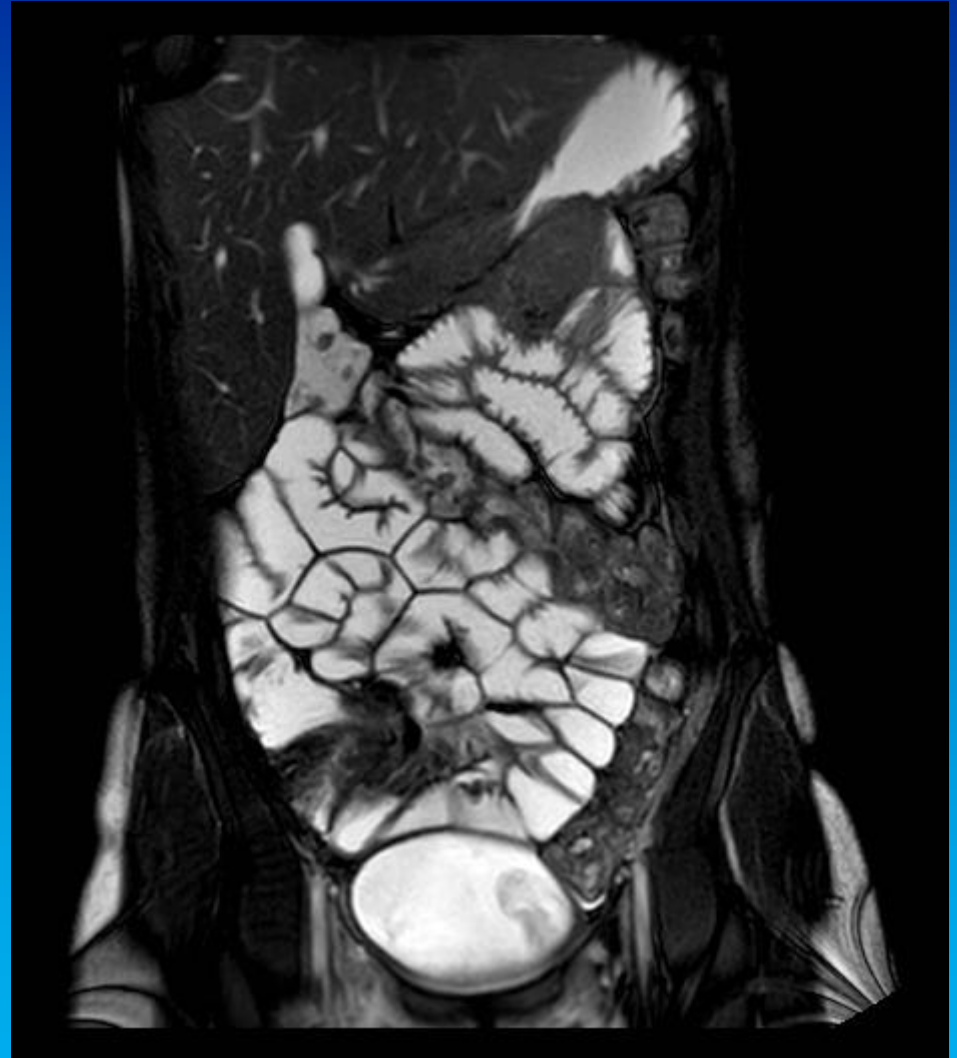
- 1) Pars superior med bulbus (ampulla) duodeni.
- 2) Pars descendens.
- 3) Pars horizontalis (inferior).
- 4) Pars ascendens.
- 5) Canalis pyloricum



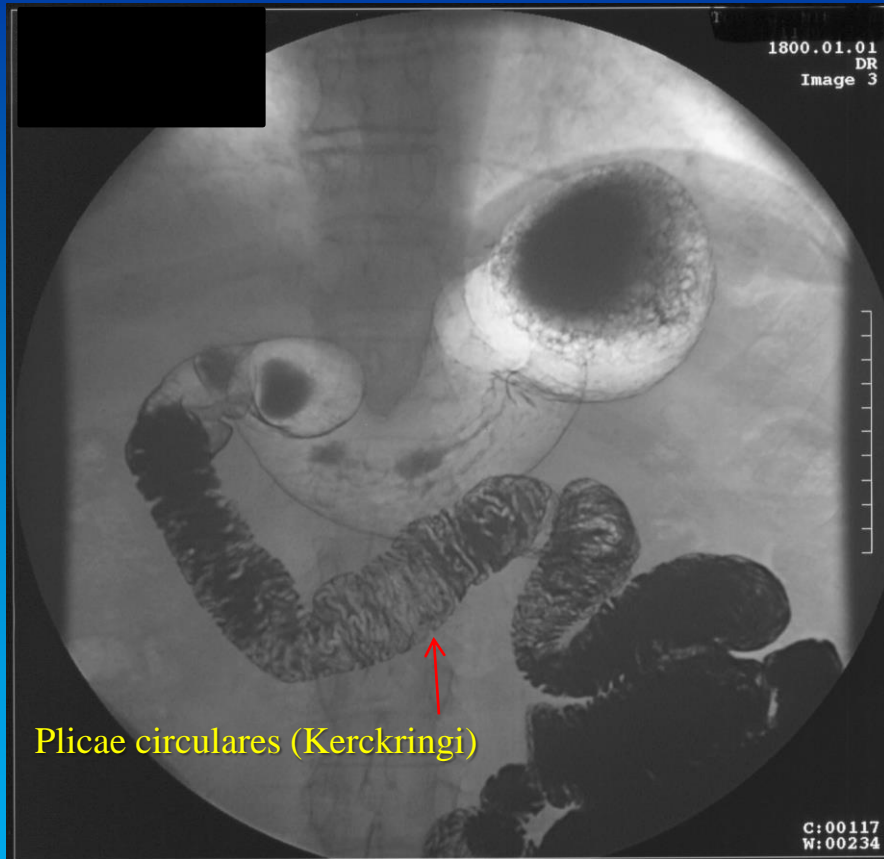
# TTP: Tyndtarmspassage



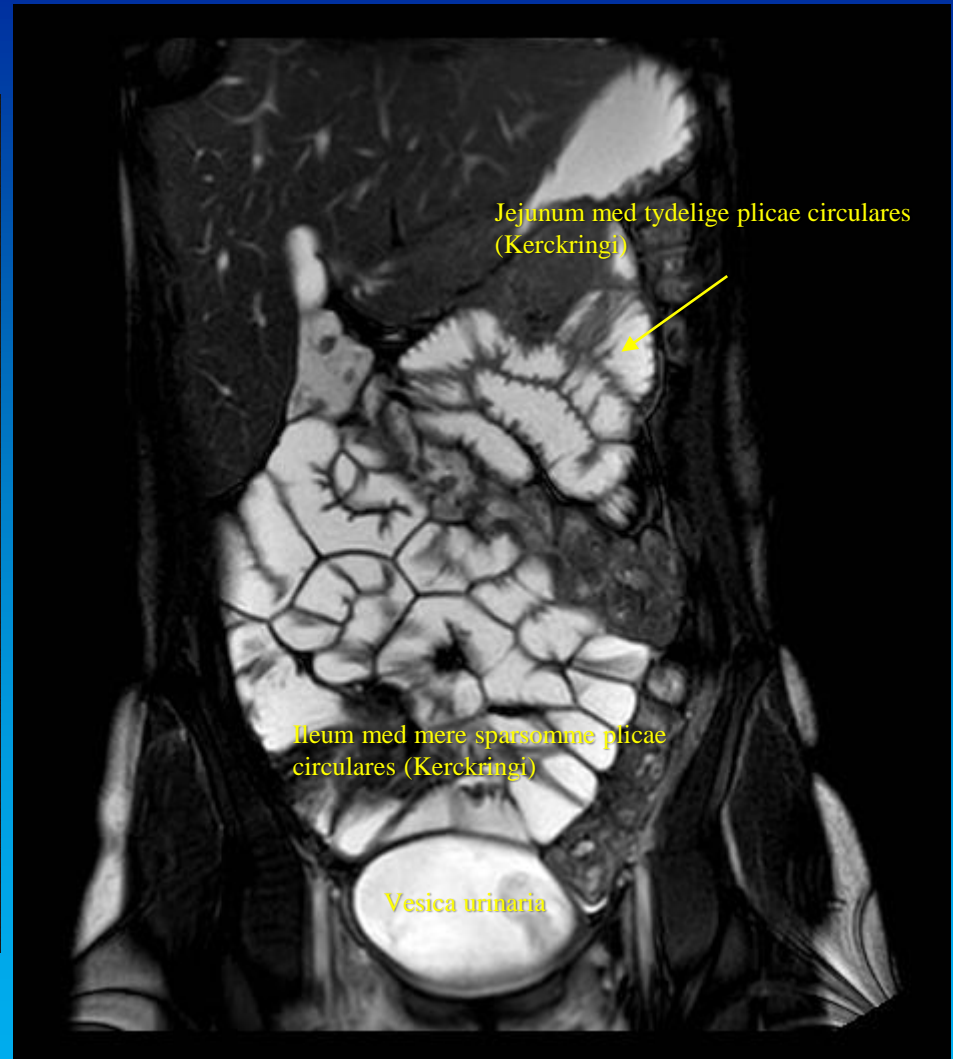# MR af tyndtarm



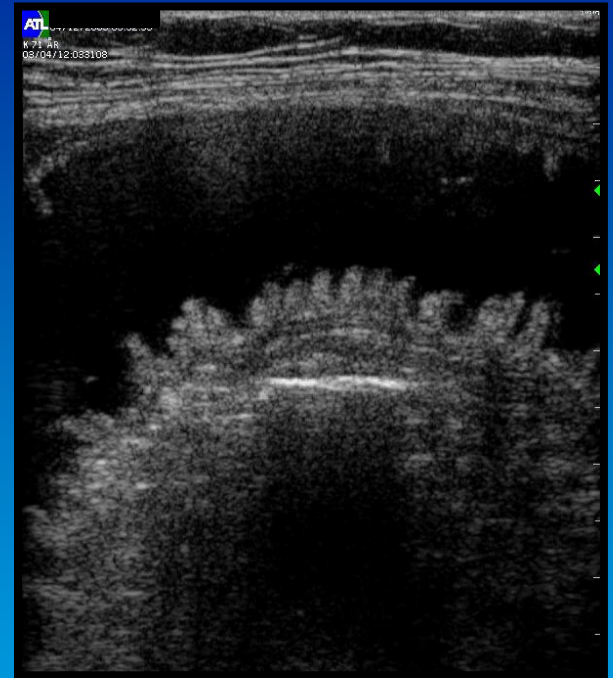
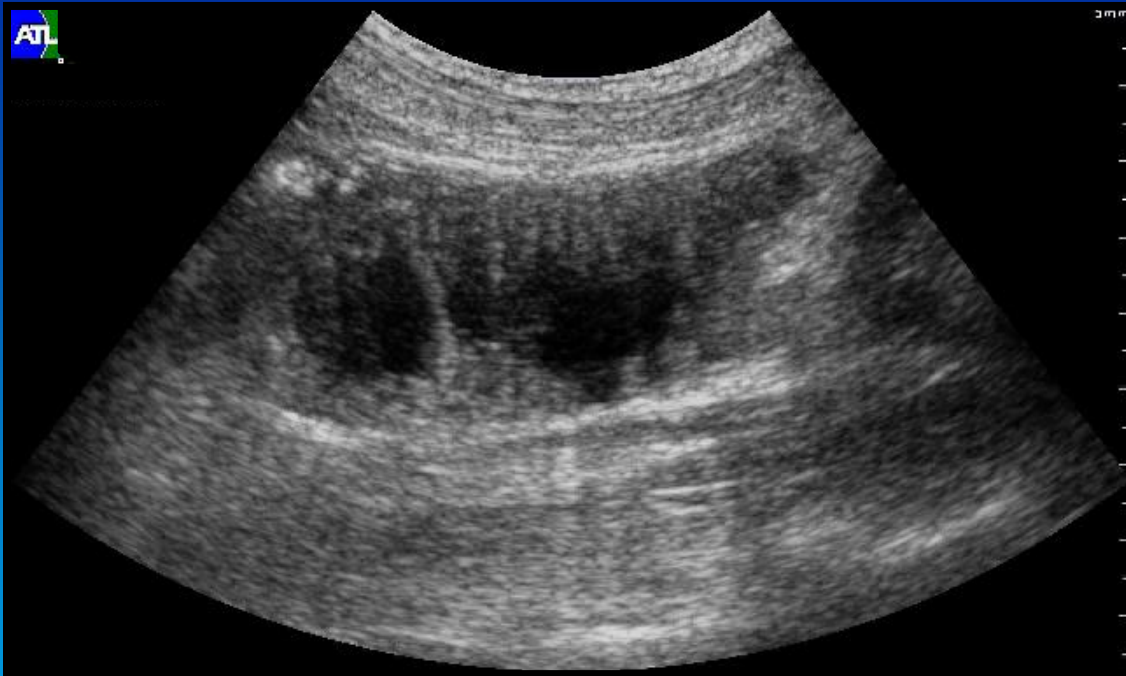# TTP: Tyndtarmspassage



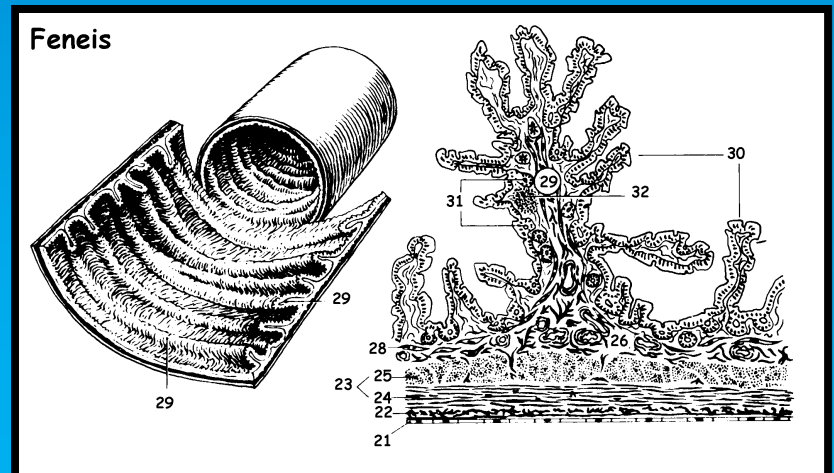
# MR af tyndtarm

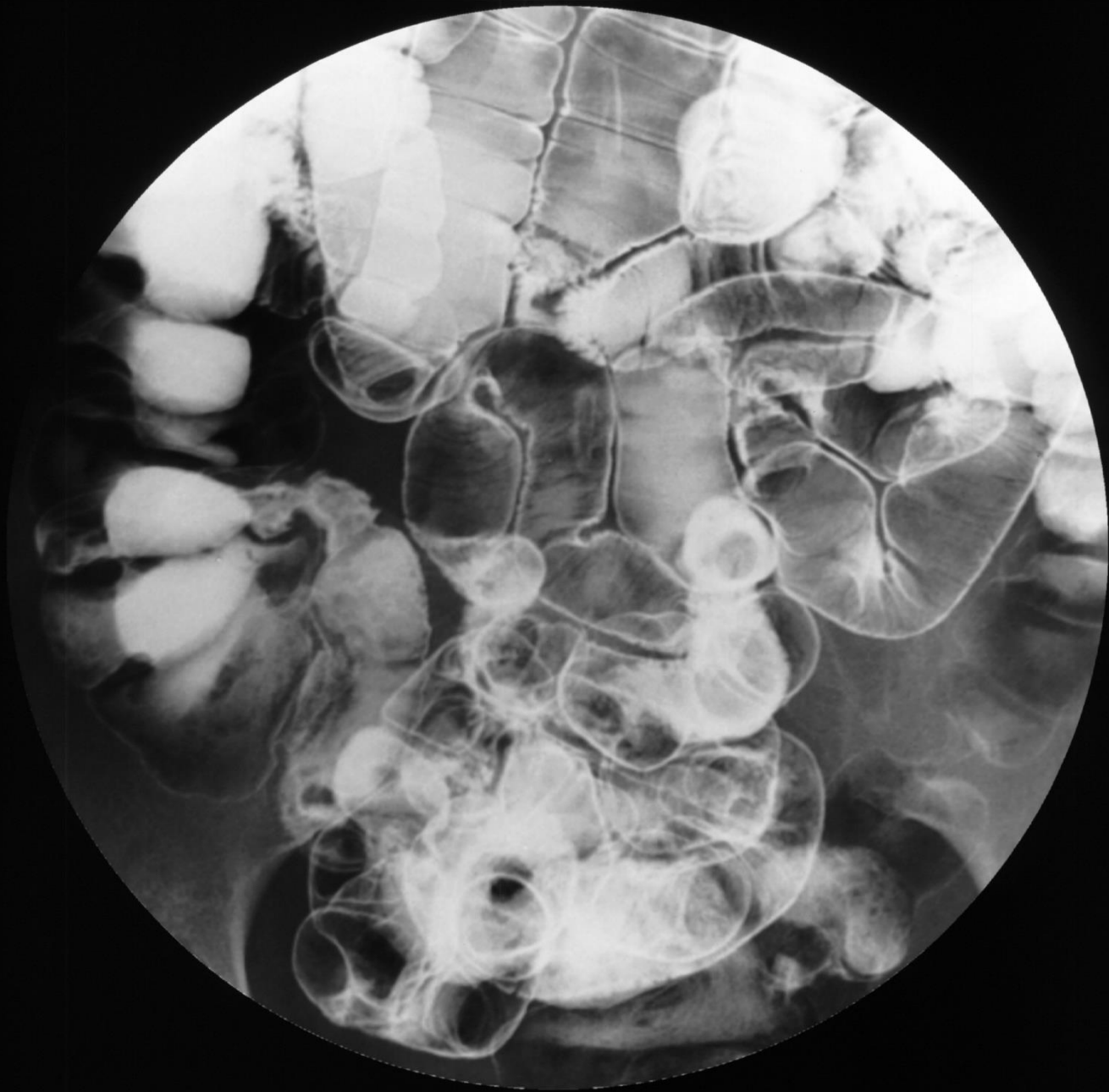

90 og 71 årig kvinder, jejunum- og ileum segment.

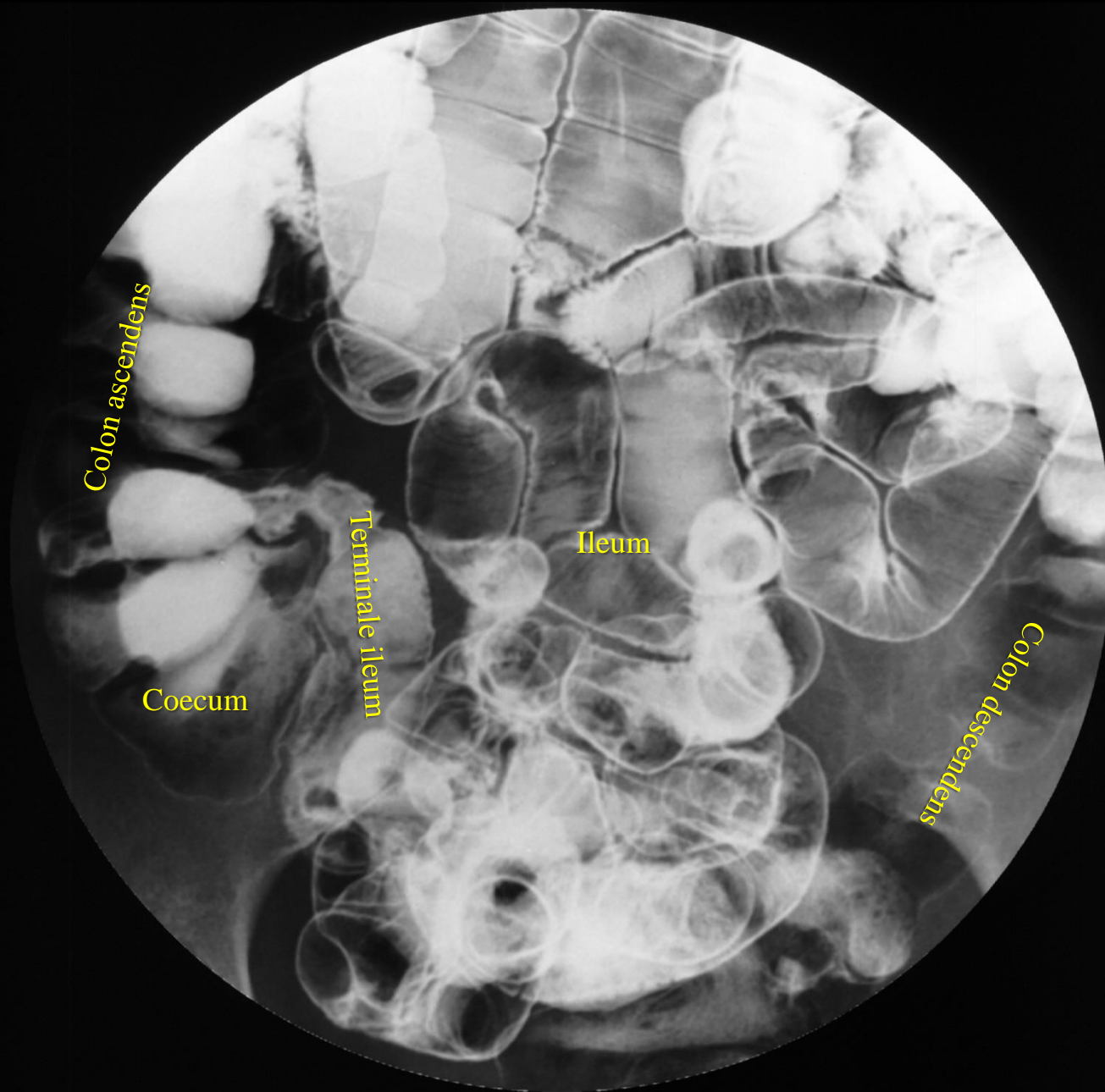


Ul af tyndtarm





Røntgenundersøgelse med dobbeltkontrast (TTP).



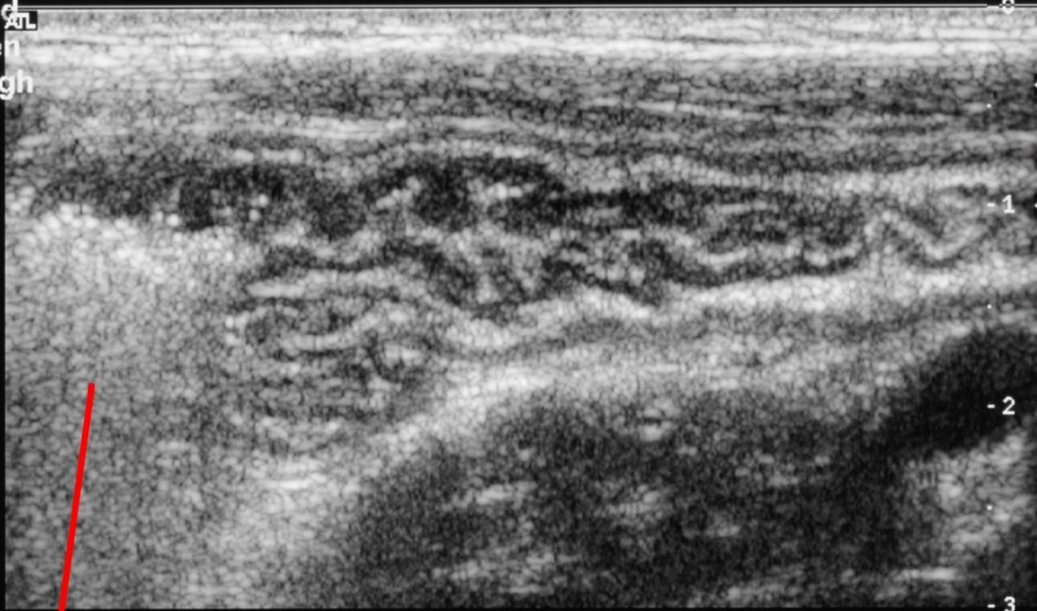
Røntgenundersøgelse med dobbeltkontrast (TTP).



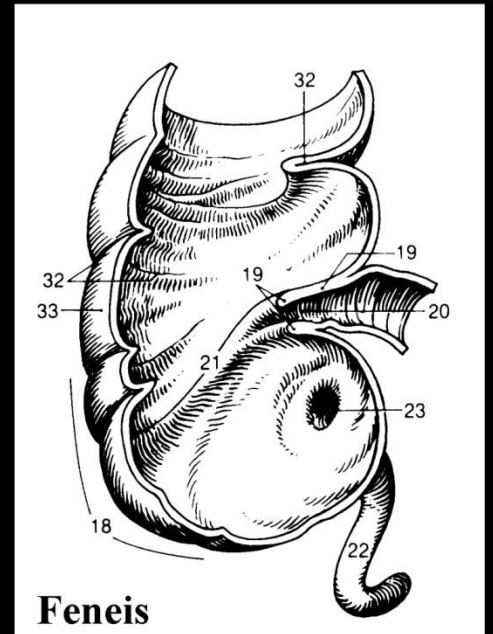
HDI  
5000

TIs 0.1 MI 0.60  
Fr #70 3.0 cm

Map 3  
150dB/C 4  
Persist Med  
2D Opt:Gen  
Fr Rate:High



**Terminale ileum**




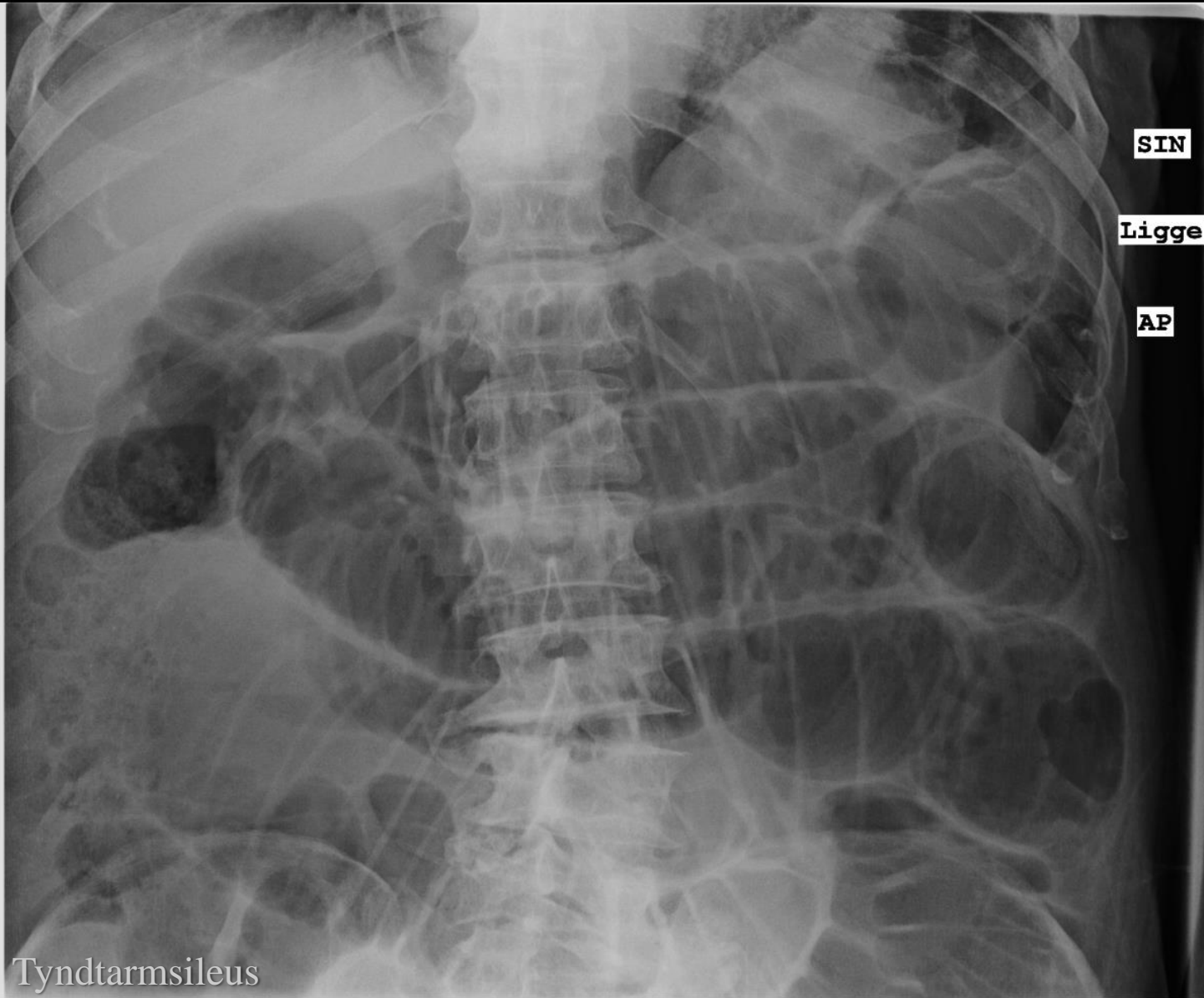
**Feneis**

**Caecum**

Ultralyd

# Ileus: Tarmslyng



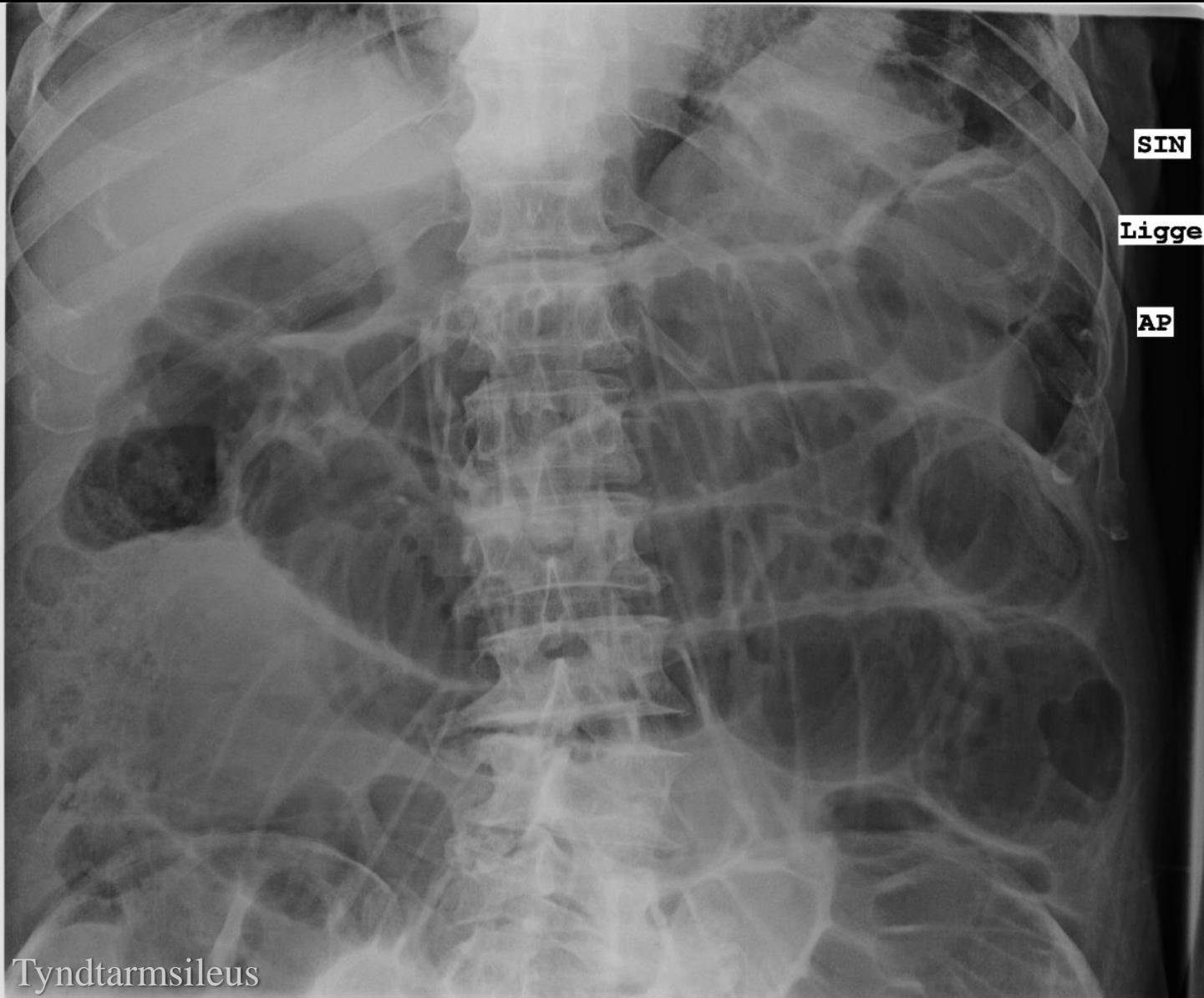

SIN

Ligge

AP

Tyndtarmsileus



SIN

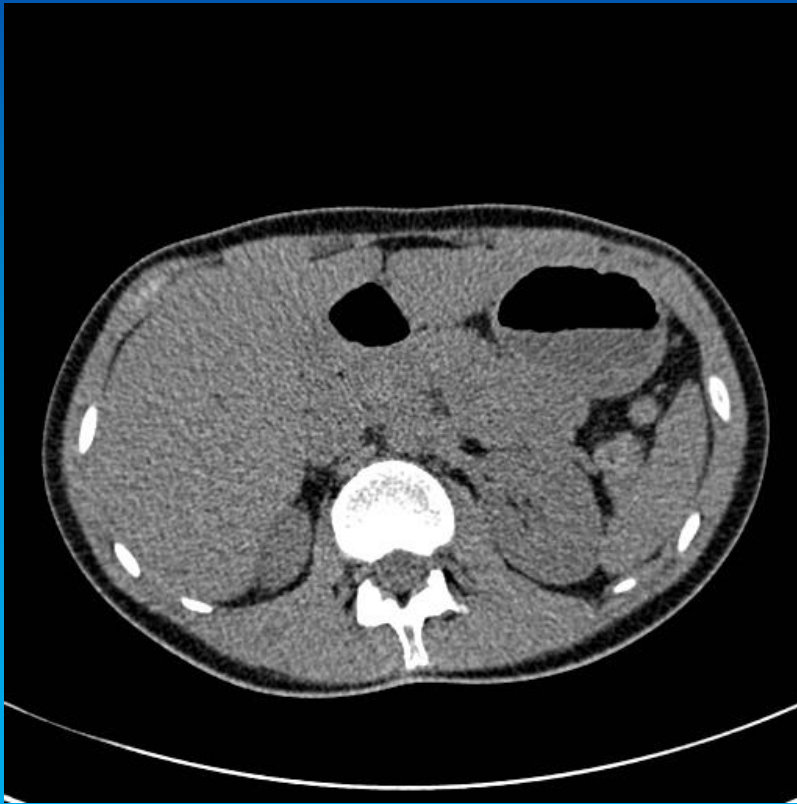
Ligge

AP

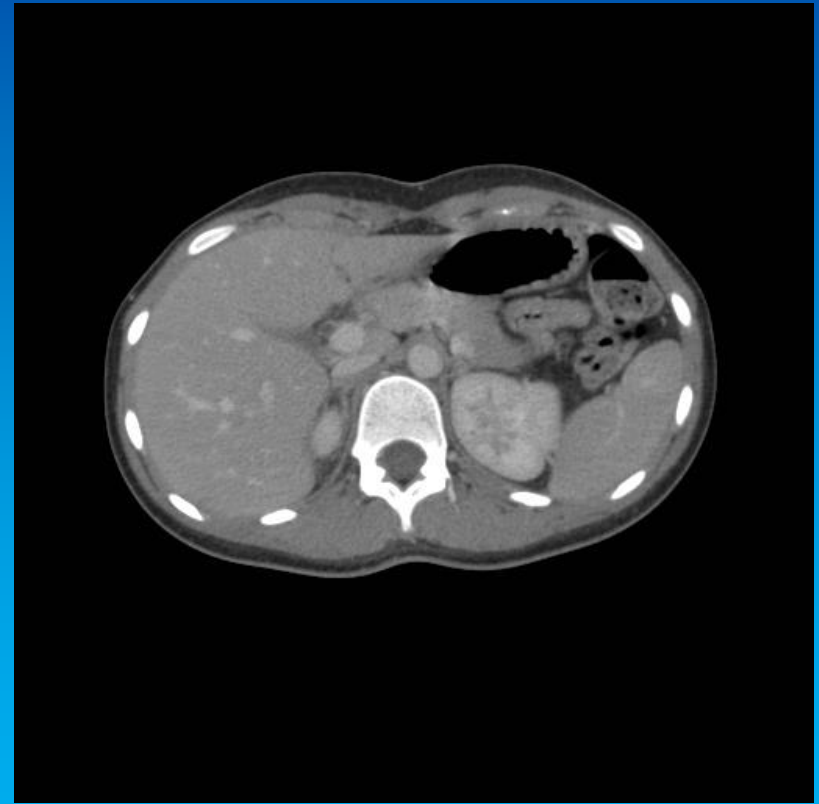
Tyndtarmsileus

# De parenkymatøse organer

# CT skanninger

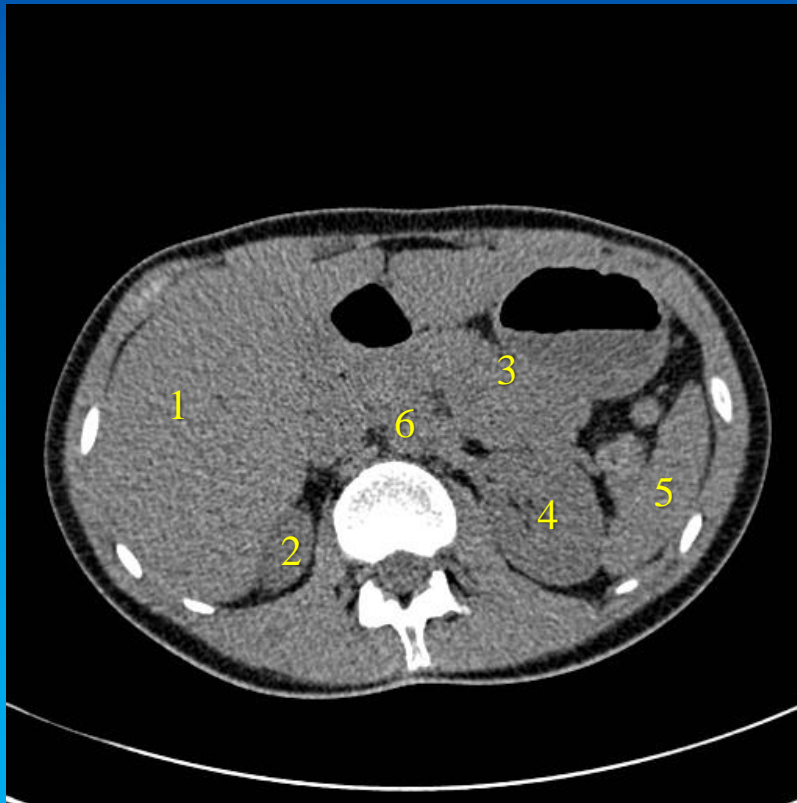


Lavdosis CT uden i.v. kontrast

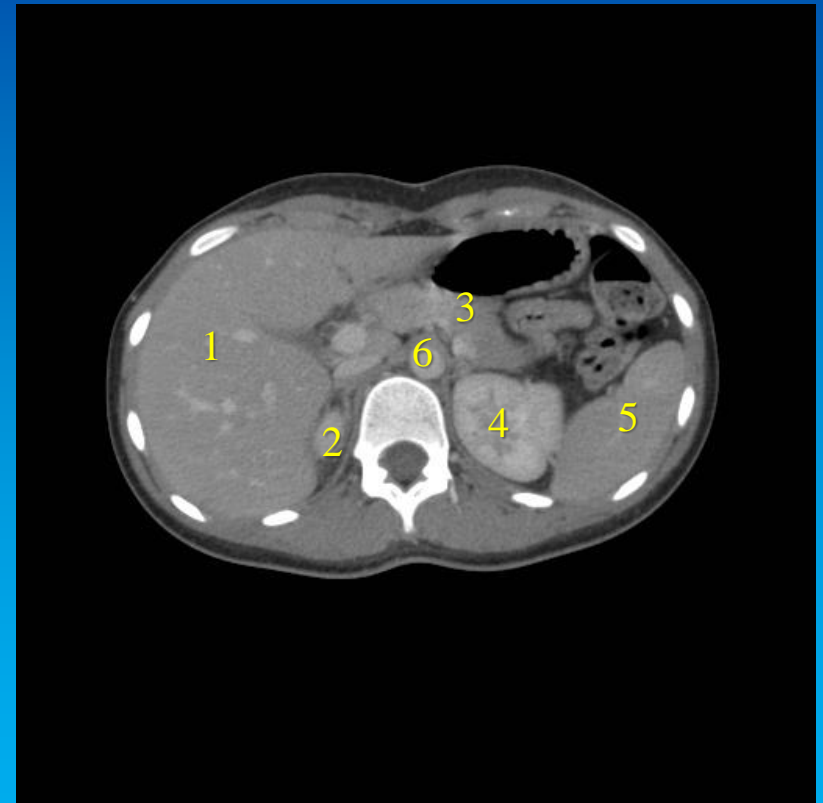


CT skanning med i.v. kontrast

To forskellige skanninger af yngre personer. Betydningen af i.v. kontrast for visualisering af organer ses af de to undersøgelser.

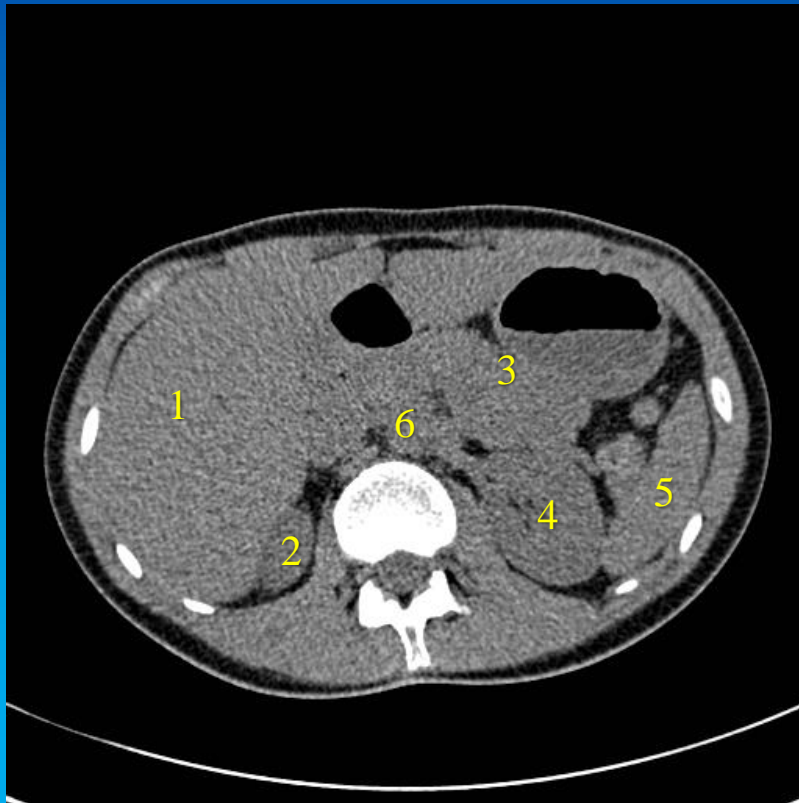


Lavdosis CT uden i.v. kontrast

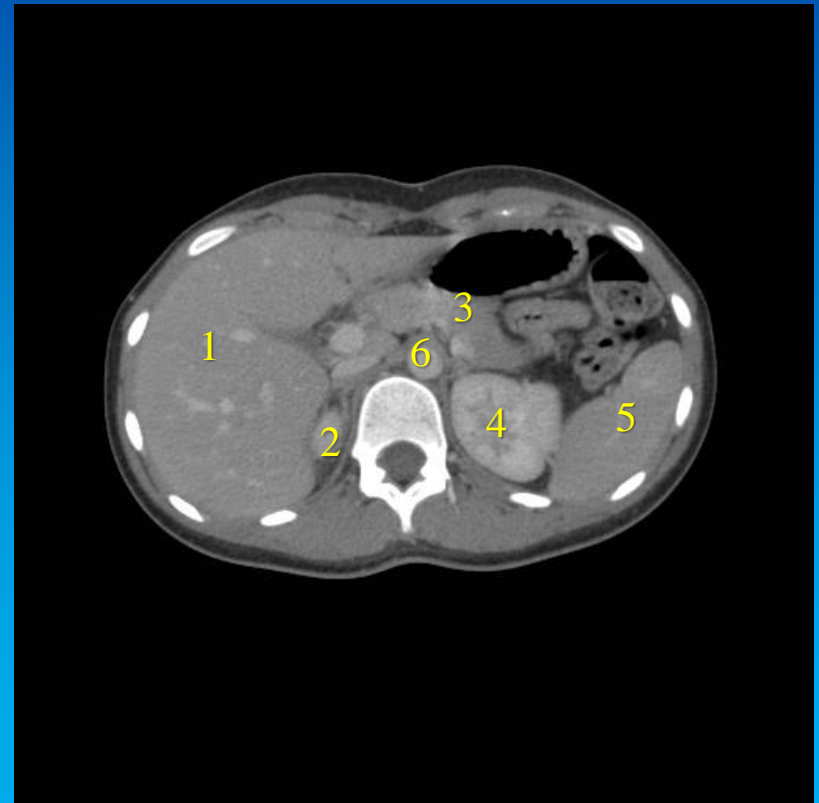


CT skanning med i.v. kontrast

1. Hepar
2. Ren dx.
3. Pancreas
4. Ren sin.
5. Spleen
6. Aorta



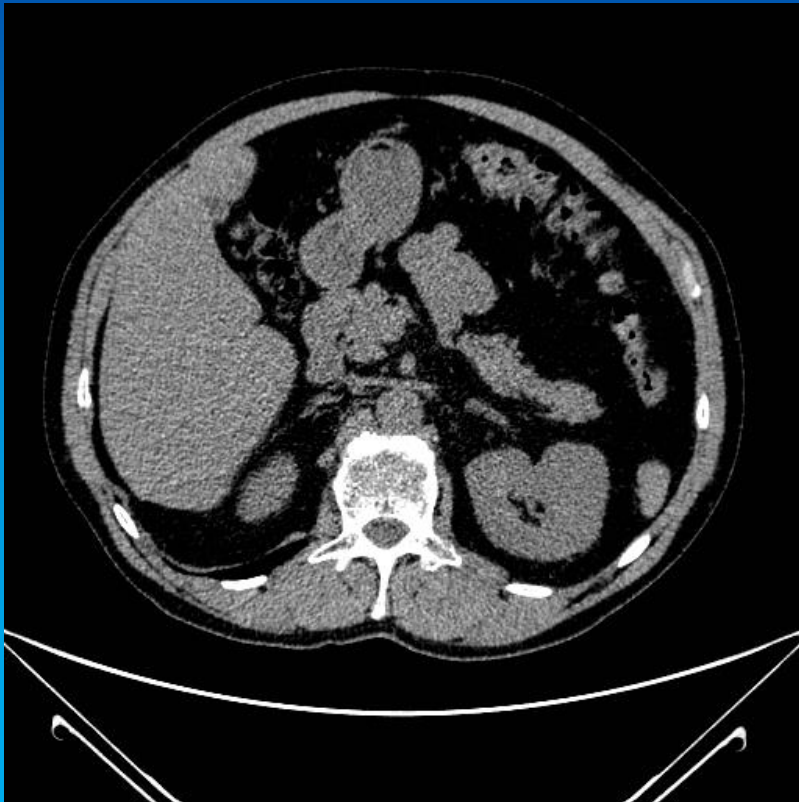
Lavdosis CT uden i.v. kontrast



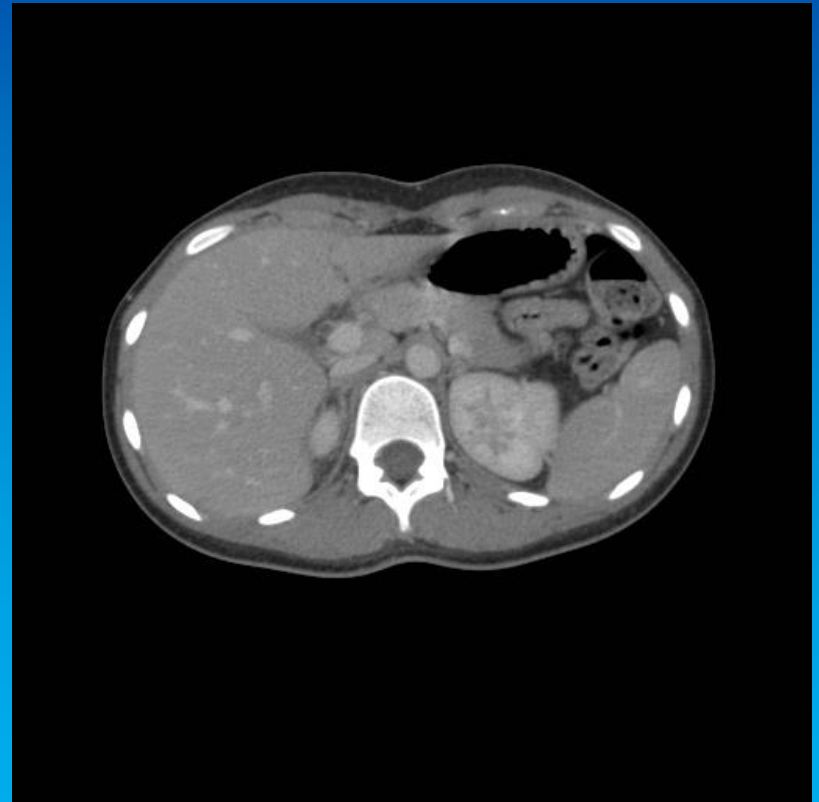CT skanning med i.v. kontrast



# CT skanninger



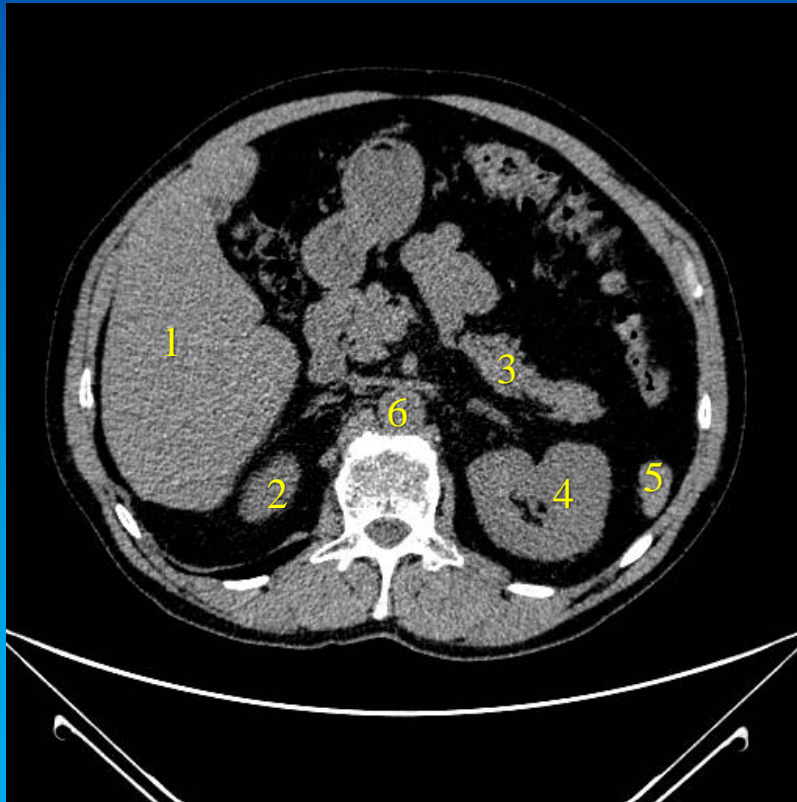
Lavdosis CT uden i.v. kontrast



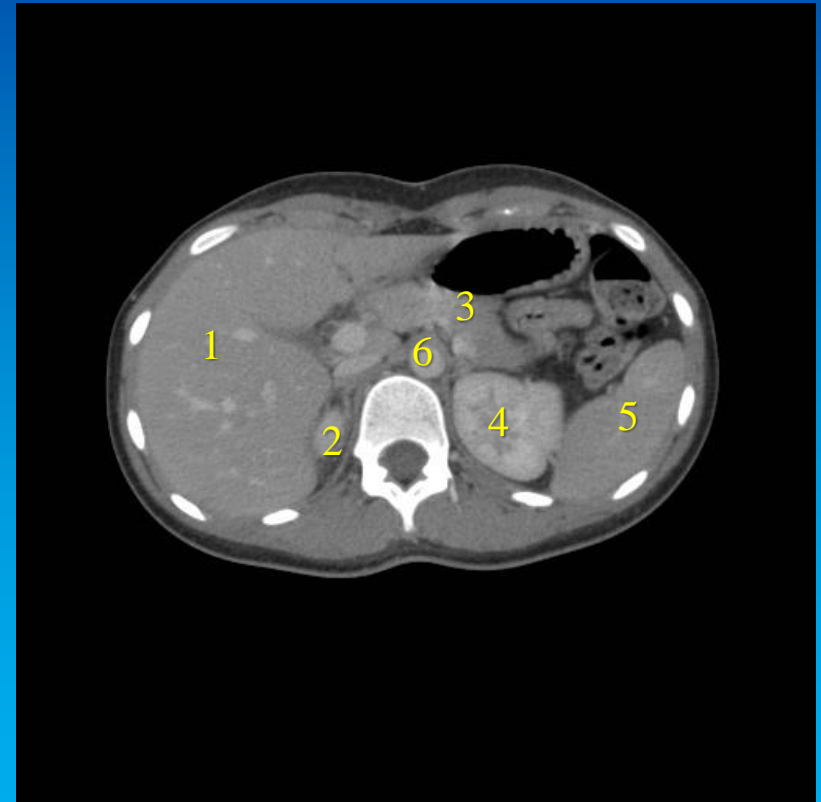
CT skanning med i.v. kontrast

1. Hepar
2. Ren dx.
3. Pancreas
4. Ren sin.
5. Spleen
6. Aorta

På undersøgelsen til venstre er der tale om midaldrende mand, på undersøgelsen til højre, en yngre kvinde. Manden ses at have en del fedtvæv intraabdominalt, der indirekte virker som kontrast. Bemærk at der ikke er benyttet samme W/L på de to billeder, idet det intraabdominale fedtvæv ikke har samme sorte farve.

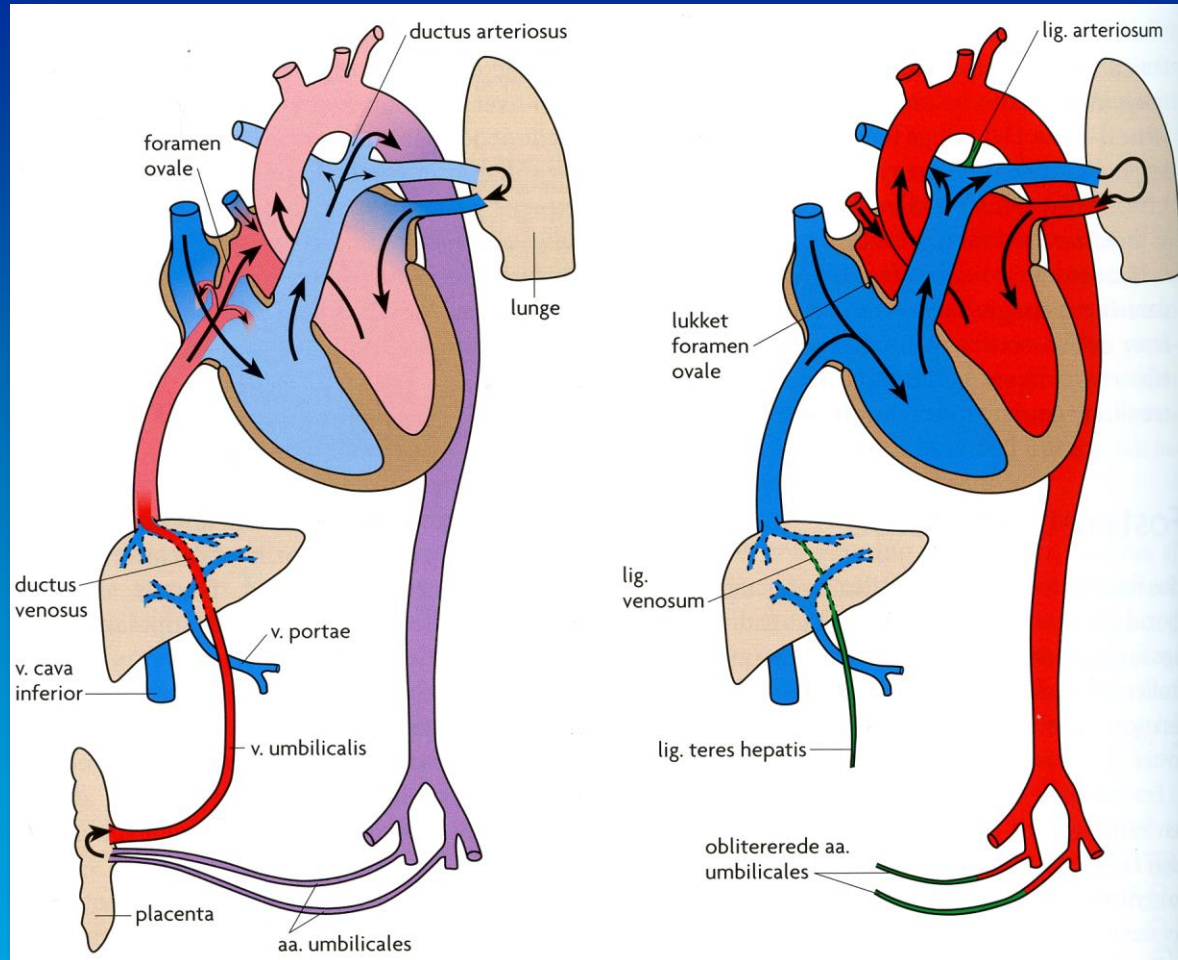


Lavdosis CT uden i.v. kontrast



CT skanning med i.v. kontrast

# Lever og galdeveje



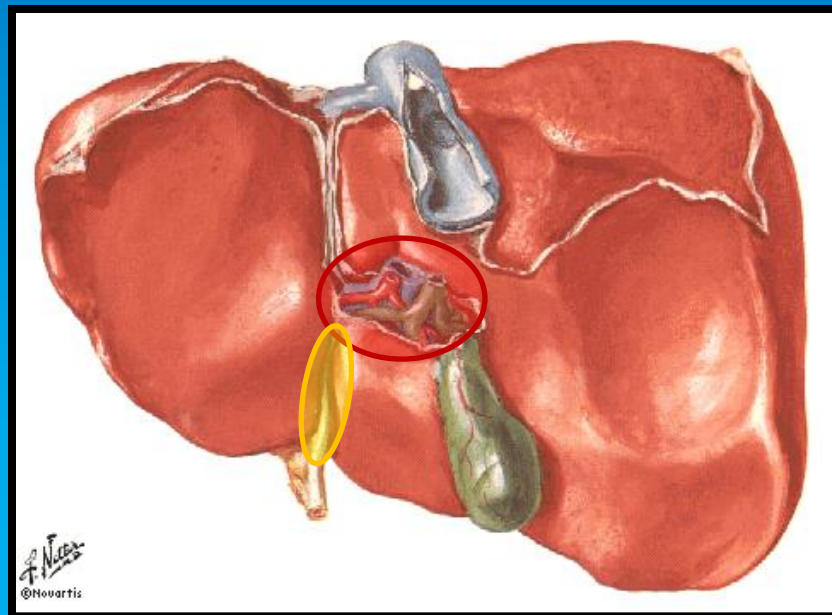
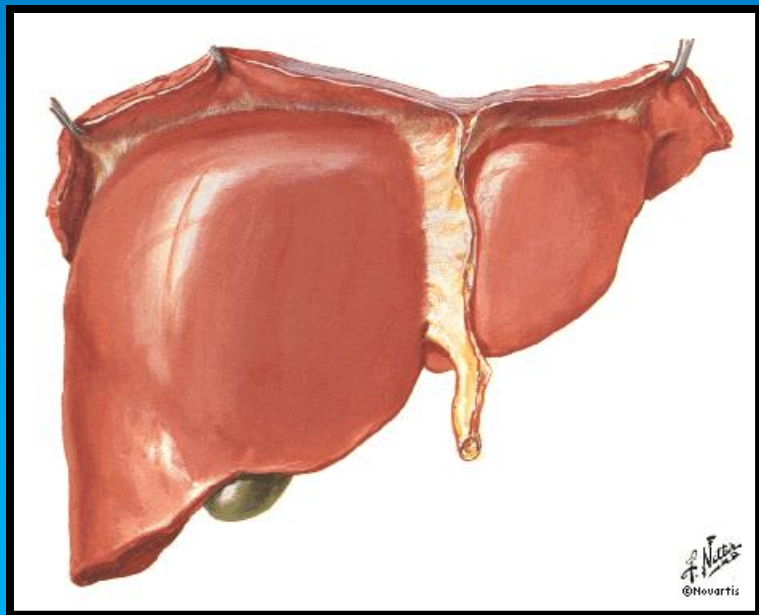
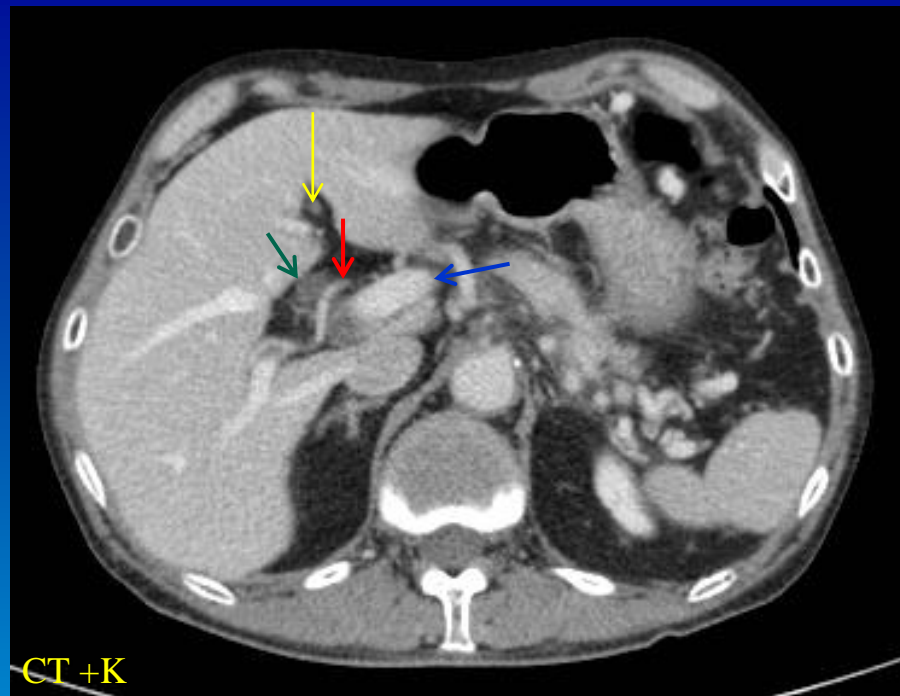
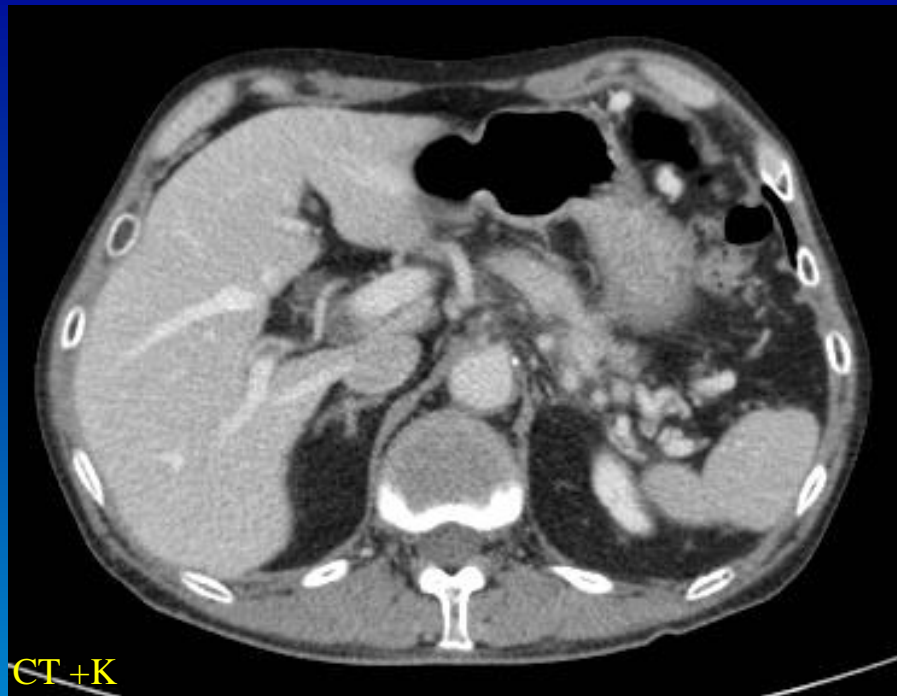
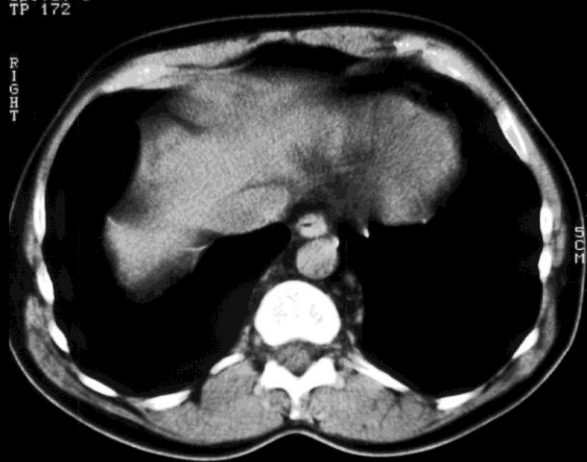
Image 24  
15:34:06.2  
Spiral 3  
TP 172

ANTERIOR

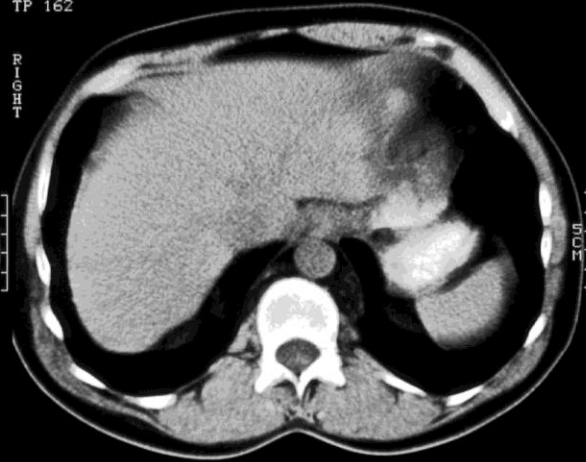
R  
I  
G  
H  
T



R  
I  
G  
H  
T

Image 24  
15:34:06.2  
Spiral 3  
TP 162

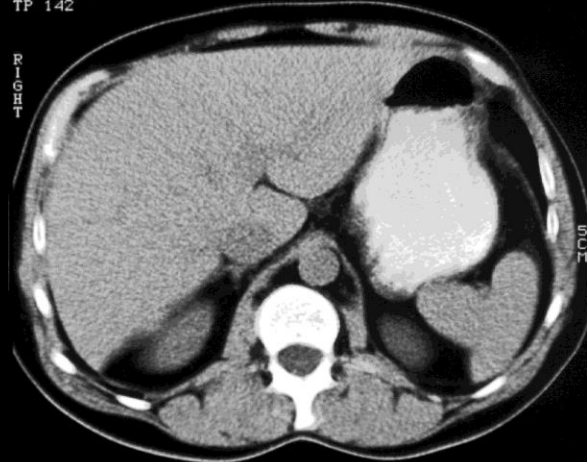
ANTERIOR



R  
I  
G  
H  
T

Image 25  
15:34:08.3  
Spiral 3  
TP 142

ANTERIOR



oral

H 292  
C 49

oral

H 292  
C 49

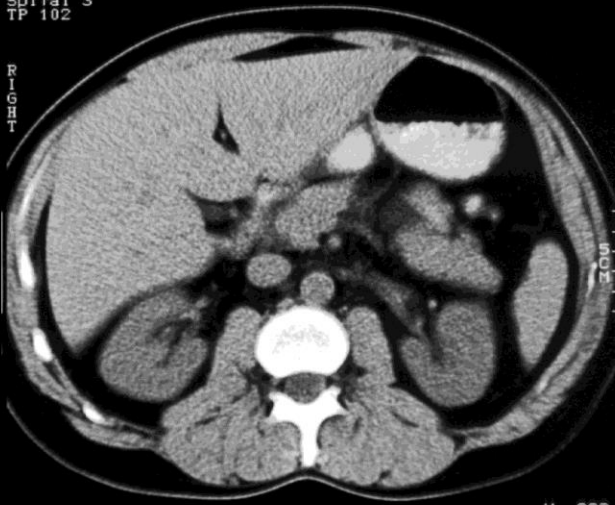
oral

H 292  
C 49

Image 30  
15:34:12.3  
Spiral 3  
TP 102

ANTERIOR

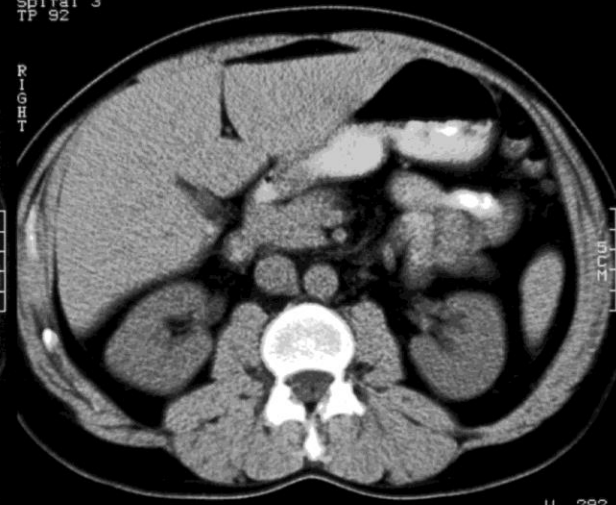
R  
I  
G  
H  
T



R  
I  
G  
H  
T

Image 31  
15:34:13.3  
Spiral 3  
TP 92

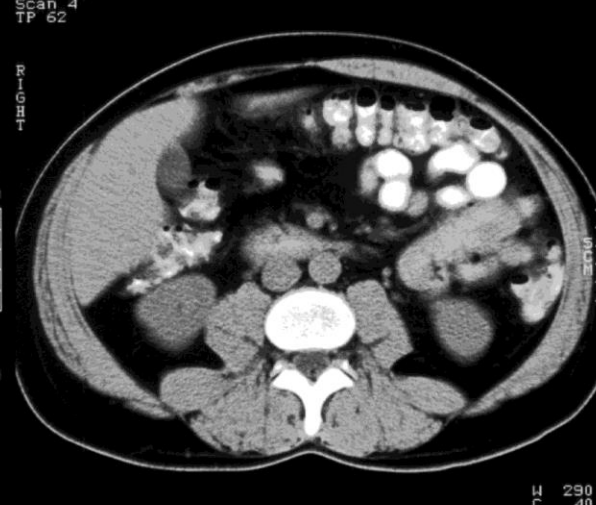
ANTERIOR



R  
I  
G  
H  
T

Image 34  
15:43:36  
Scan 4  
TP 62

ANTERIOR



oral

H 292  
C 49

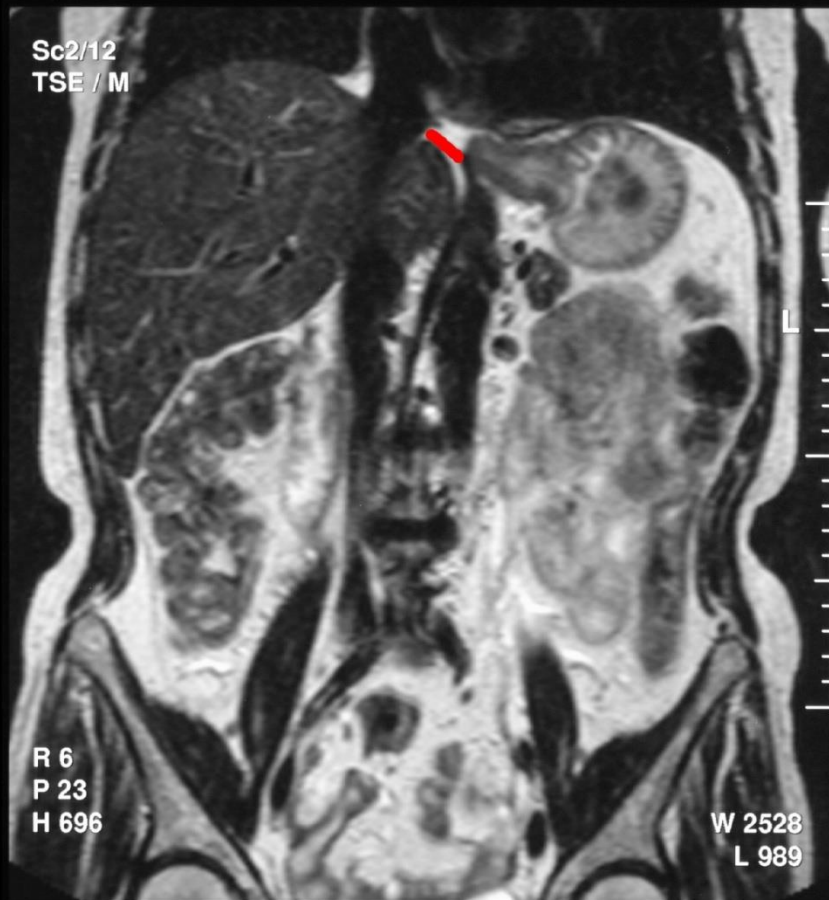oral

H 292  
C 49

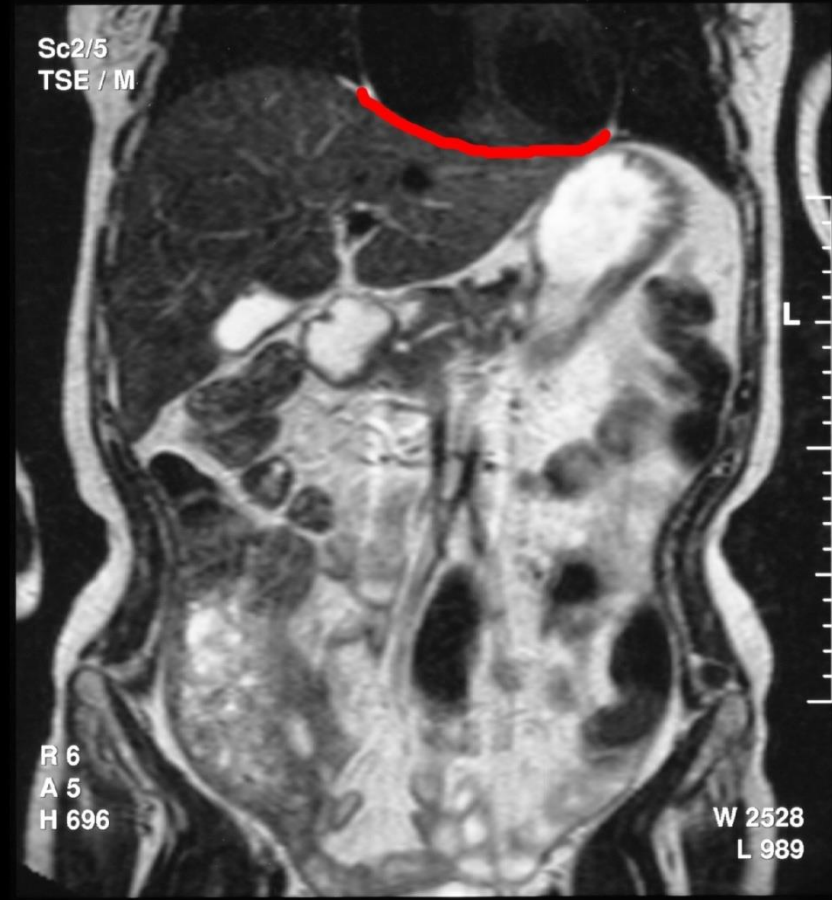oral

H 290  
C 40

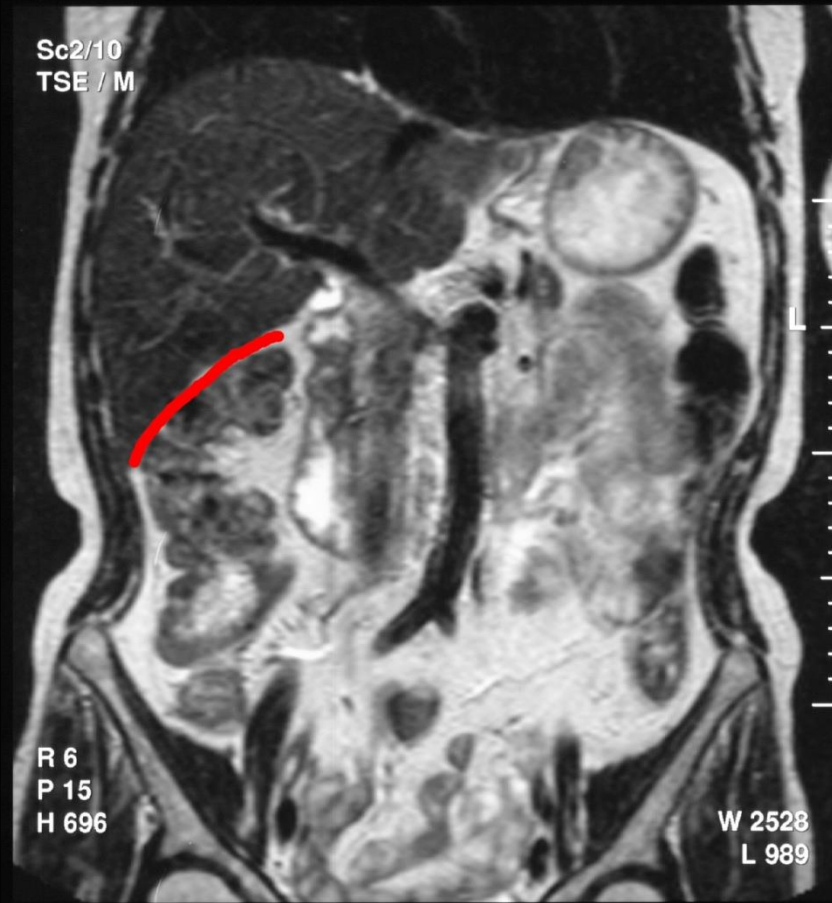
## Impressio oesophageale



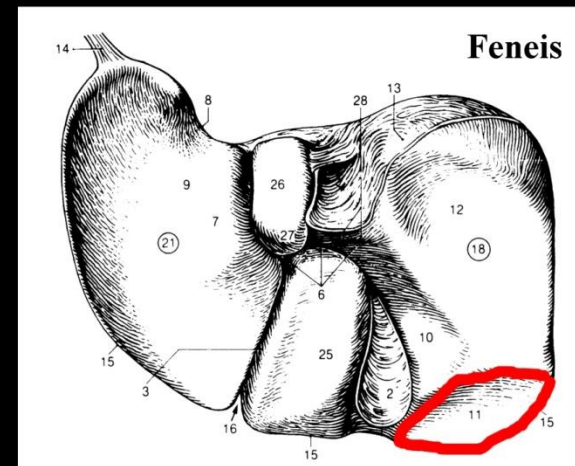
## Impressio cardiaca



# Impressio colica

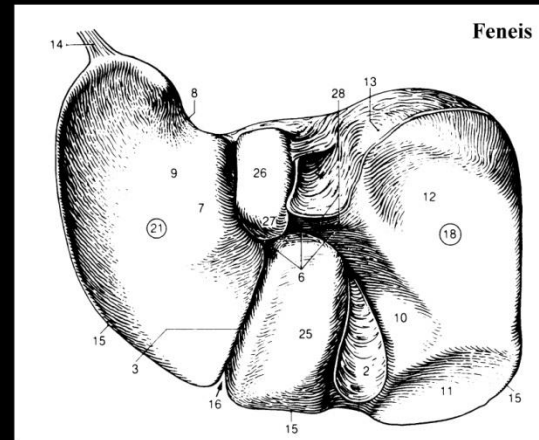
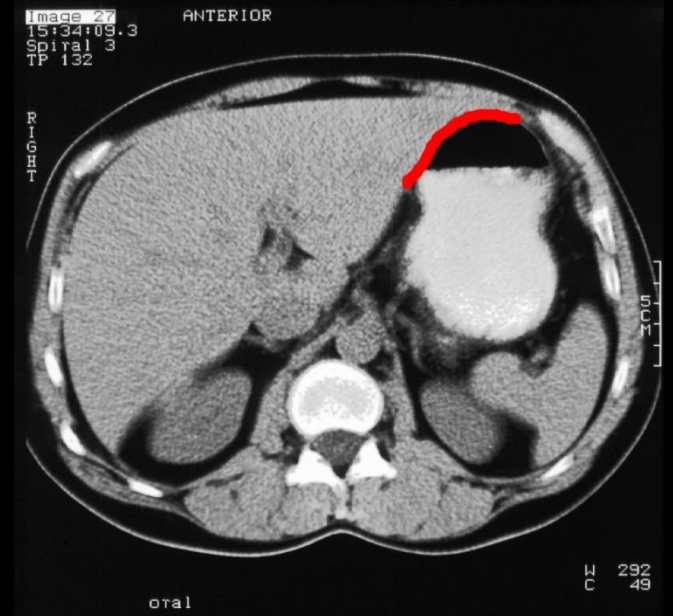
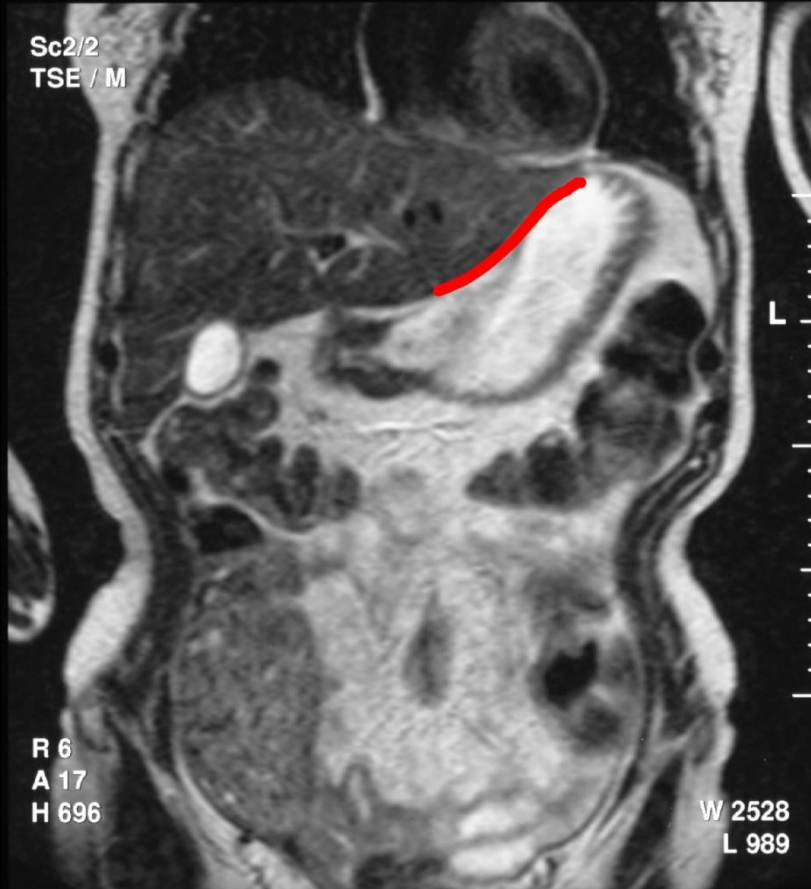


MR T2



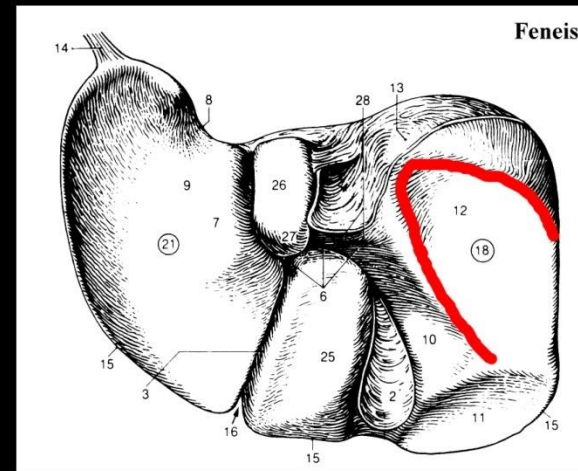
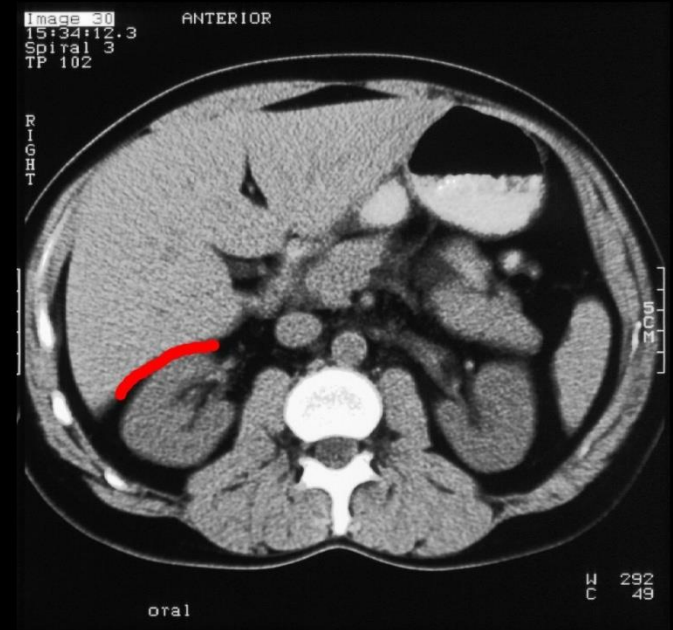
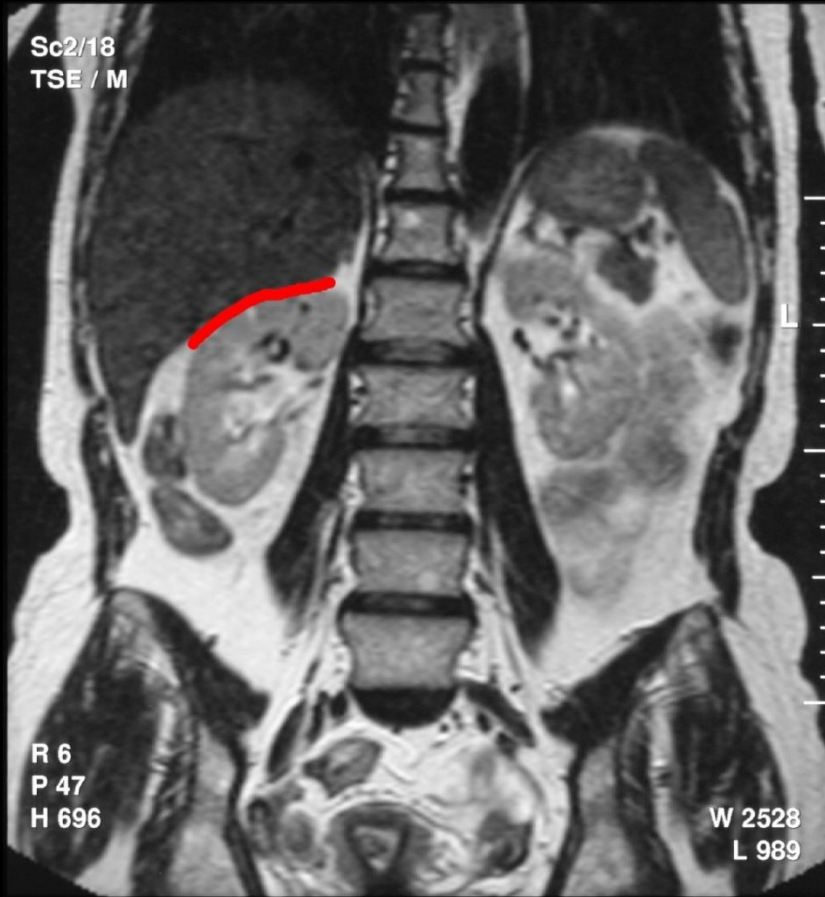


# Impressio gastrica

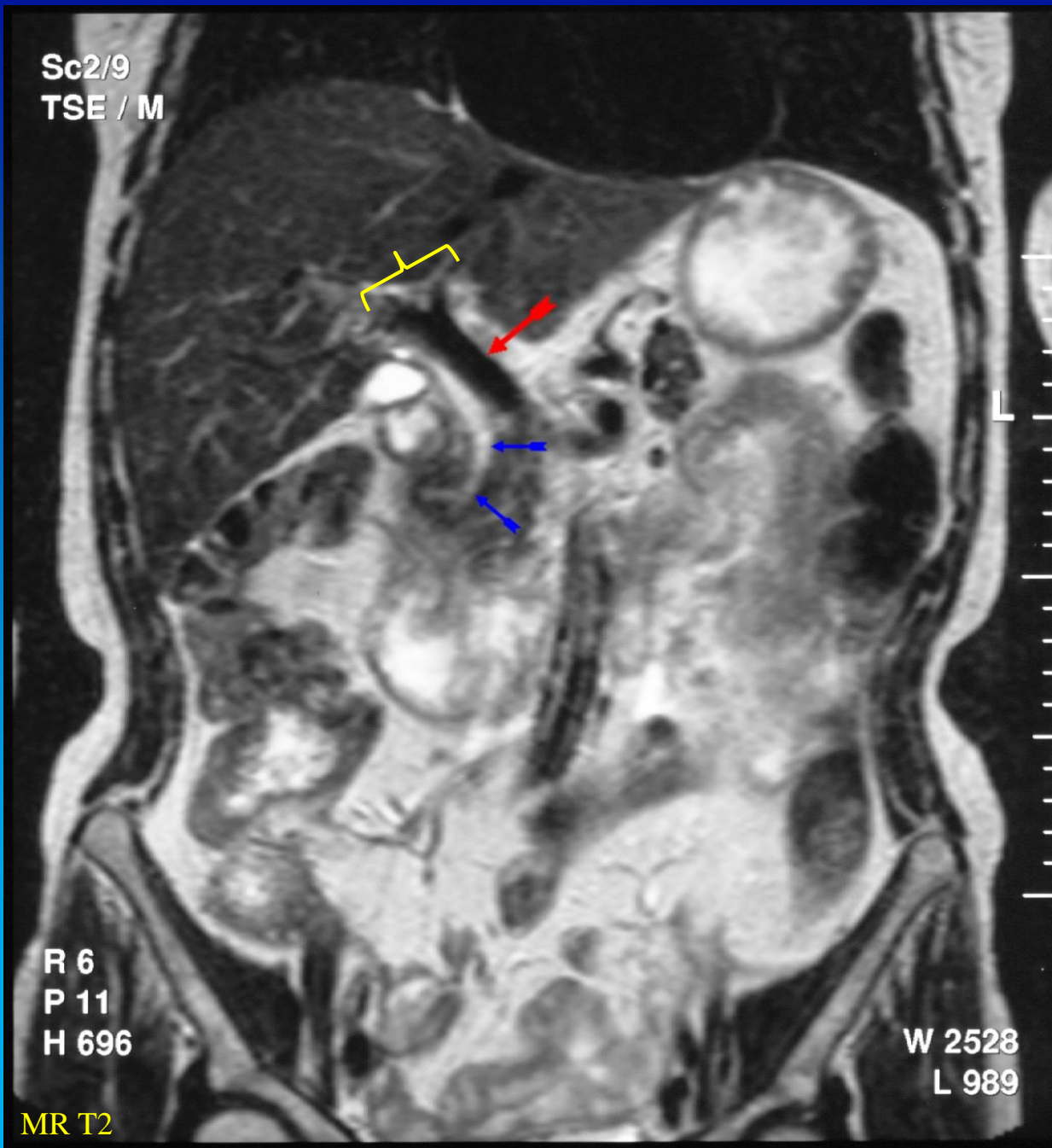


MR T2

# Impressio renalis



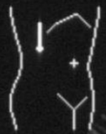Sc2/9  
TSE / M



Porta hepatis

Map 3  
150dB/C 3  
Persist Med  
2D Opt:Gen  
Fr Rate:High

ATL



Map 3  
150dB/C 3  
Persist Med  
2D Opt:Gen  
Fr Rate:High

ATL

Vena  
hepatica

V. cava inferior

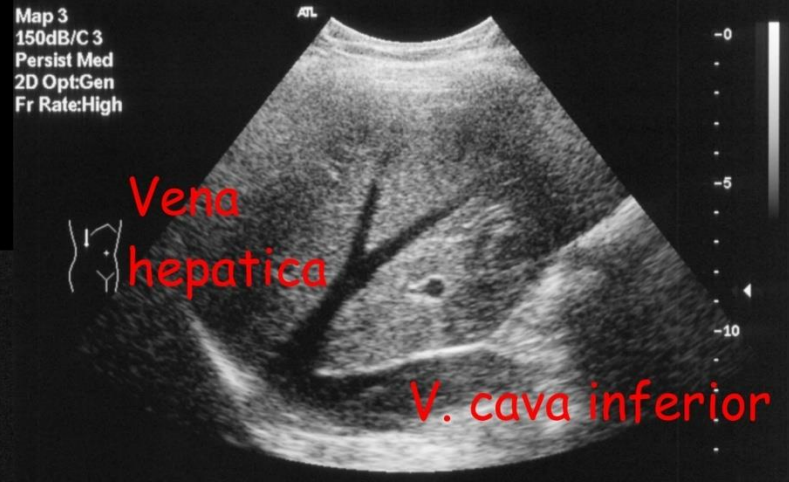
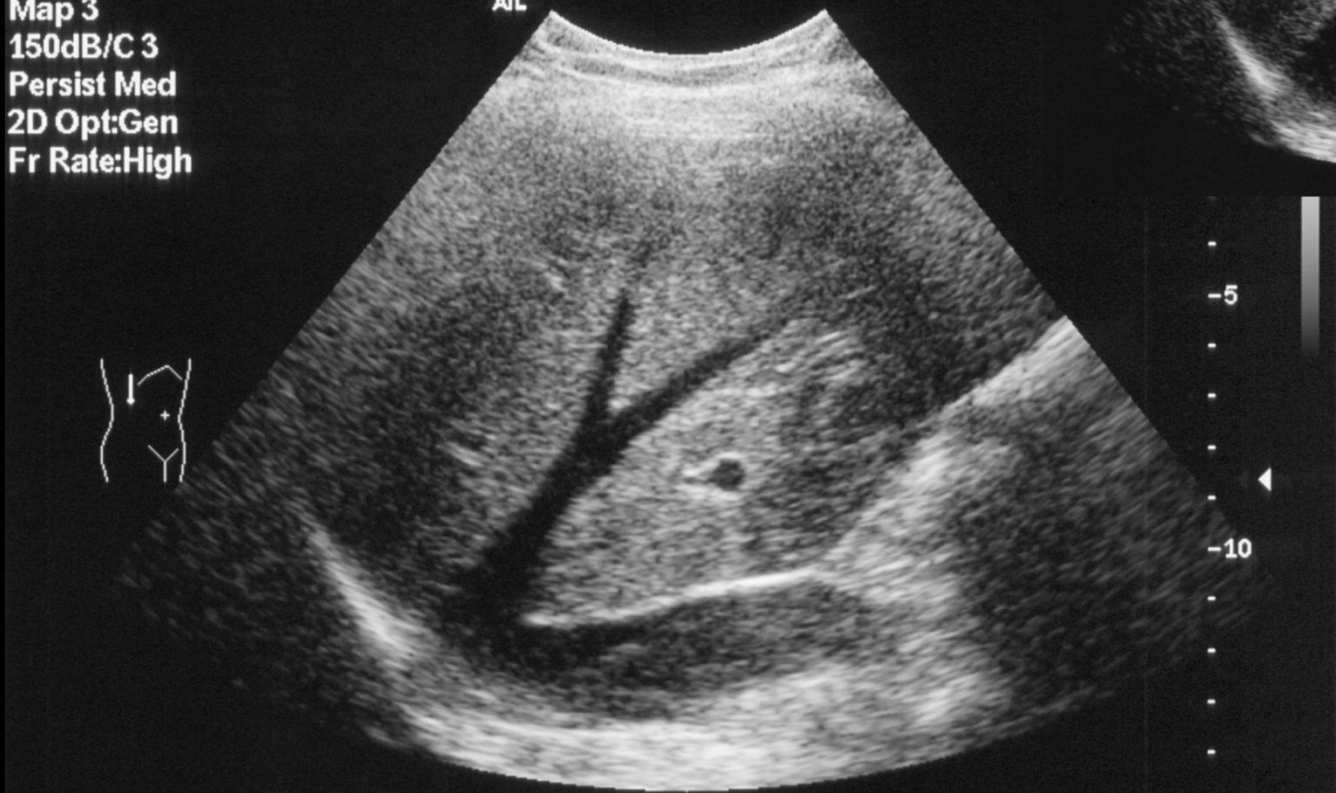-5

-10

-0

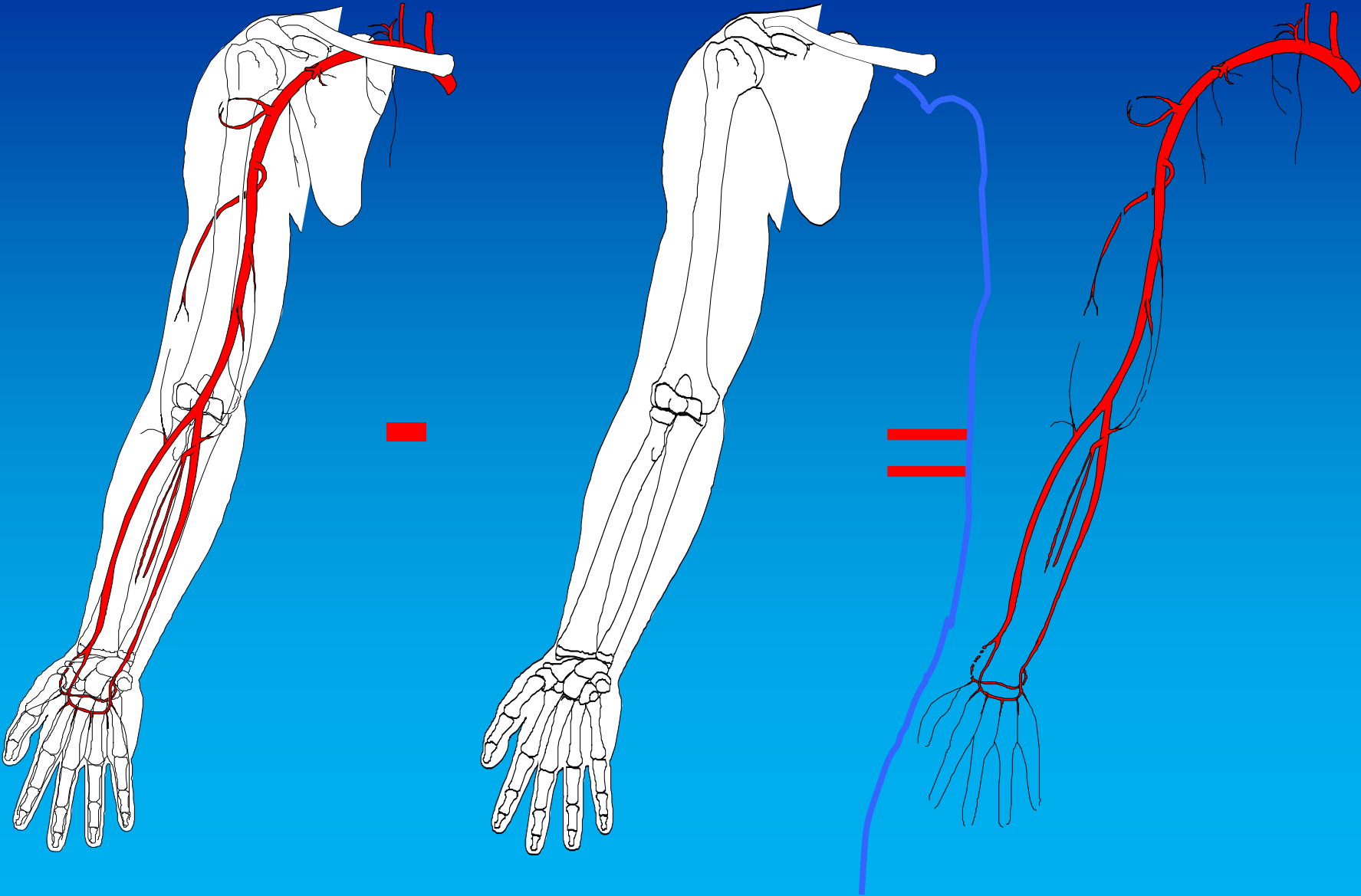
-5

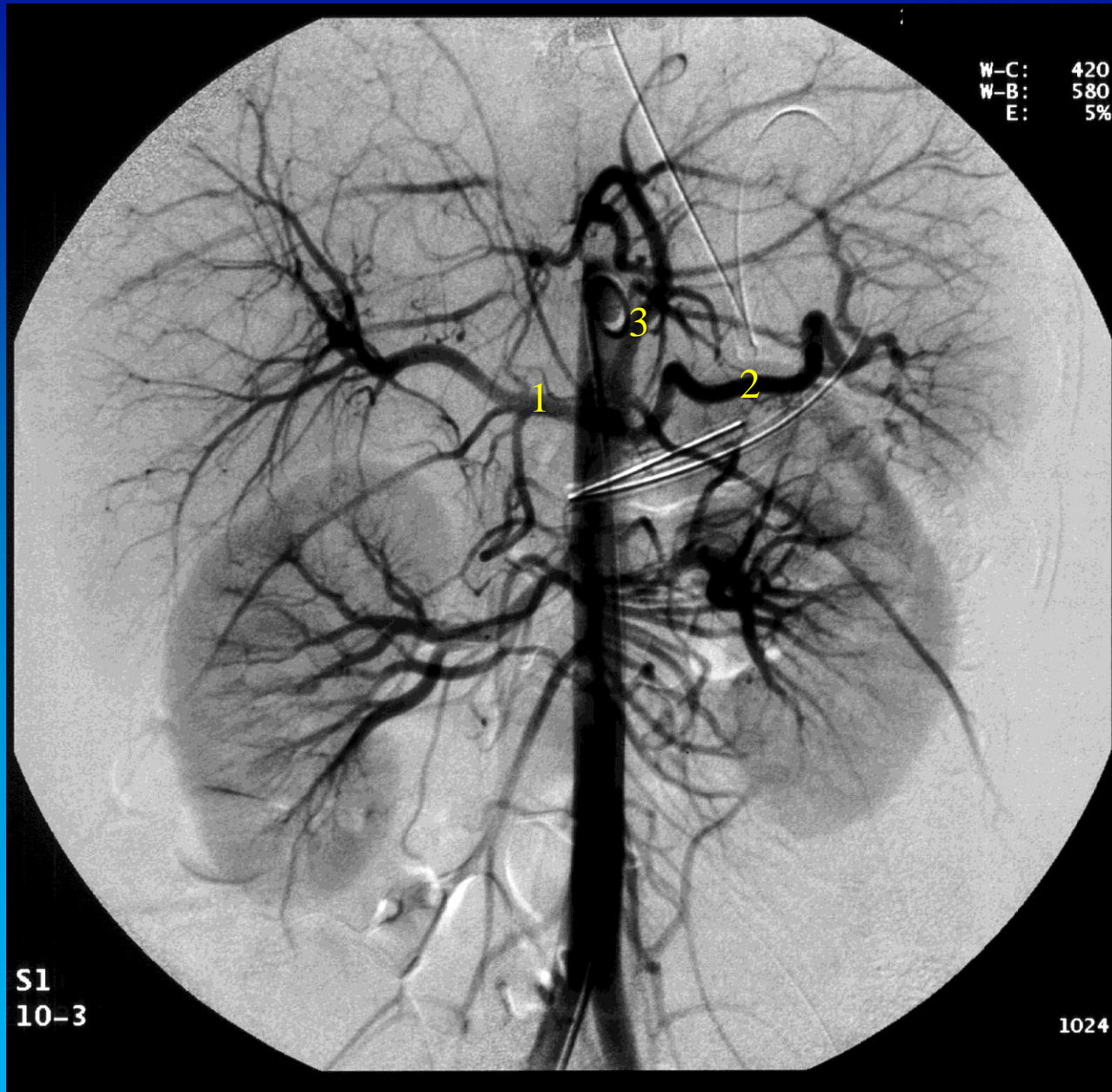
-10



# Abdominal angiografi

# DSA: Digital subtraktions angiografi

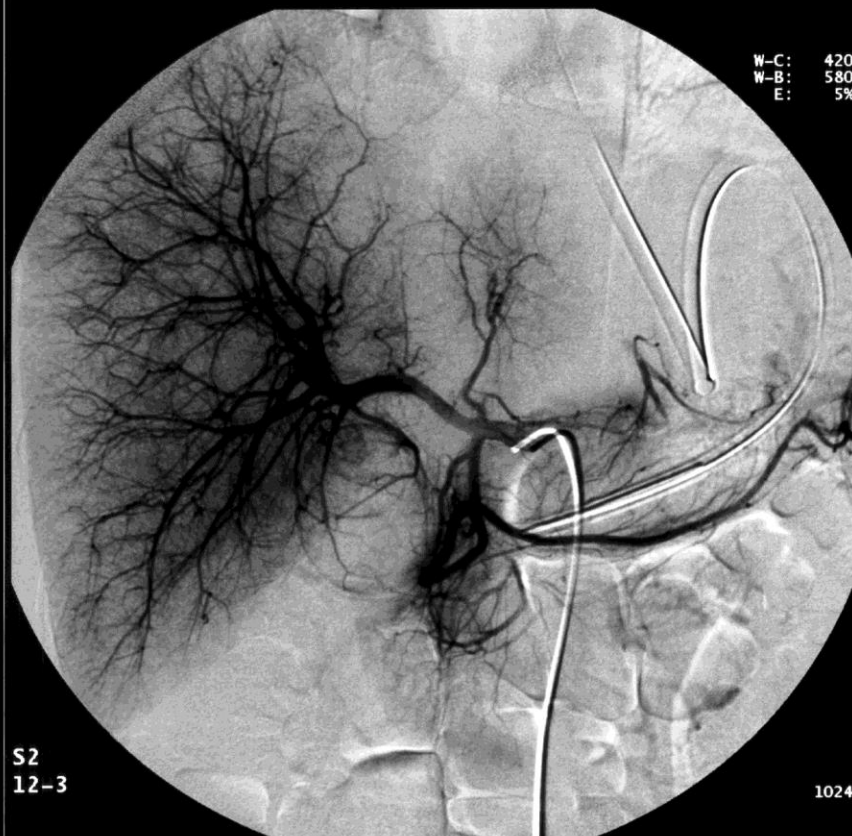
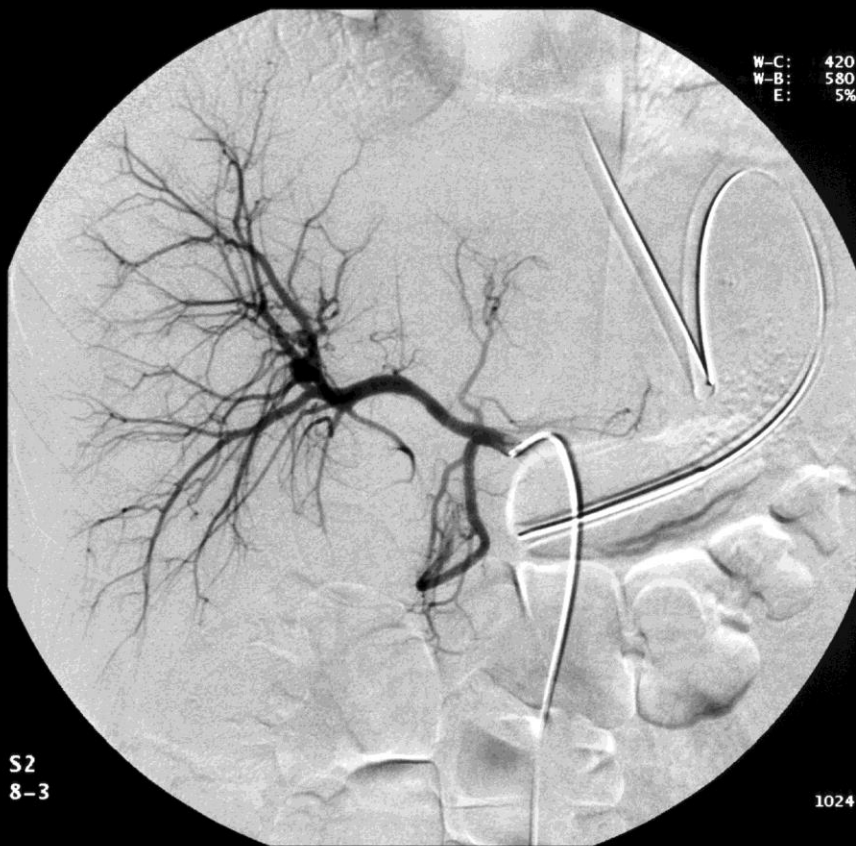



## Abdominal aortografi

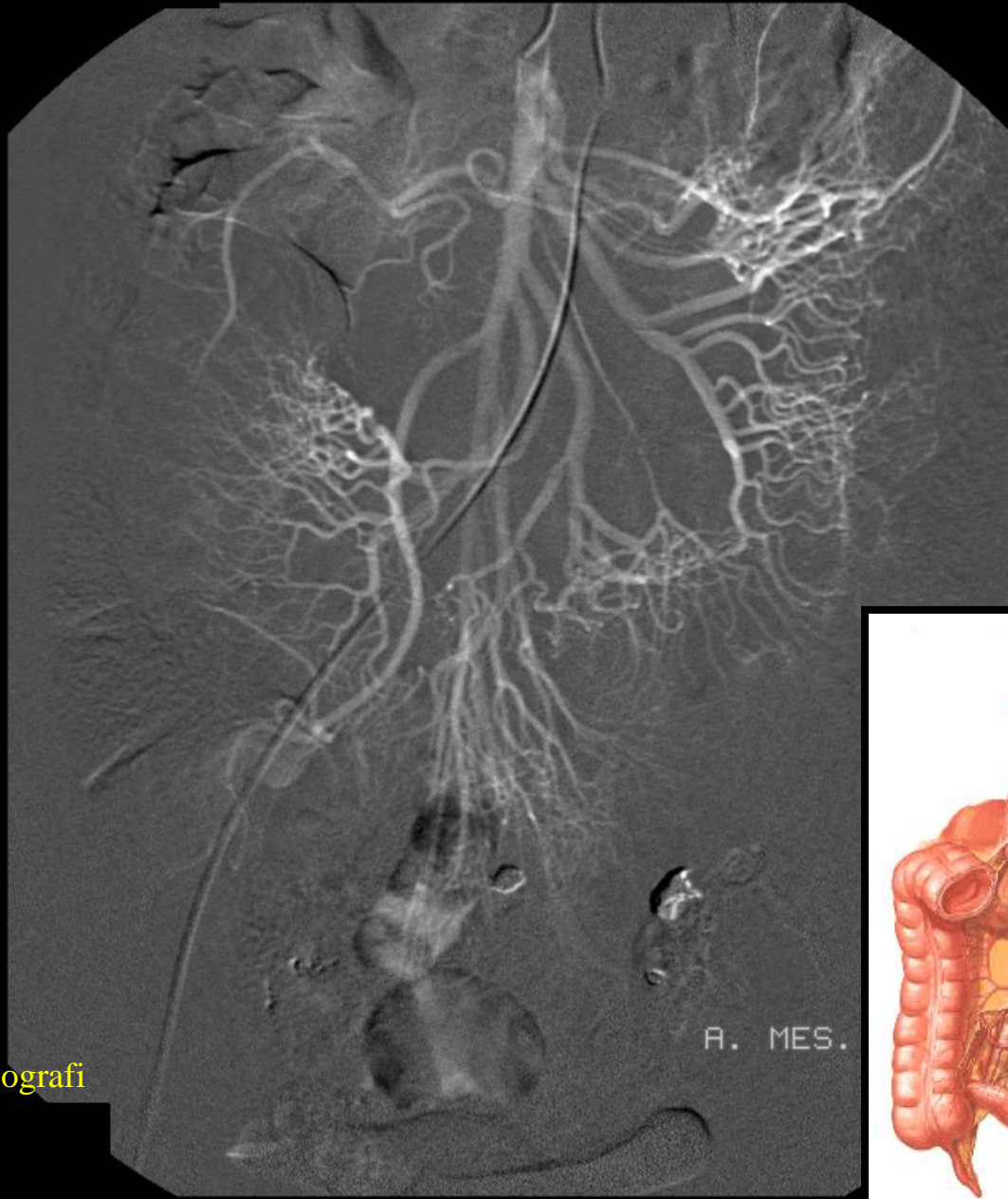
Truncus coeliacus:

- 1) A. hepatica communis
- 2) A. splenica
- 3) A. gastrica sinistra



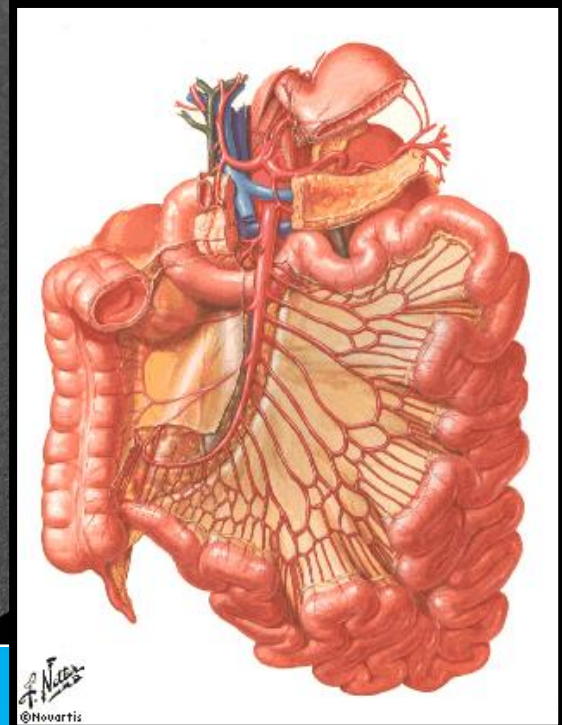
A. hepatica communis angiografi





A. MES.

A. mesenterica sup. angiografi



A. mesenterica sup.

A. colica dx.

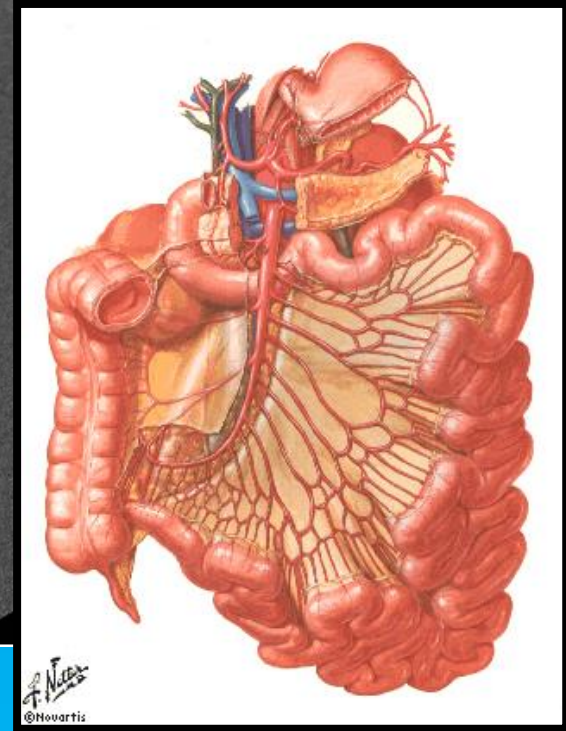
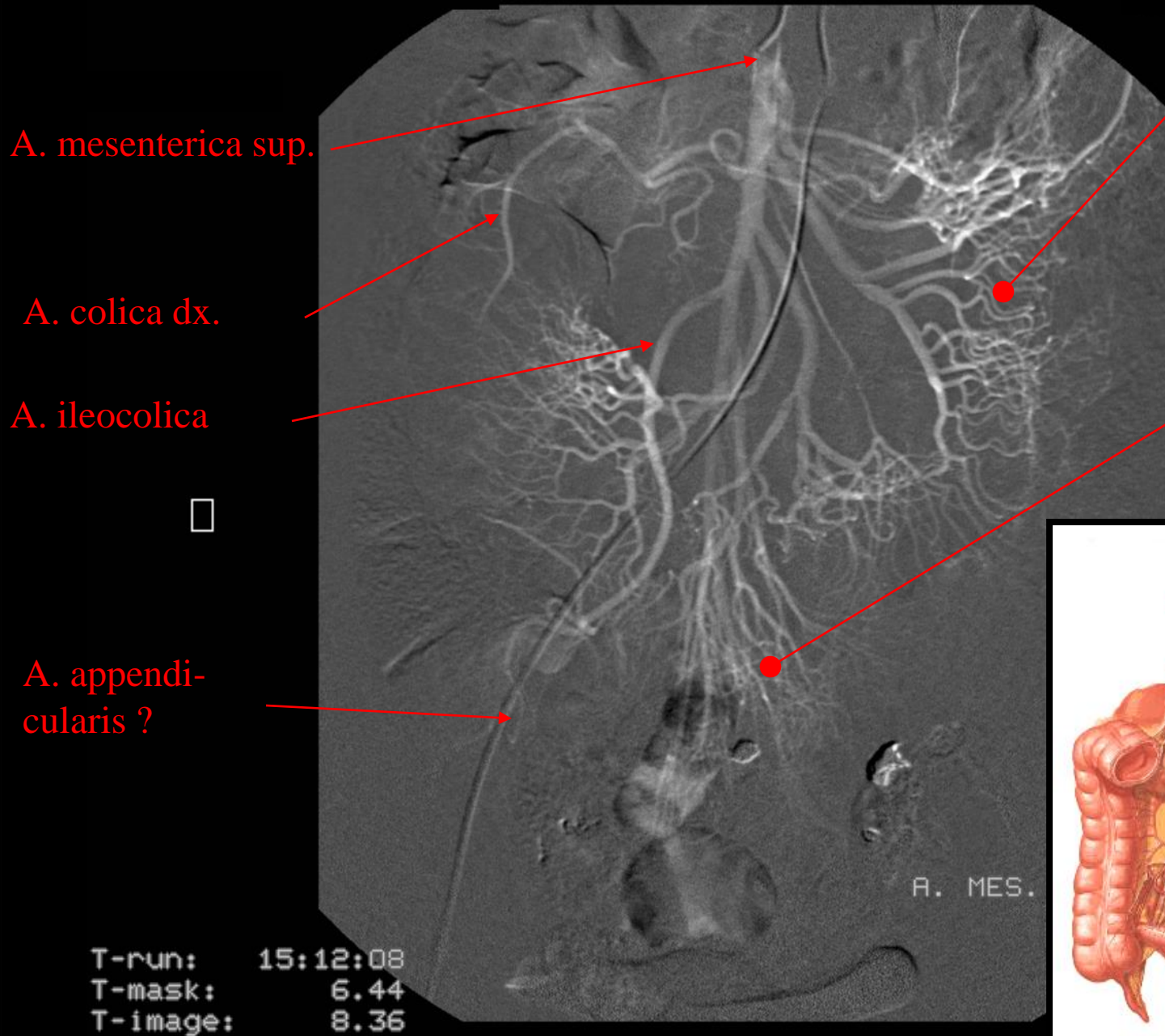
A. ileocolica



A. appendicularis ?

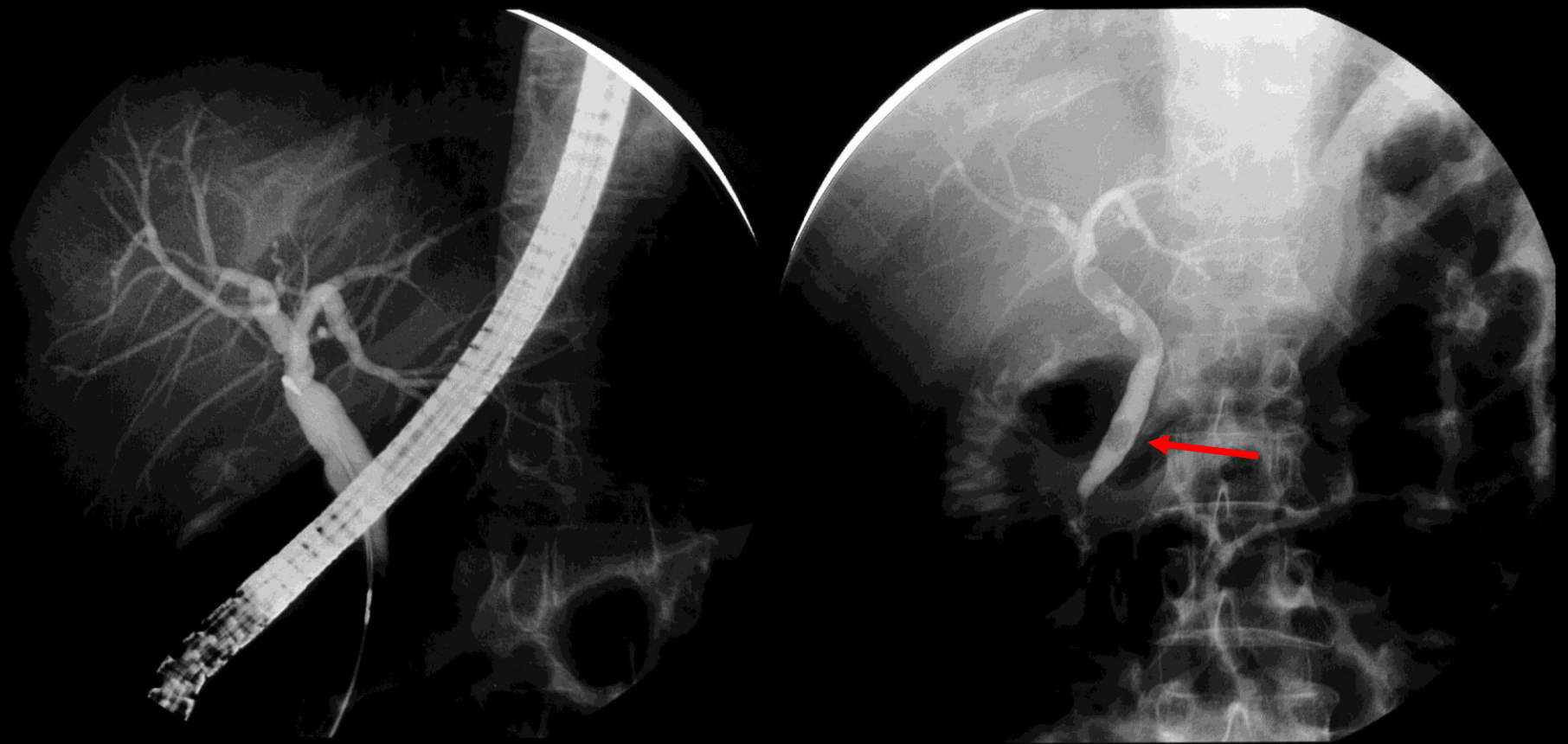
Aa. jejunales

Aa. ileales

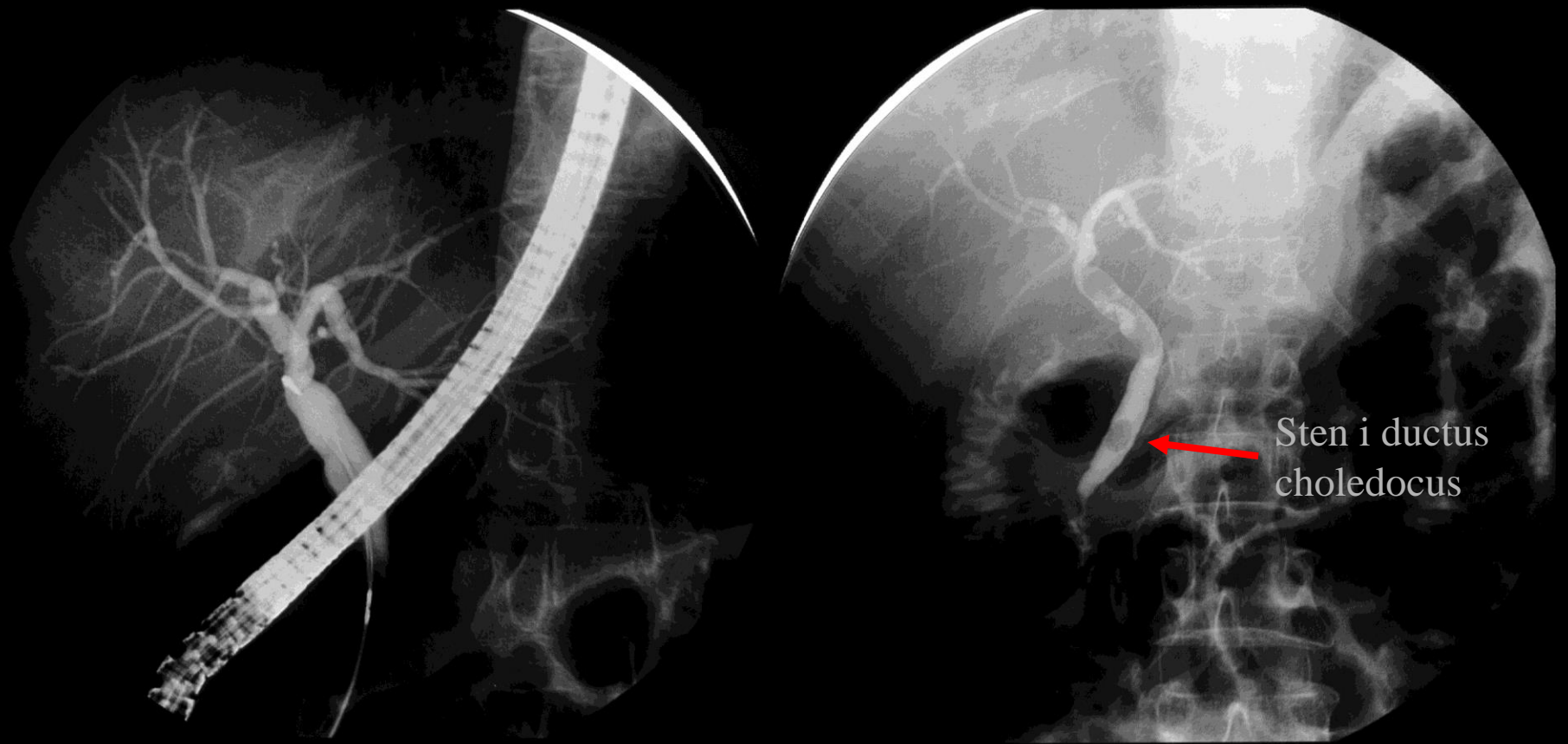


Galdevejene

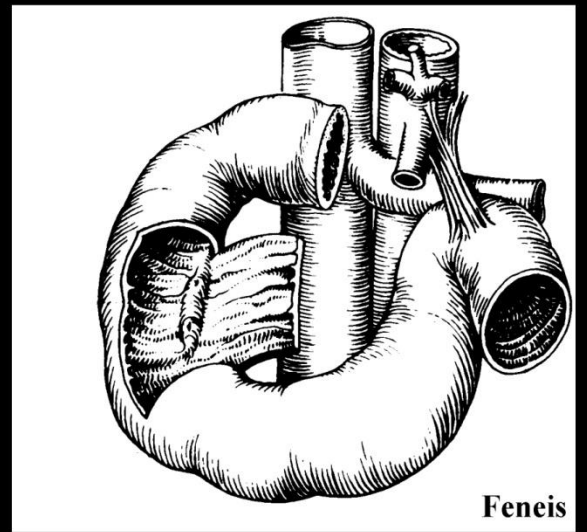
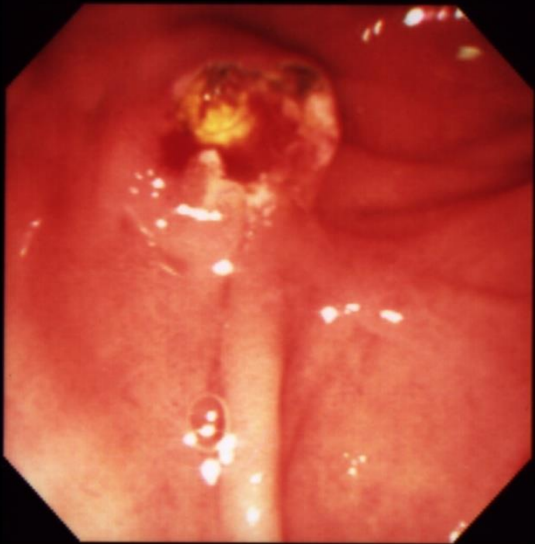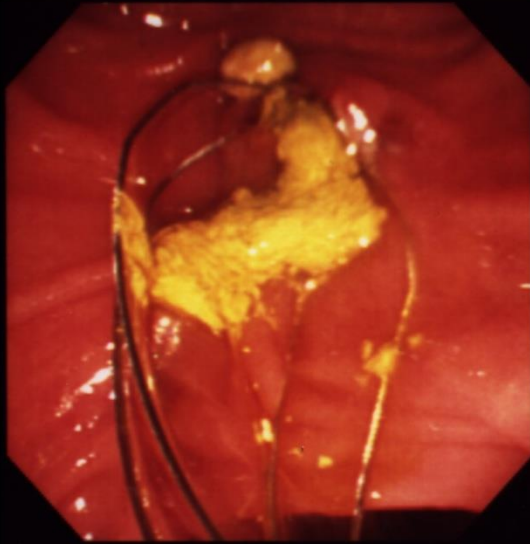
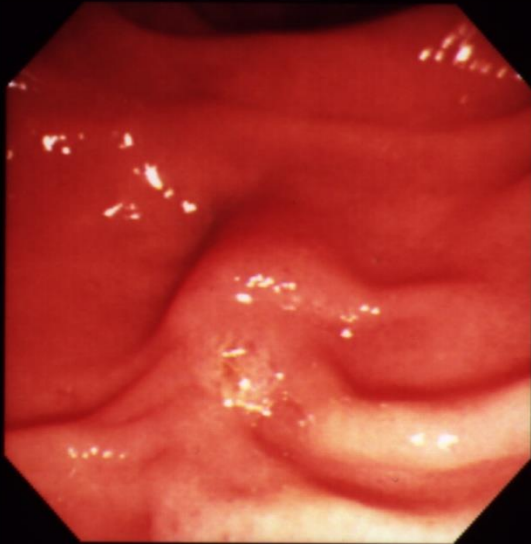
52 årig kvinde, smerter under højre  
ribbenskurvatur, affarvet afføring, mørkfarvet  
urin.



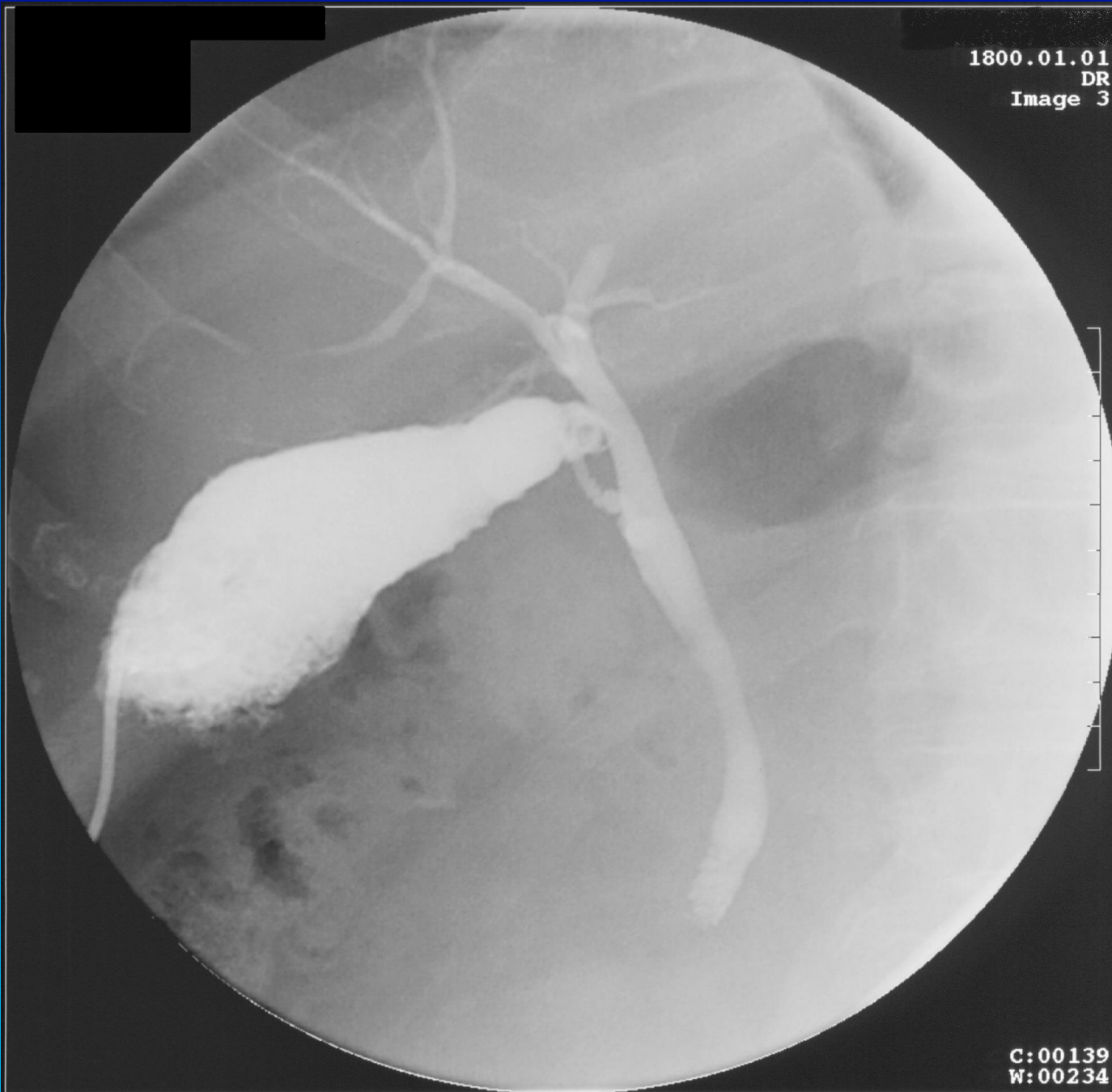**ERCP: Endoskopisk retrograd cholecysto-pancreaticografi**



**ERCP: Endoskopisk retrograd cholecysto-pancreaticografi**



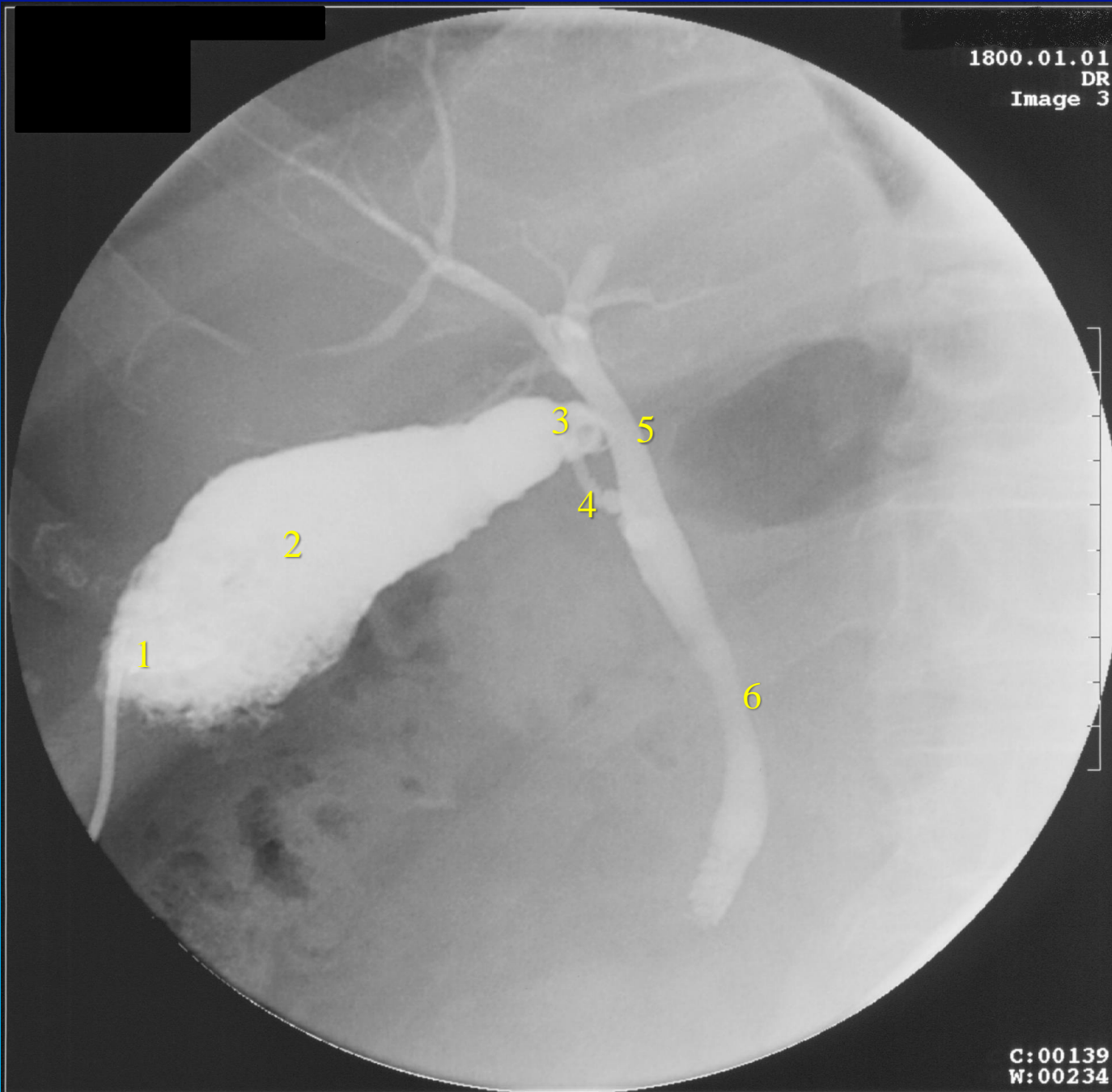
Feneis



## Vesica fellea/biliaris:

- 1) Fundus
- 2) Corpus
- 3) Collum
- 4) Ductus cysticus
- 5) Ductus hepaticus communis
- 6) Ductus choledocus



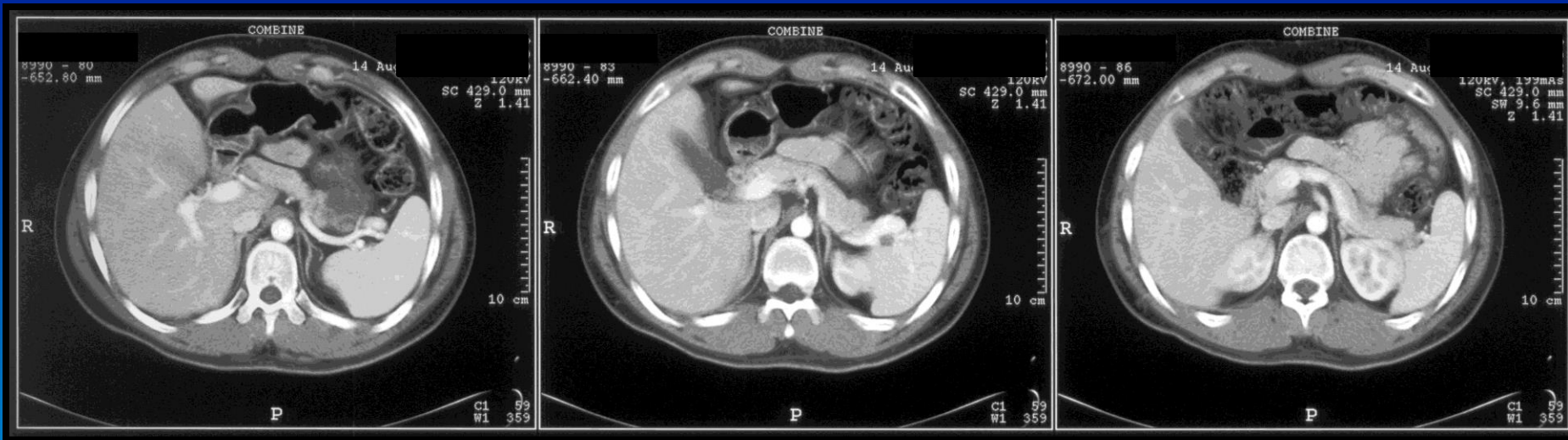


Vesica fellea/biliaris:

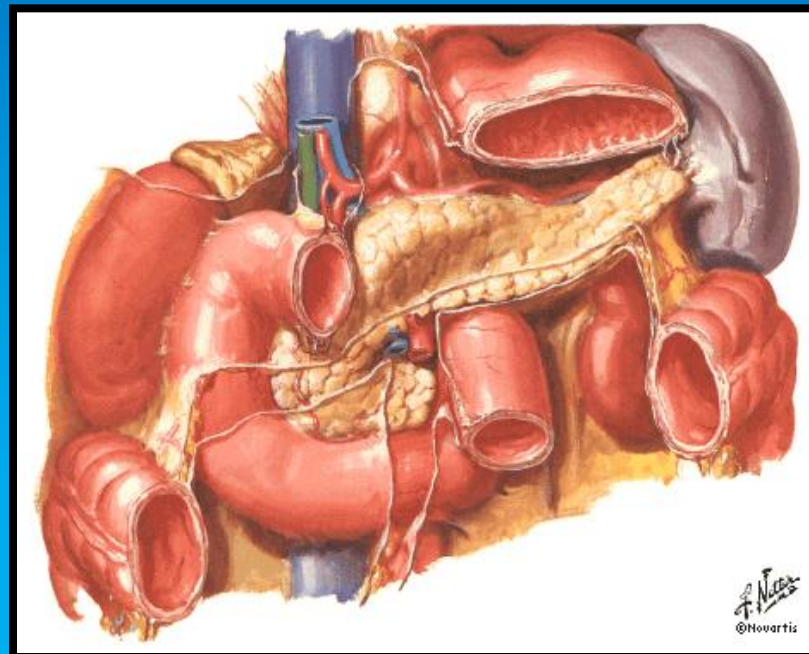
- 1) Fundus
- 2) Corpus
- 3) Collum
- 4) Ductus cysticus
- 5) Ductus hepaticus communis
- 6) Ductus choledocus

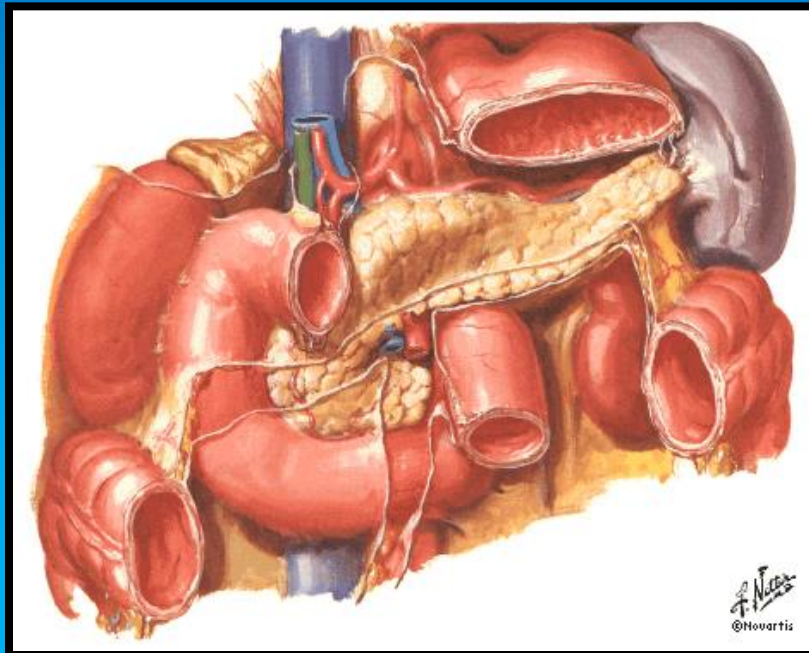
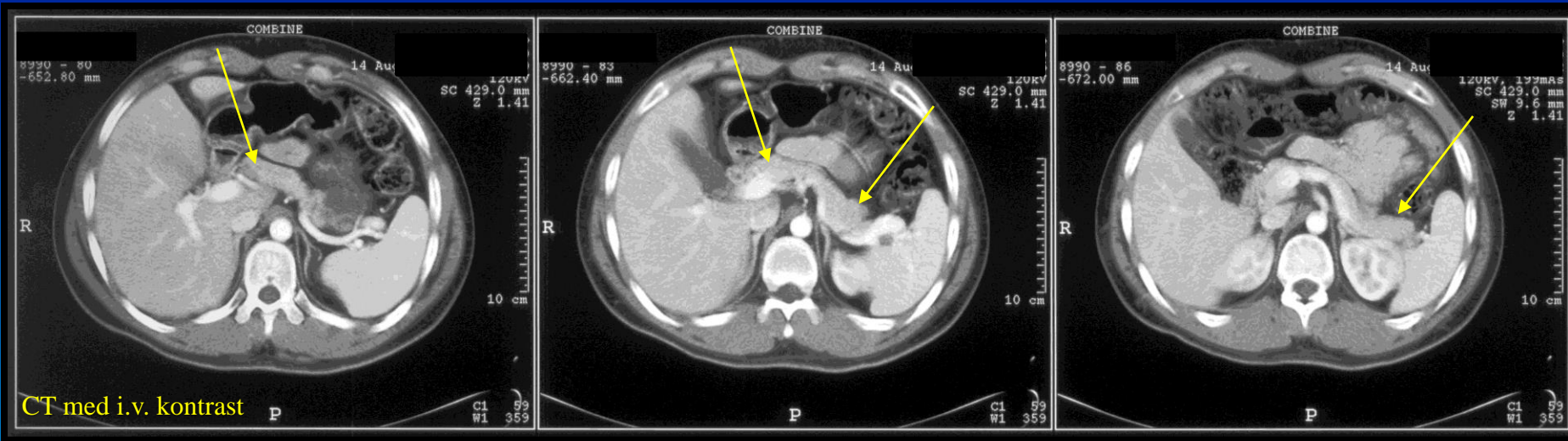
Cholecystografi via et kateter i fundus

# Pancreas

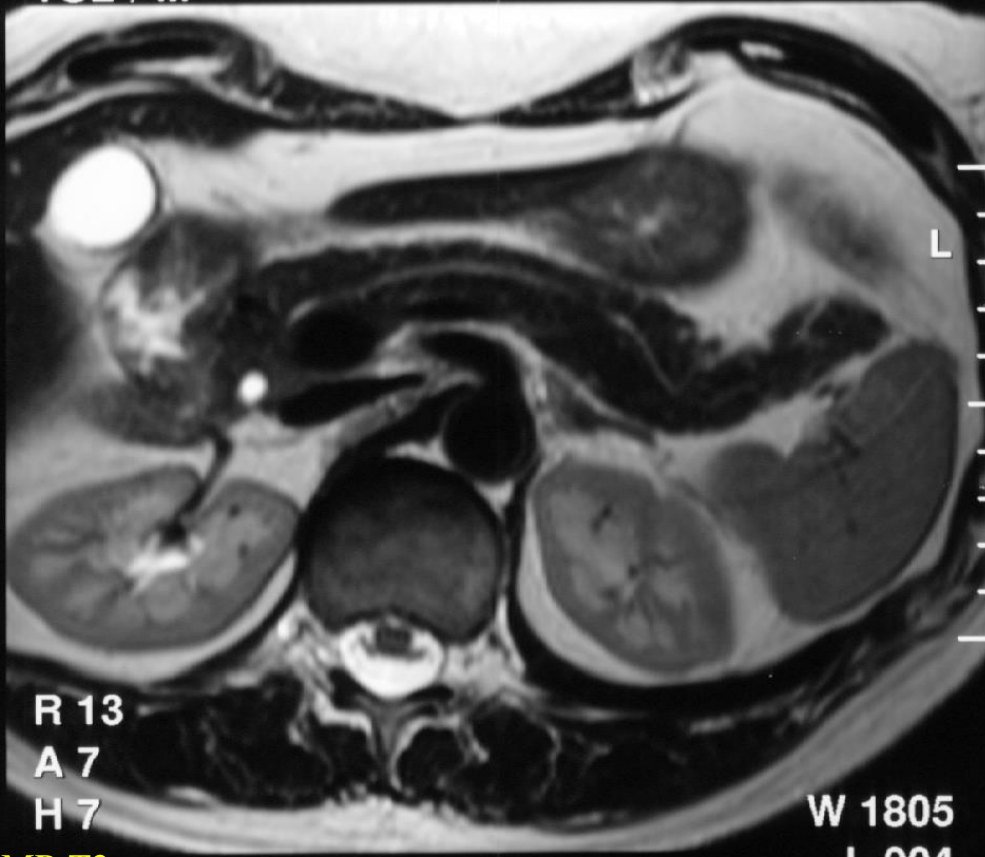

CT med i.v. kontrast

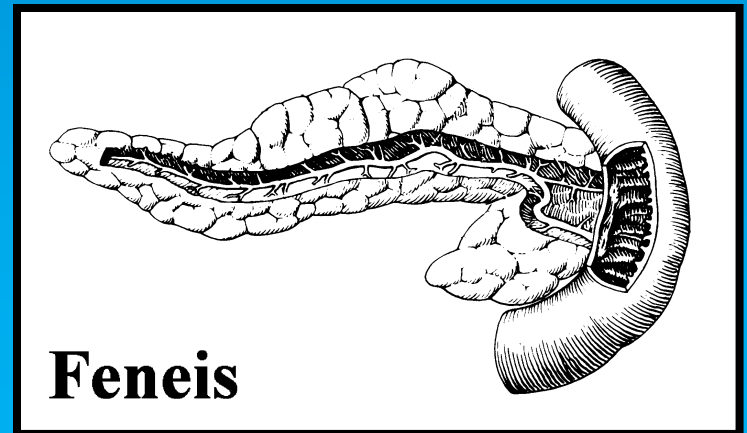
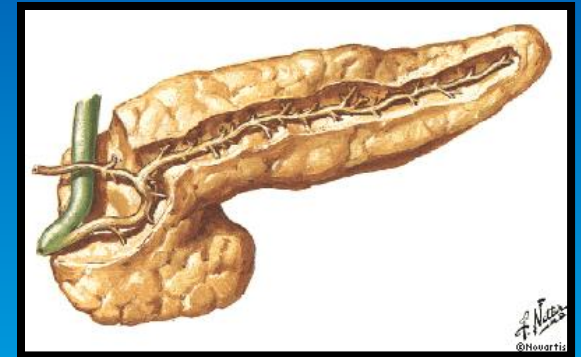




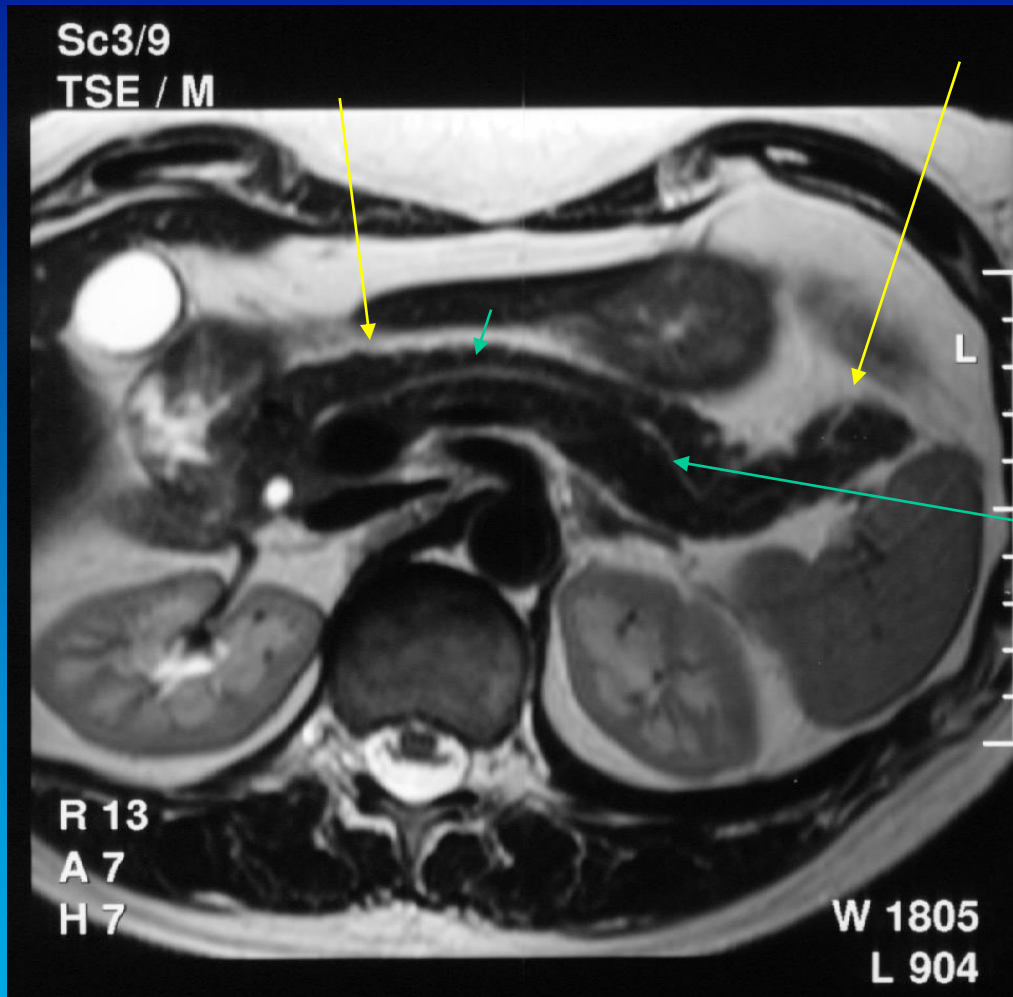
Sc3/9  
TSE / M



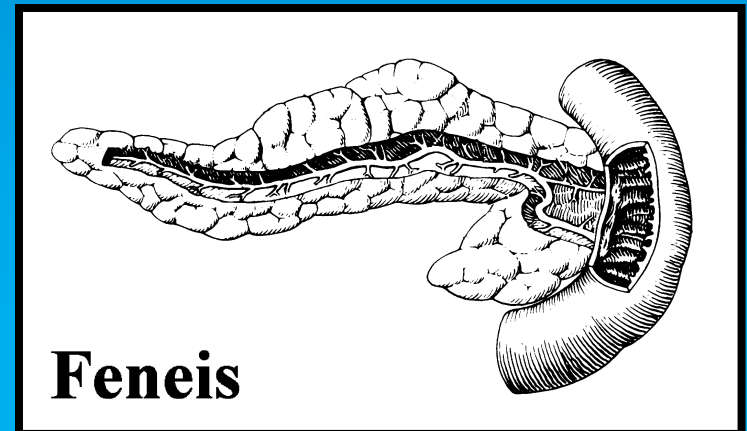
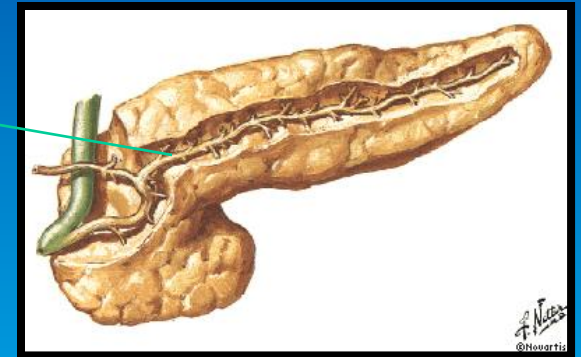
MR T2



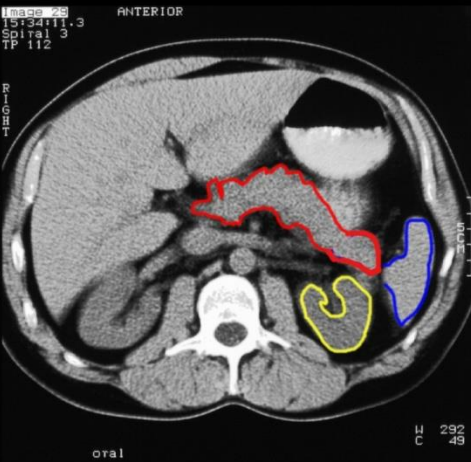
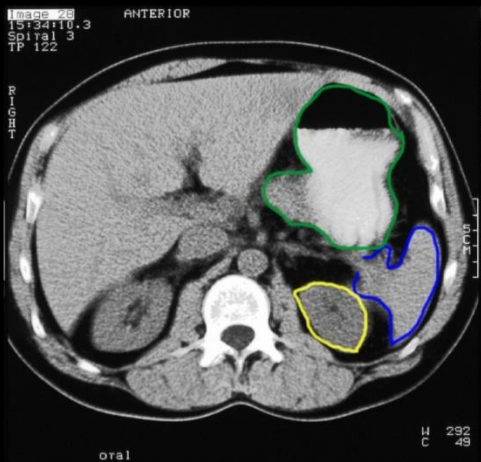
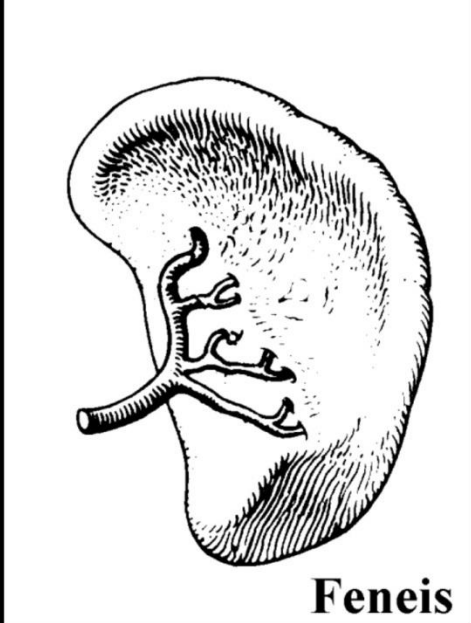
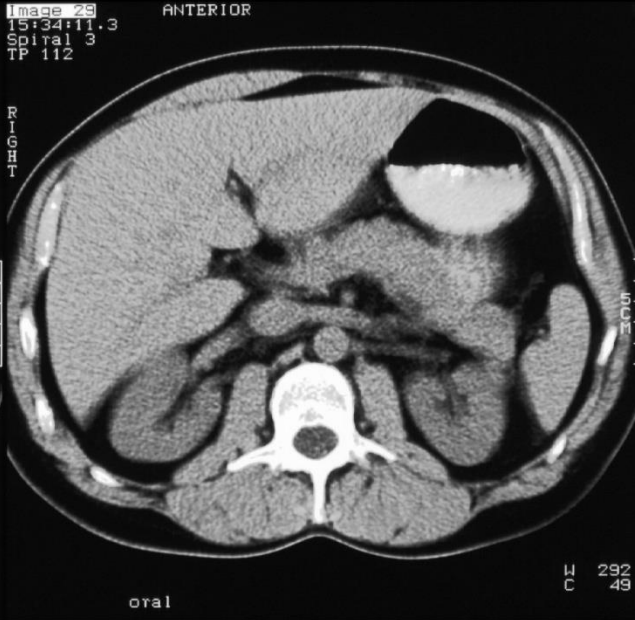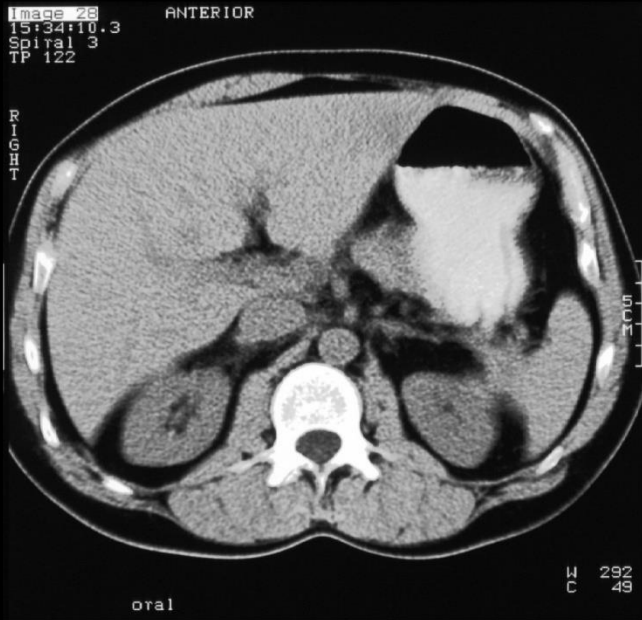**Feneis**



MR of abdomen, T2



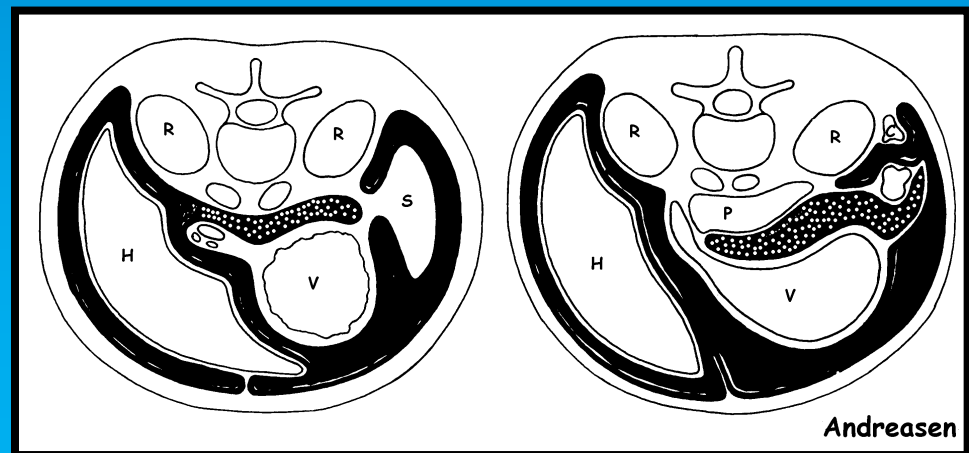
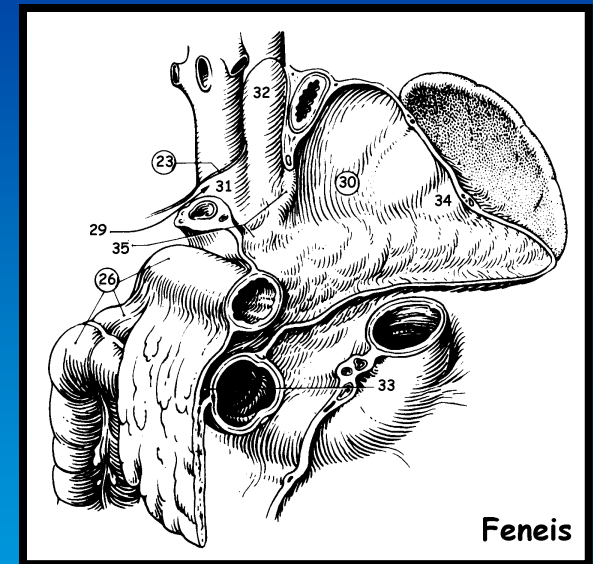
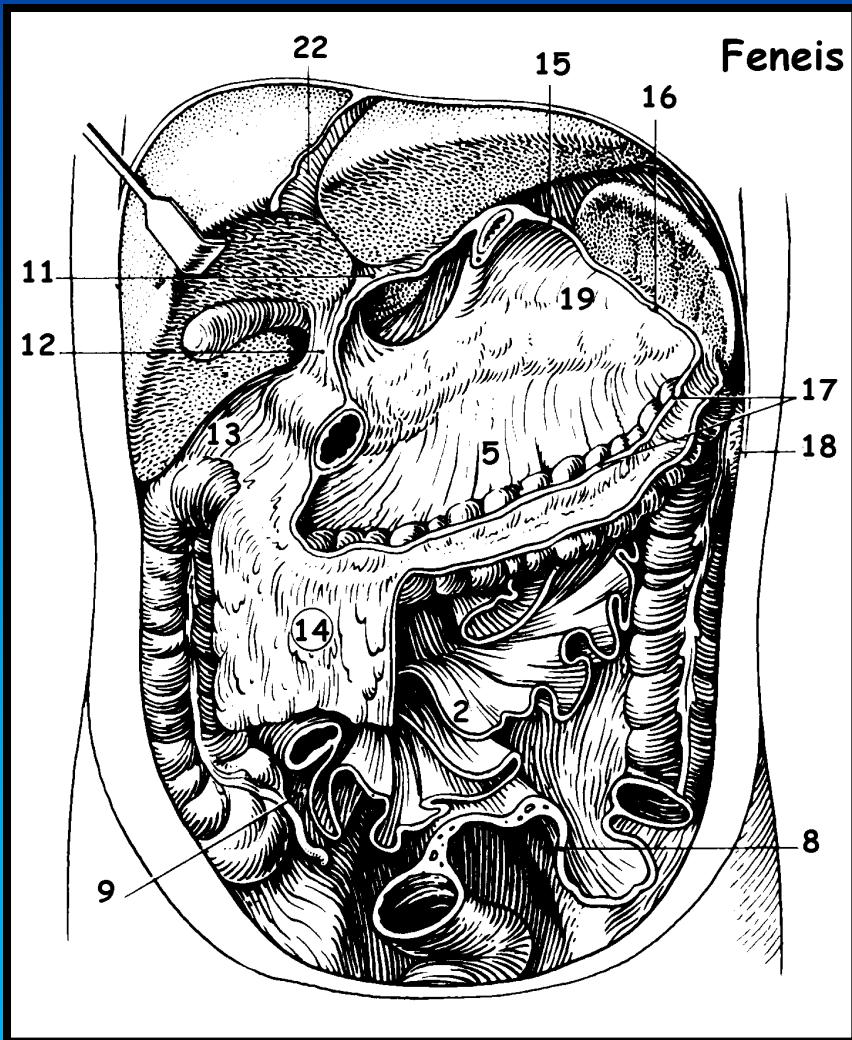
Milten

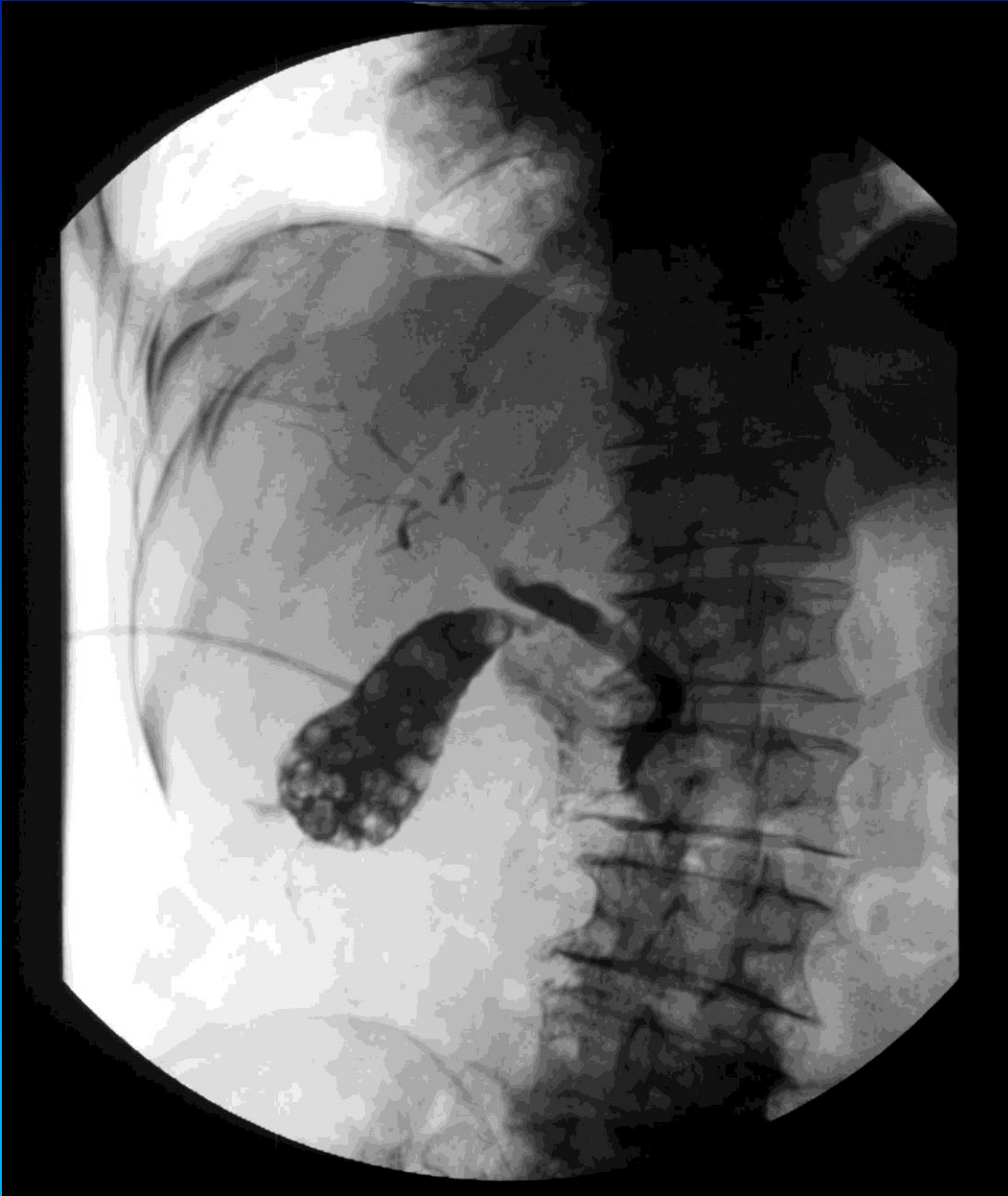



# Peritoneum

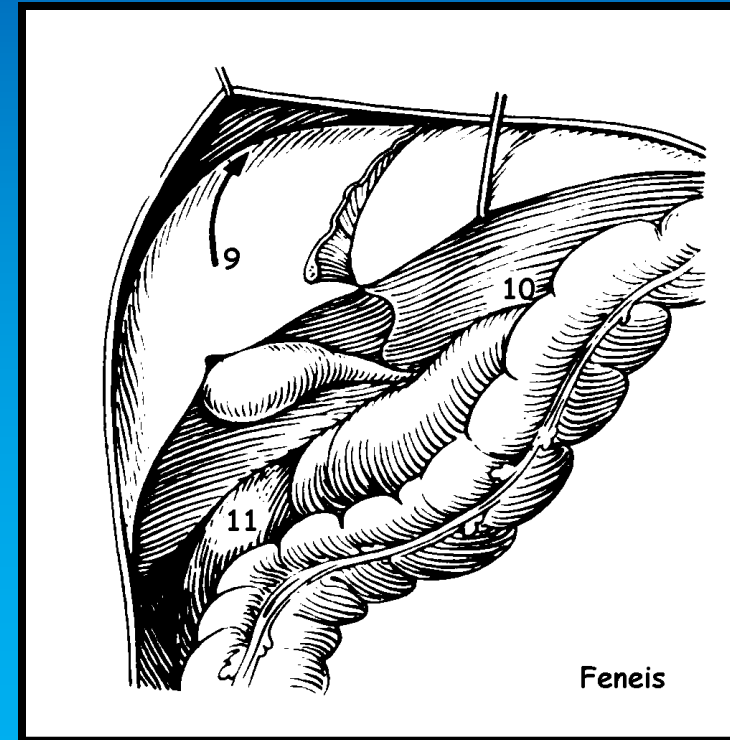
# Peritoneum skematisk

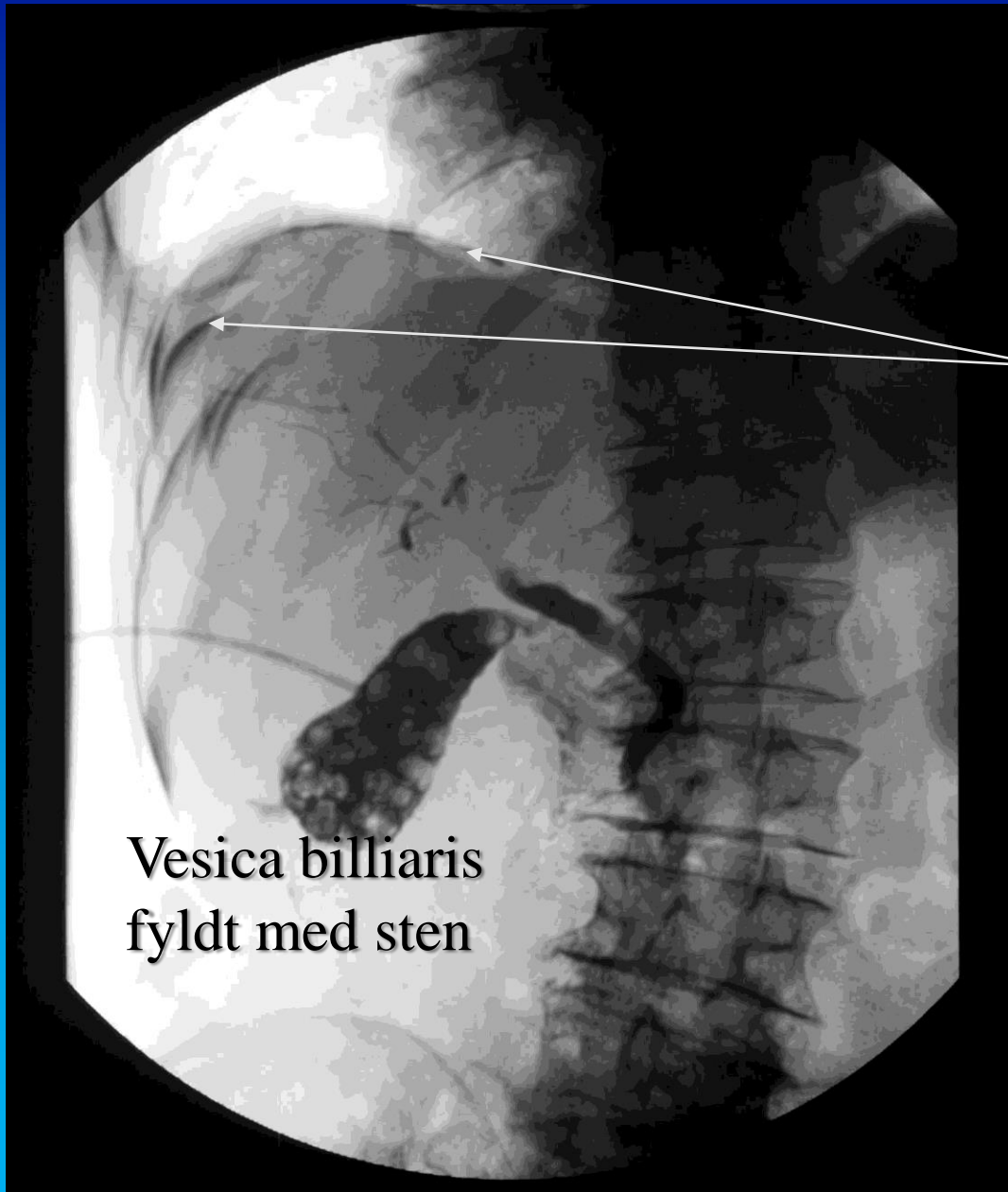




76 årig mand med cholecystit, drænbehandlet.  
Kontrolcholangiografi.

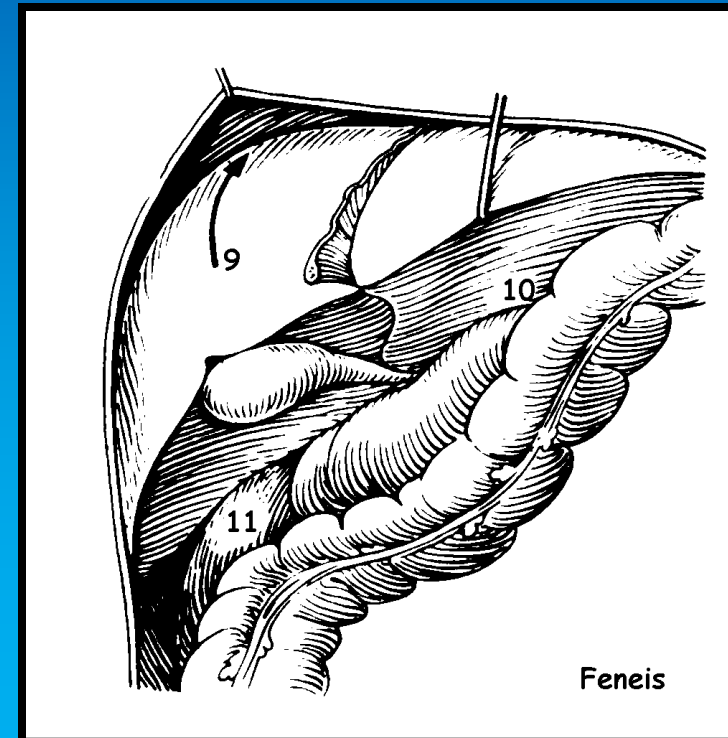
Kontrast i recessus  
subphrenicus





76 årig mand med cholecystitis, drænbehandlet.  
Kontrolcholangiografi.

Kontrast i recessus  
subphrenicus



# Recessus subhepaticus (Morison's poche)

