

Ultralydskanning af bevægeapparatet


Michel Bach Hellfritsch

Strukturer

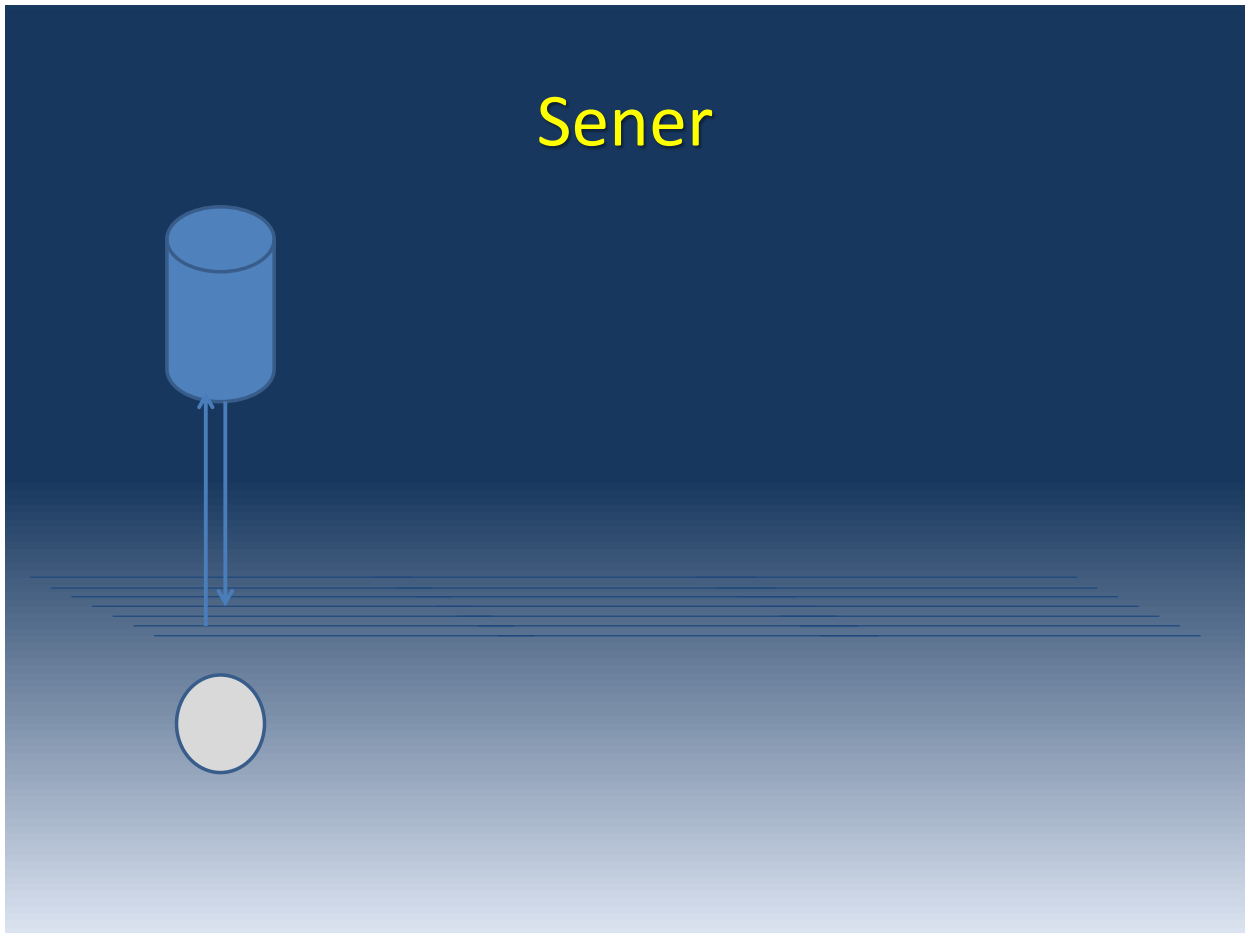
- Sener
- Knogler
- Led
- Muskler
- Kar
- Nerver
- Hud & subcutis

Generelle principper

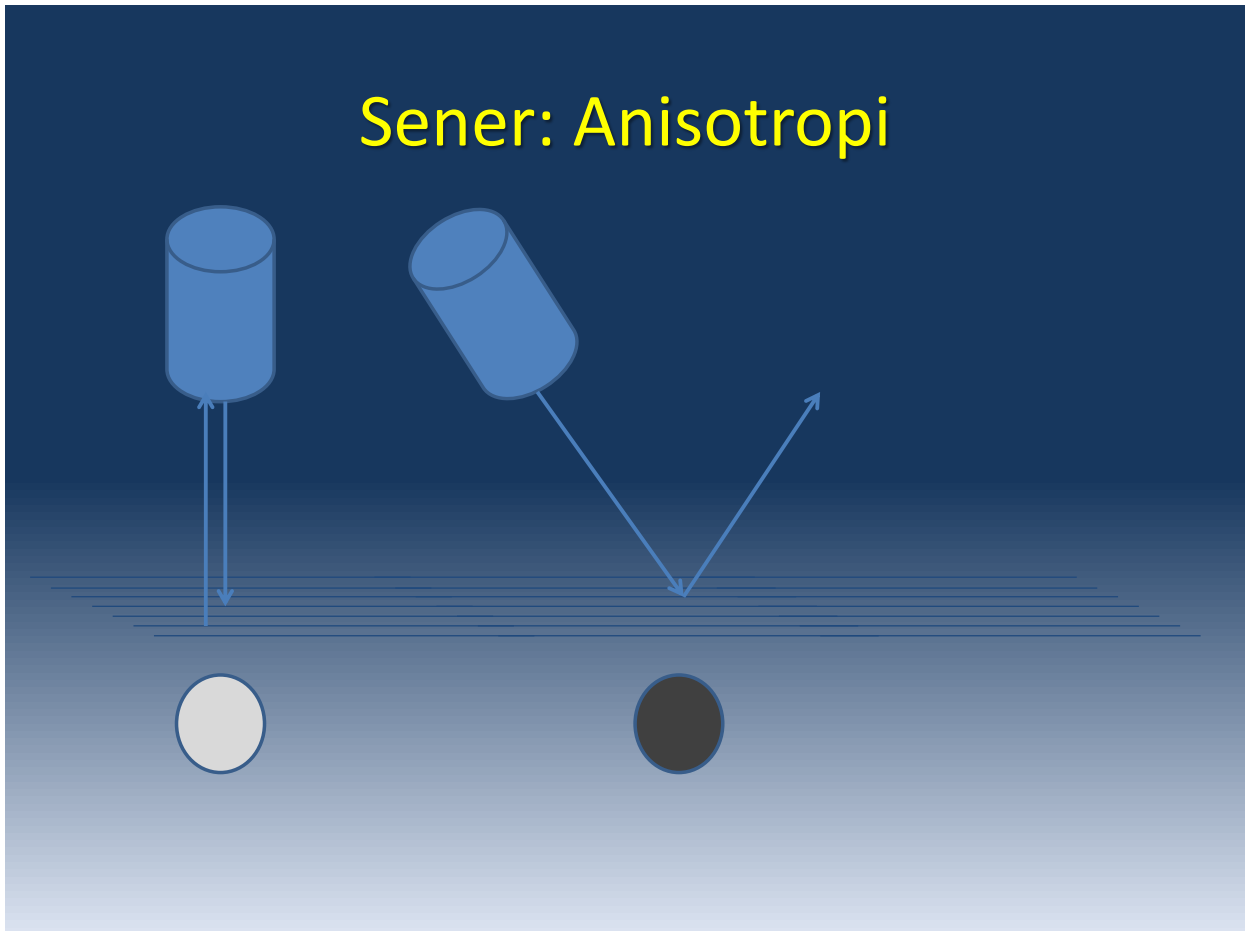
- Ekkorig/hyperekkkoisk
- Ekkofattig/hypoekkoisk
- Ekkotom/aneekkoisk



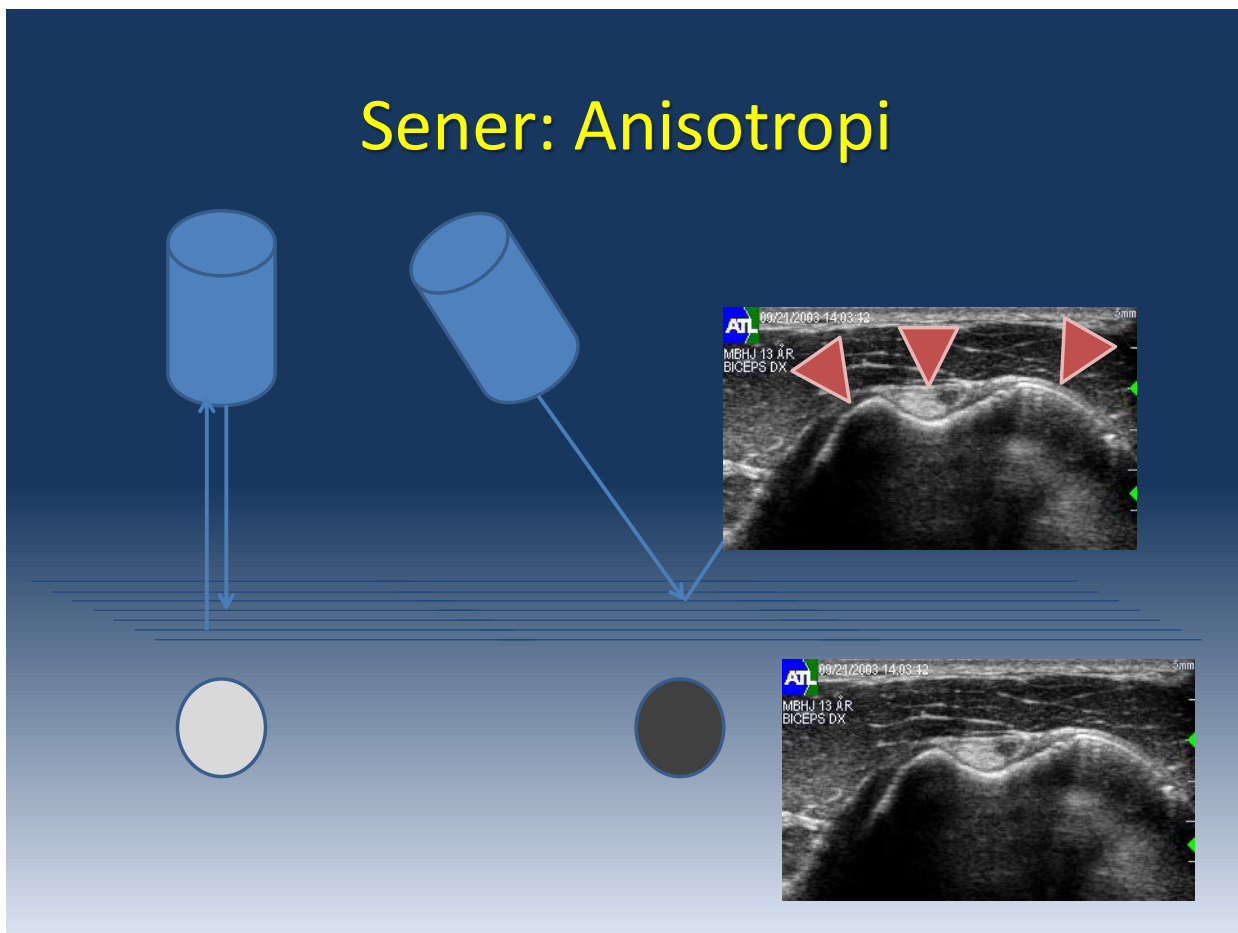
Sener



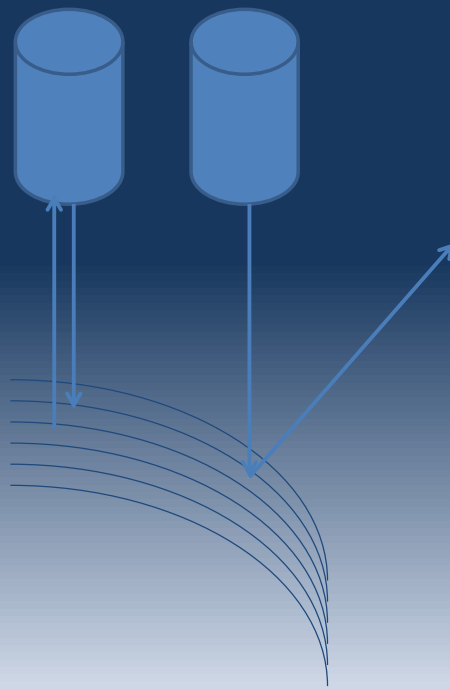
Sener: Anisotropi



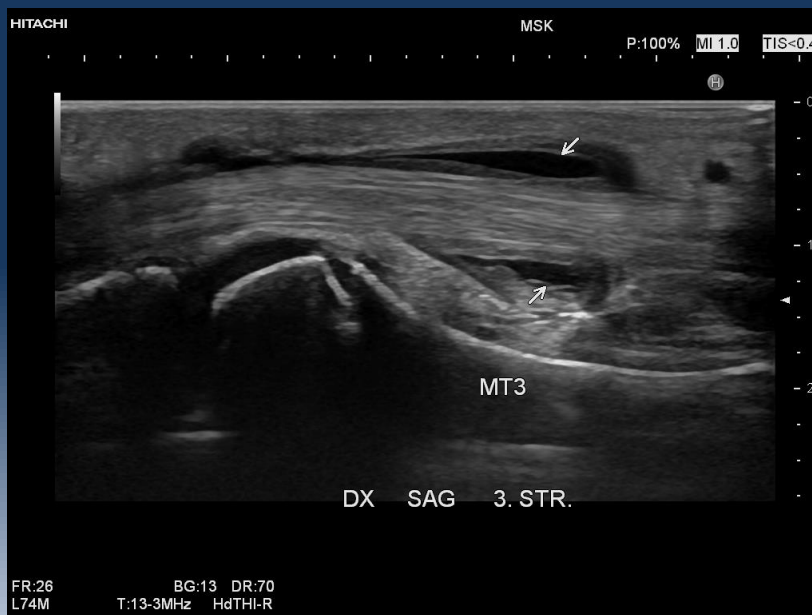Sener: Anisotropi



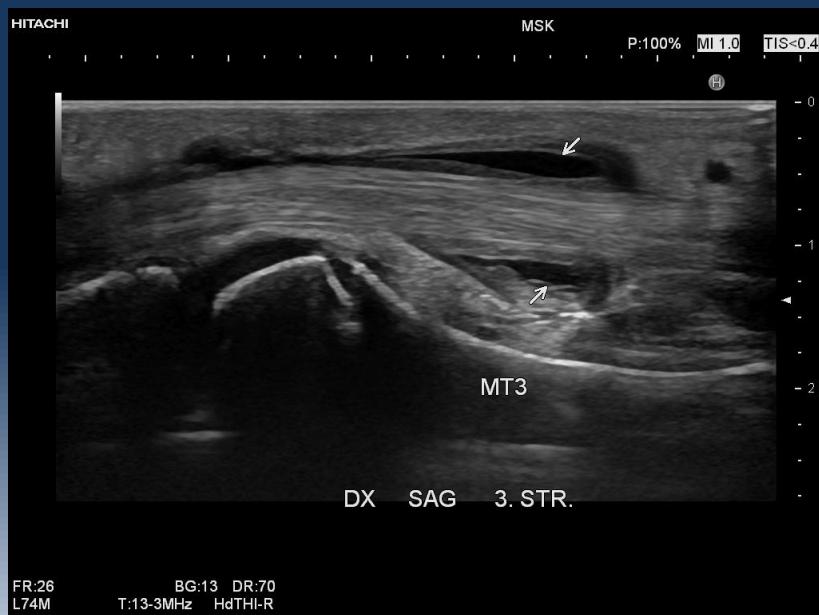Sener: Anisotropi



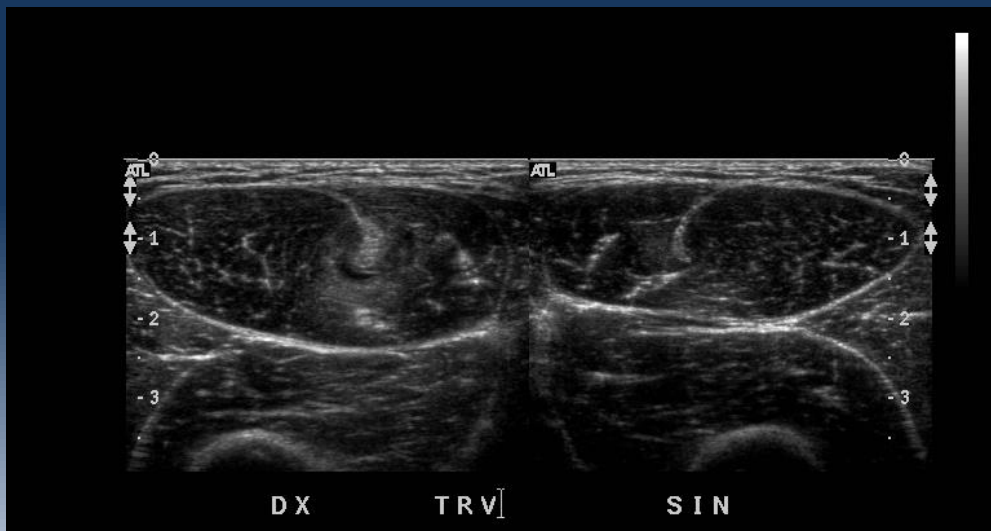
Sener: Flexorsene på hånden



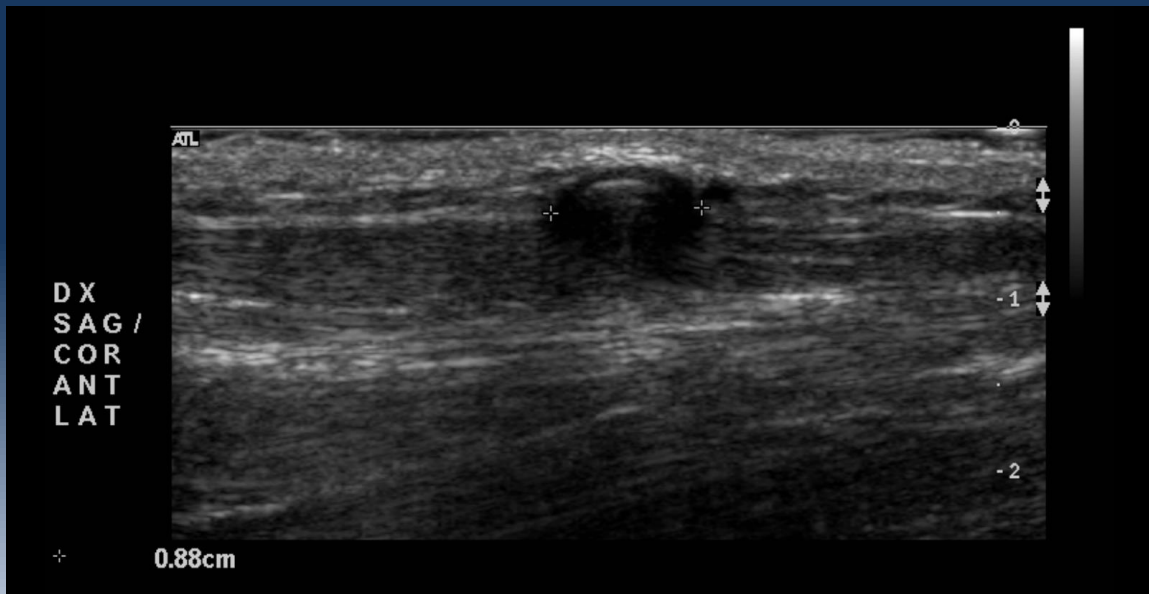
Knogler og led



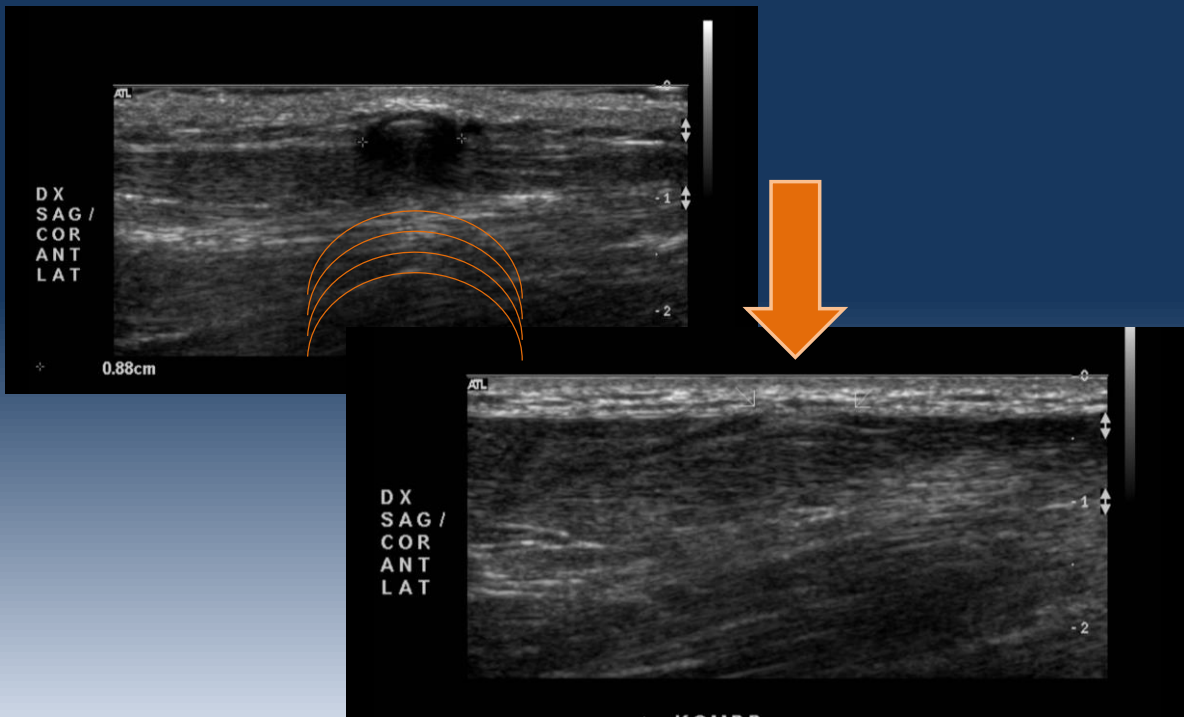
Muskler



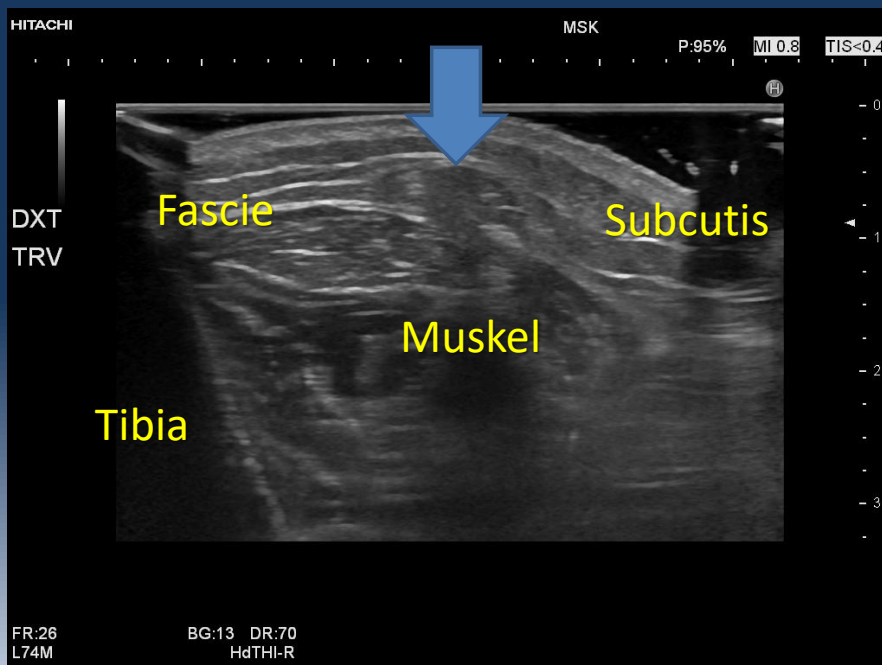
Muskler



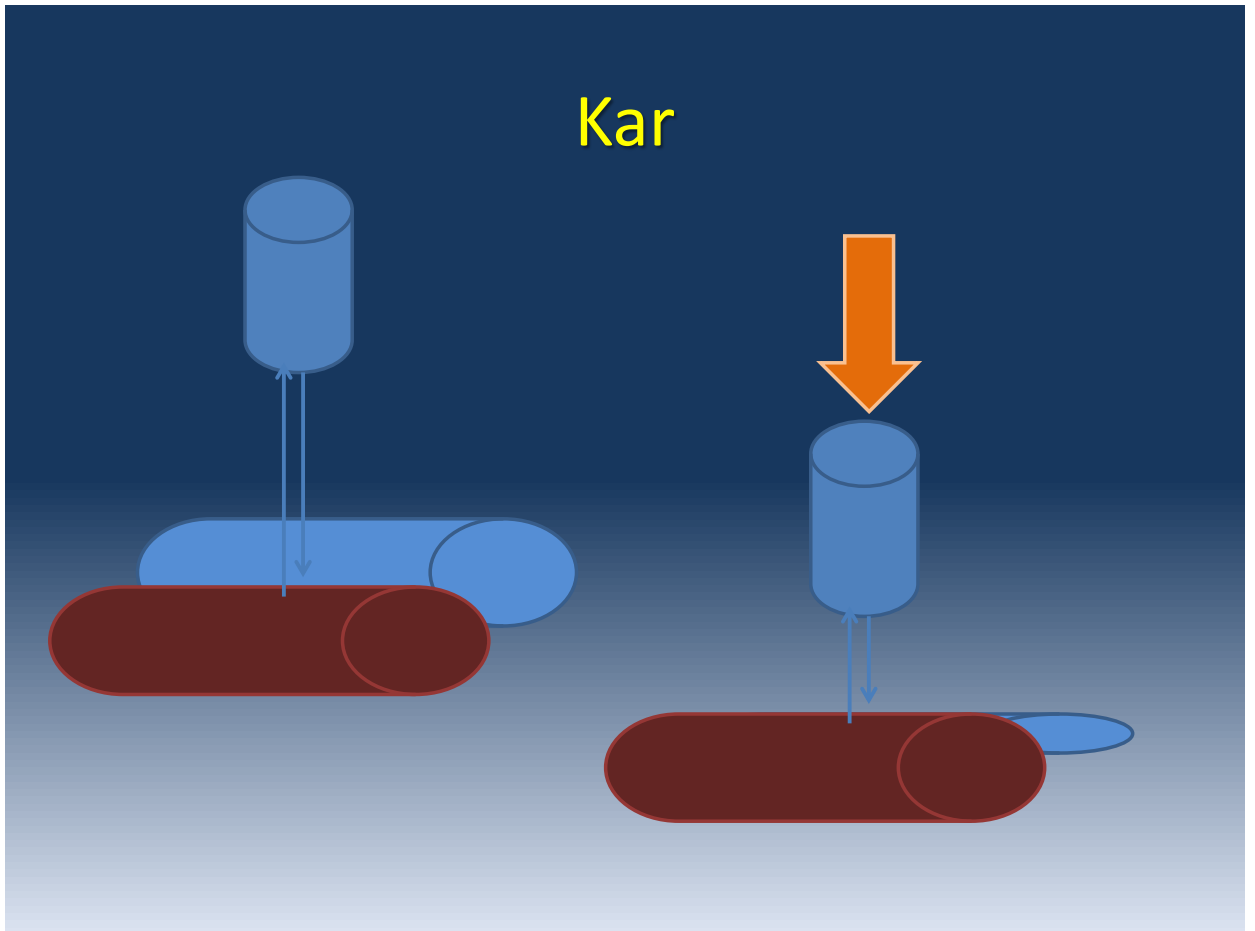
Muskler: Hernie



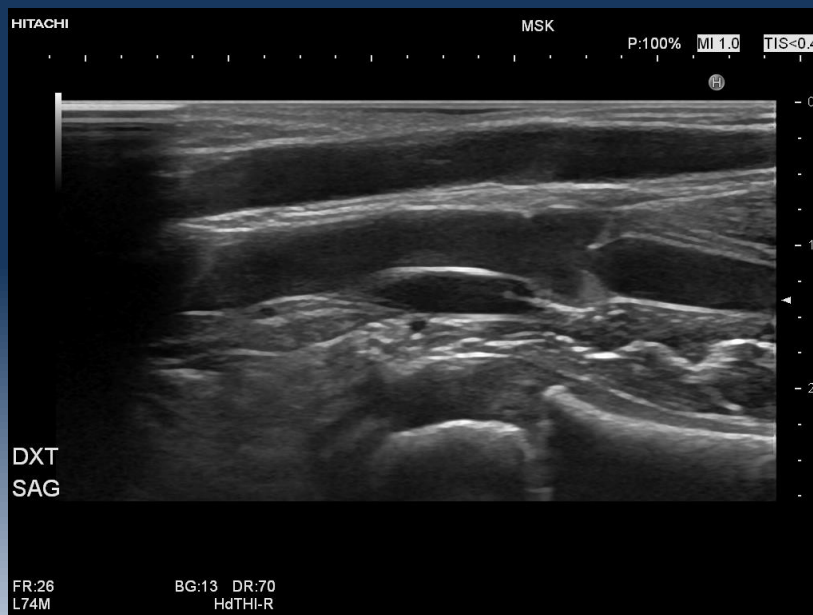
Muskler: Hernie



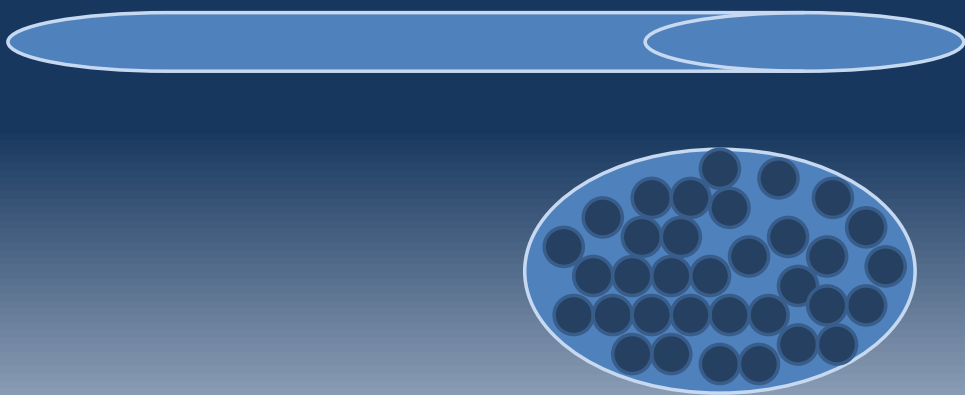
Kar



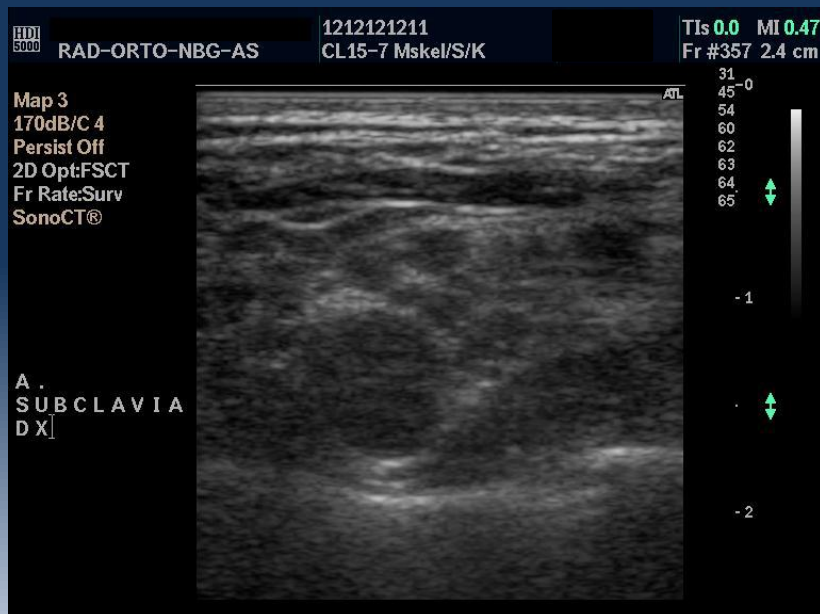
Kar: Veneklapper hos mindre barn



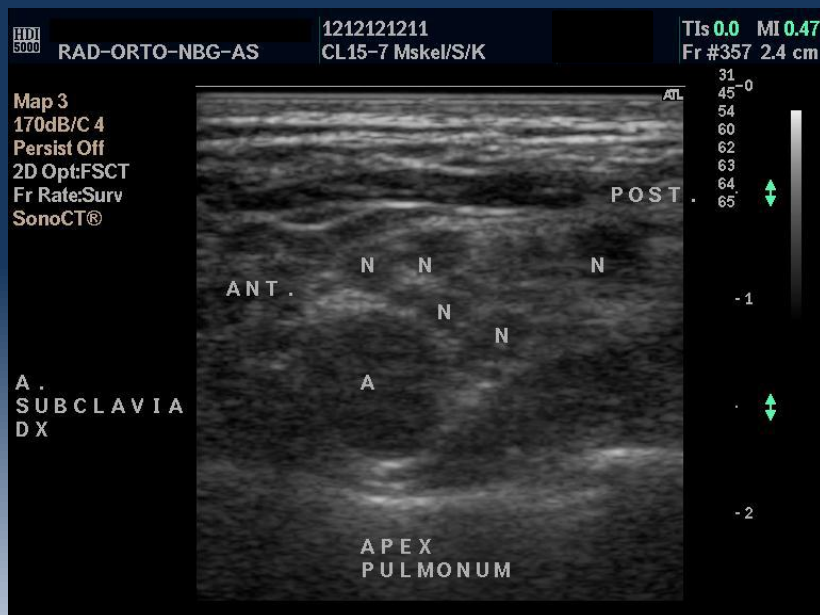
Nerver



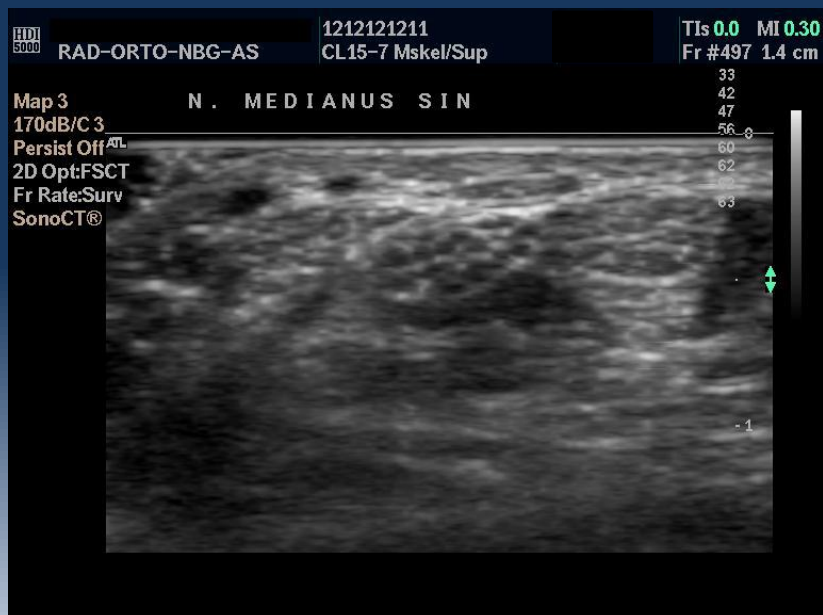
Plexus brachialis



Plexus brachialis



Nerver: Mere perifert



Nerver

