Truncus

Michel Bach Hellfritzsch

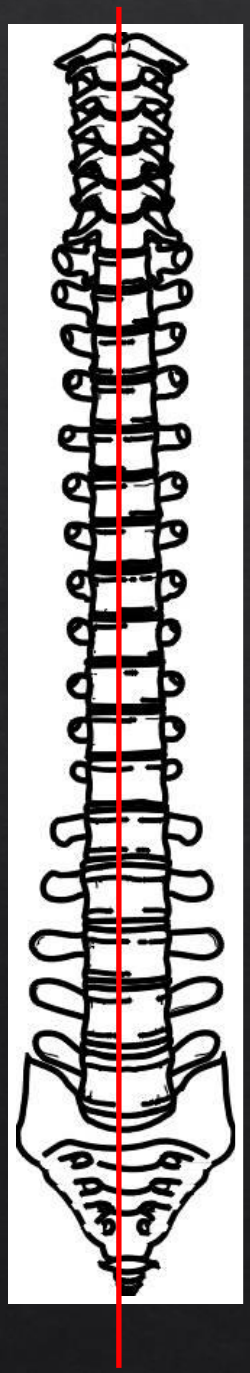

Frontalt ses ingen krumning

Thorakal kyfose

(Primær)

Sakral kyfose

(Primær)

Cervikal lordose

(Sekundær)

Lænde lordose

(Sekundær)

Oversigt over abdomen, kvinde 32 år med gemelli

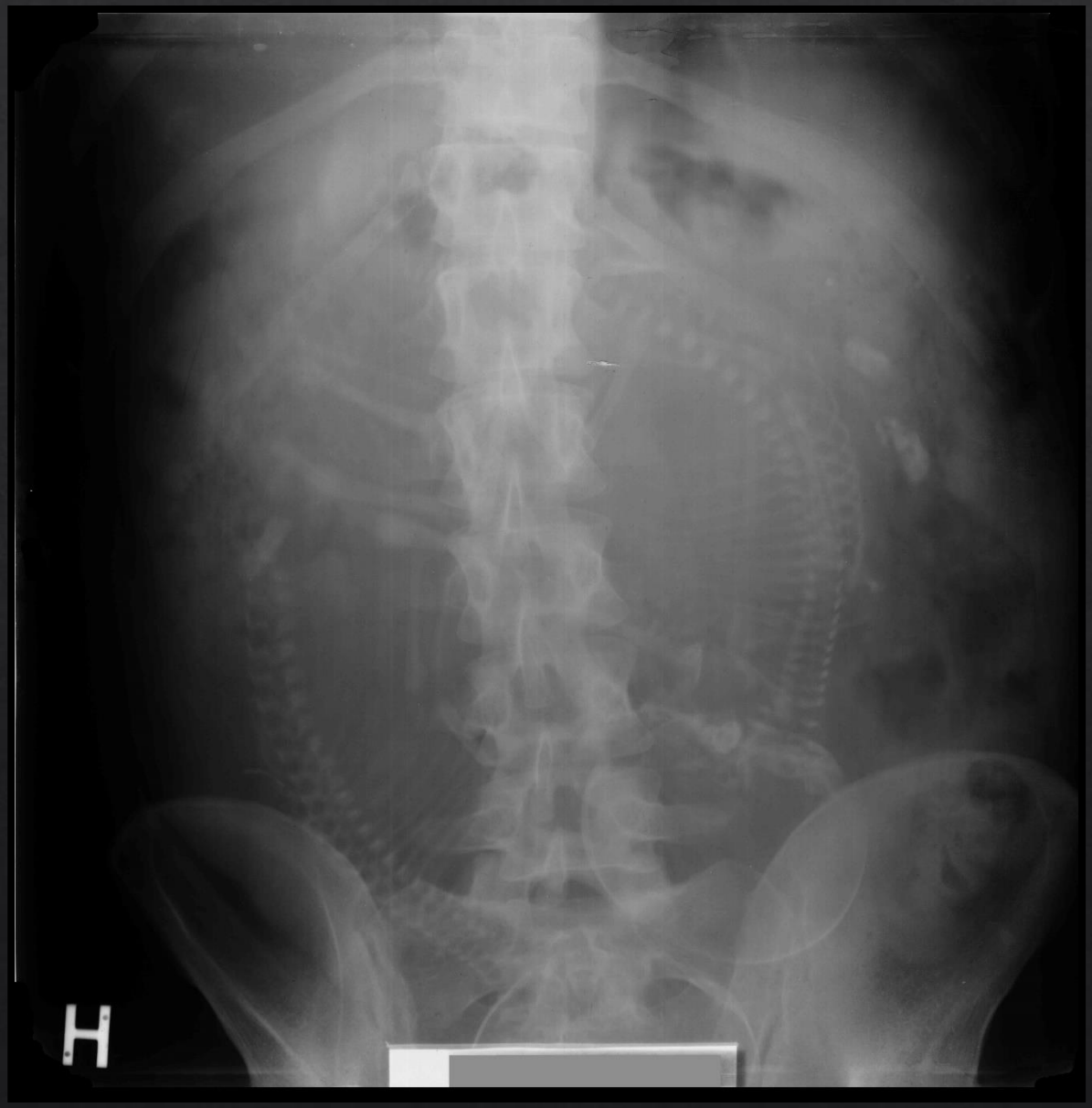

Kyfoser:
Primære

Oversigt over abdomen, kvinde 32 år med gemelli

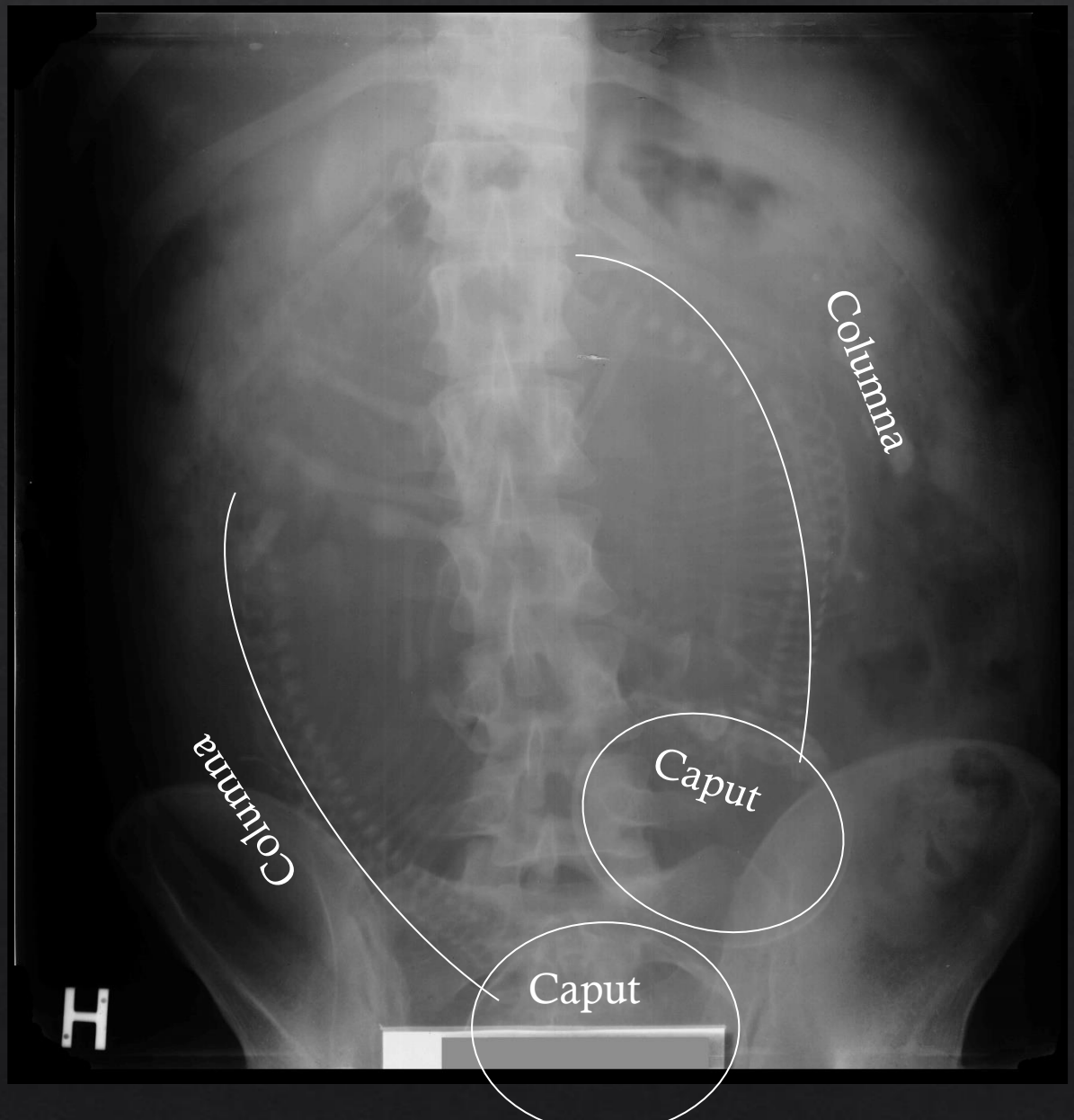

Kyfoserne er primære, idet fosteret i livmoderen ligger rullet sammen, således columna udgør en lang kyfose.
På billedet til venstre ses tvillinger (gemelli), med markering af hovedet og columna.
Knoglerne i arme og ben kan også ses.
Røntgenbilledet er fra før ultralyd var tilgængelig, denne undersøgelse udføres ikke længere hos gravide.

7 mdr. gammel pige.

6 uger: Barnet smiler

9-10 uger: Ruller fra siden til ryggen

3-4 måneder Løfter hovedet og skuldrene, når det ligger på maven

6 måneder: Sidder med støtte

9 måneder :Kan sætte sig op

9-10 måneder: Siger enkle tostavelsesord som "mor" og "far"

12 måneder: Forstår enkle kommandoer

12 måneder: Kan stå uden støtte i et sekund eller to

18 måneder: Forsøger at spise med ske

18 måneder: Går uden hjælp

18 måneder :Kan stable 3-4 klodser

2-3 år: Kan have kontrol over urin og afføring

3 år: Taler i enkle sætninger

3 år: Klæder sig af og på med lidt hjælp

5 år: Kan tegne en figur med hoved, krop, arme og ben

www.sundhed.dk

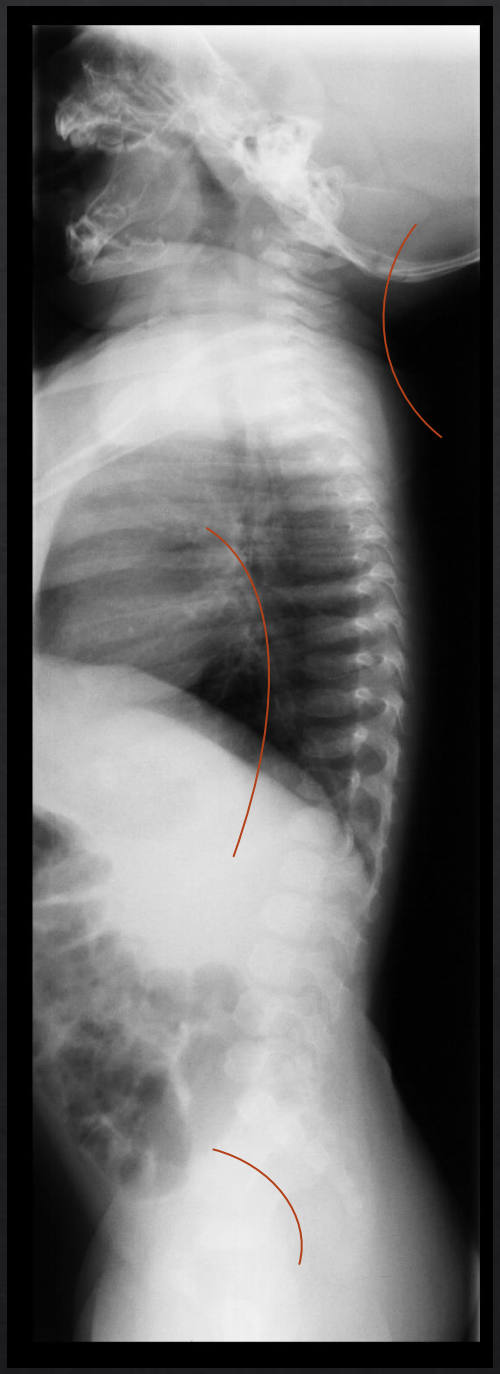

7 mdr. gammel pige.

Her ses cervical lordose.
Der er vinkling mellem
columna lumbalis og
os sacrum, men fortsat
langstrakt torakolumbal kyfose.

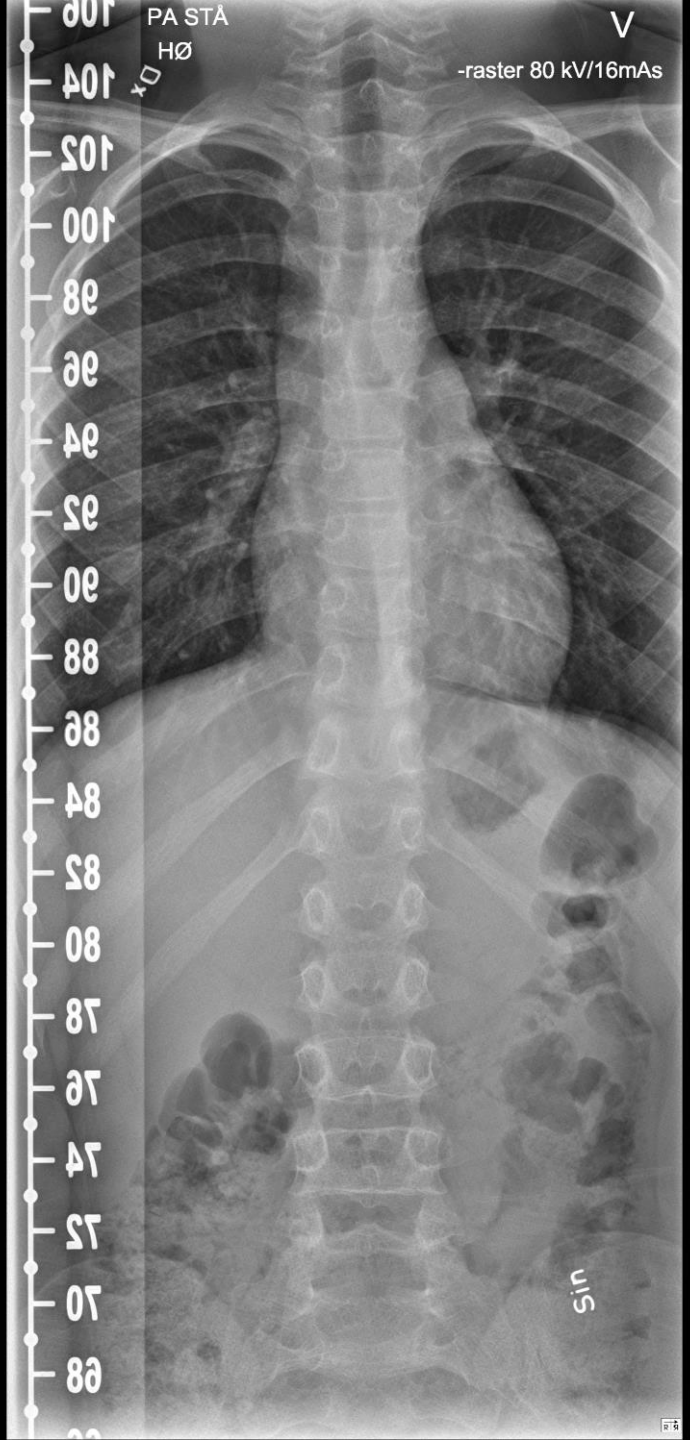
PA STÅ
HØ
V
-raster 80 kV/16mAs
sin


Stå
VE
-raster 85kV/20mAs

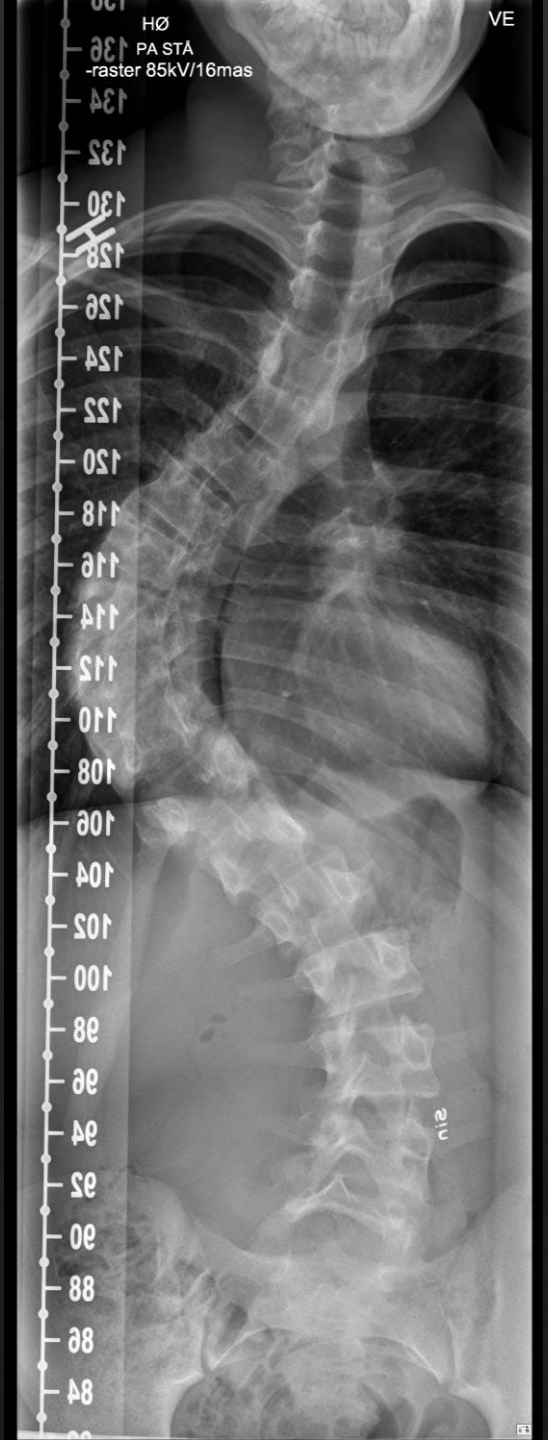
VE
HØ
PA STÅ
-raster 85kV/16mas
sin

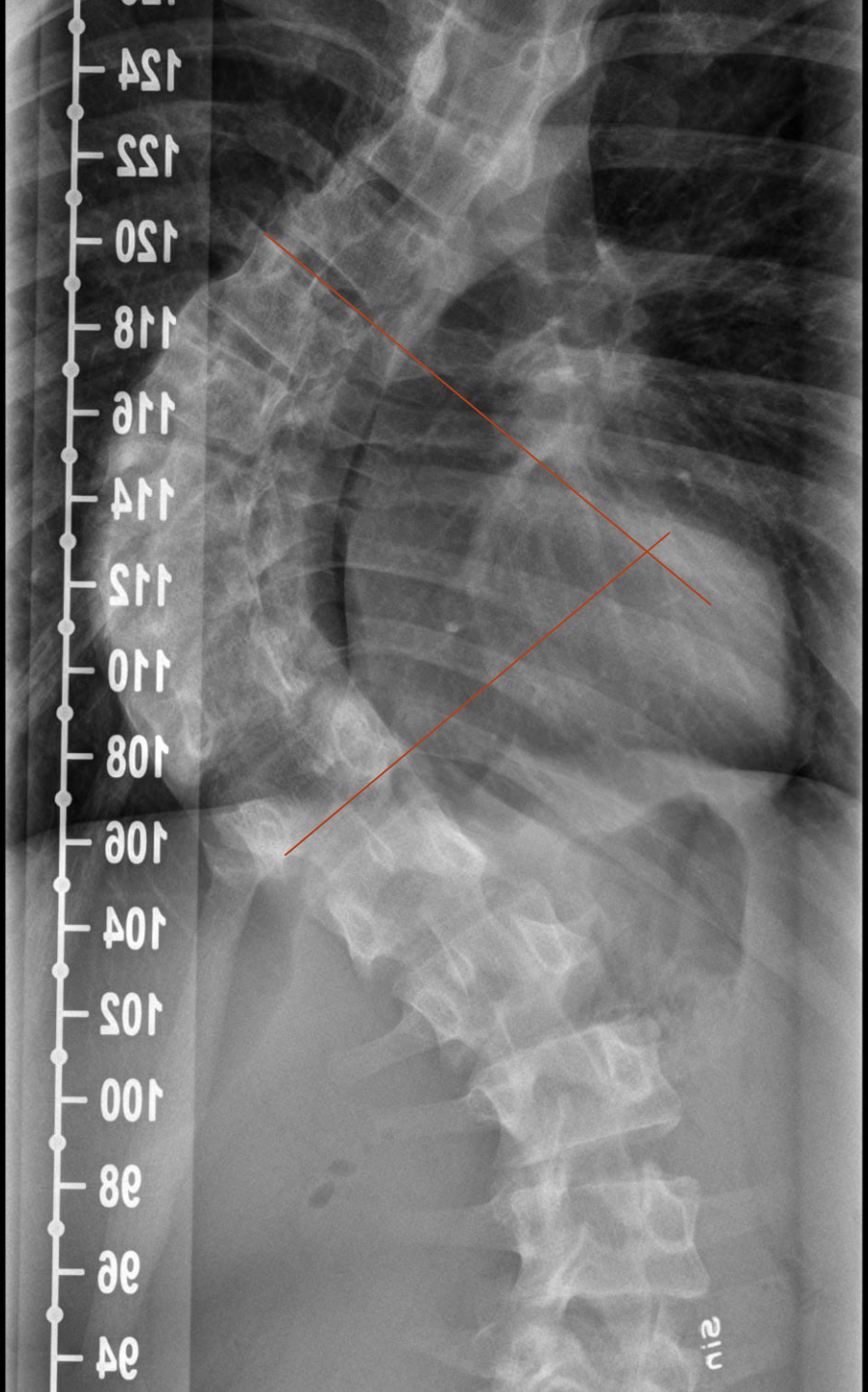
sin

Columna vertebralis

Udvikling

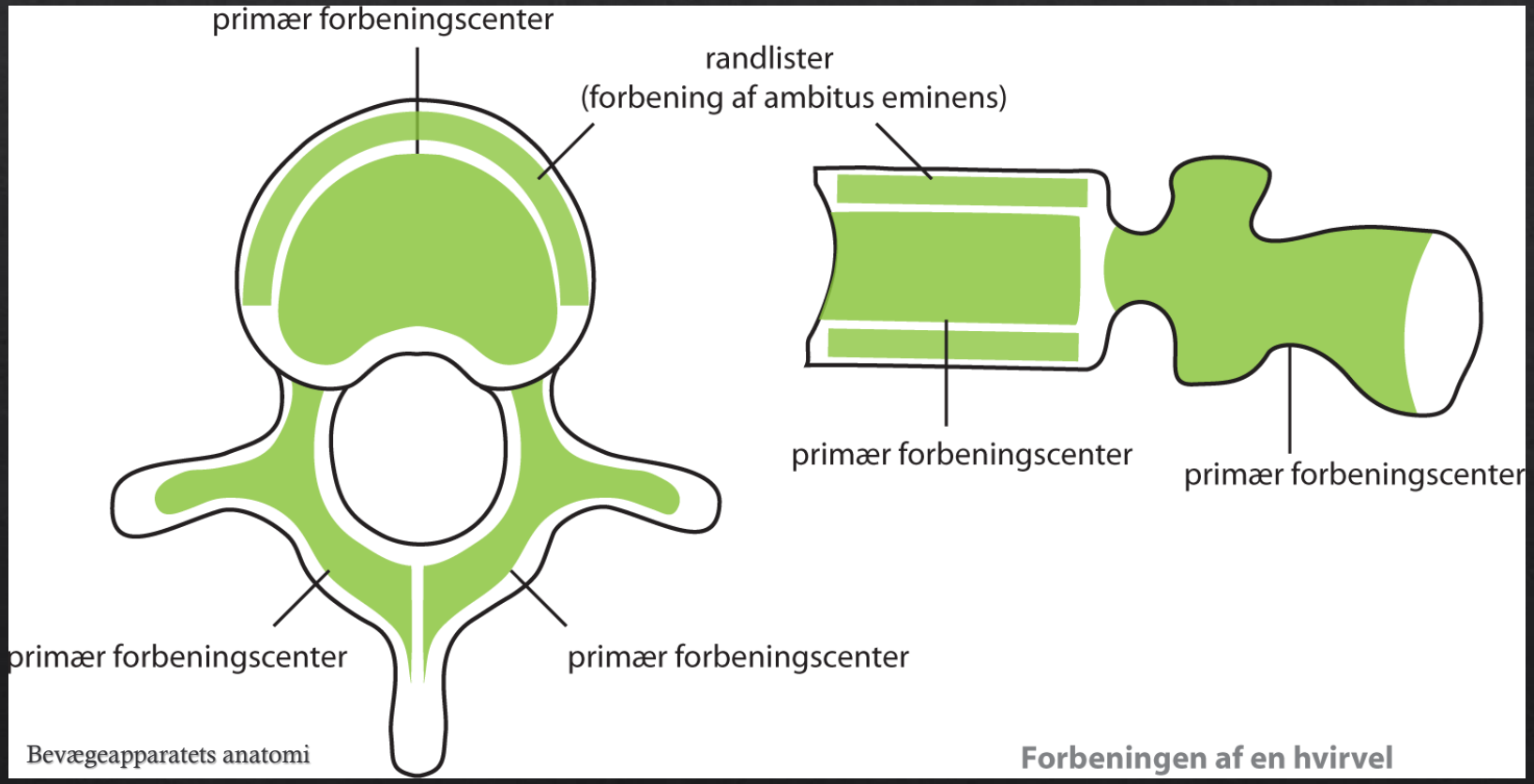
primær forbeningscenter
randlister
(forbening af ambitus eminens)
primær forbeningscenter
primær forbeningscenter
primær forbeningscenter
primær forbeningscenter
Bevægeapparatets anatomi
Forbeningen af en hvirvel

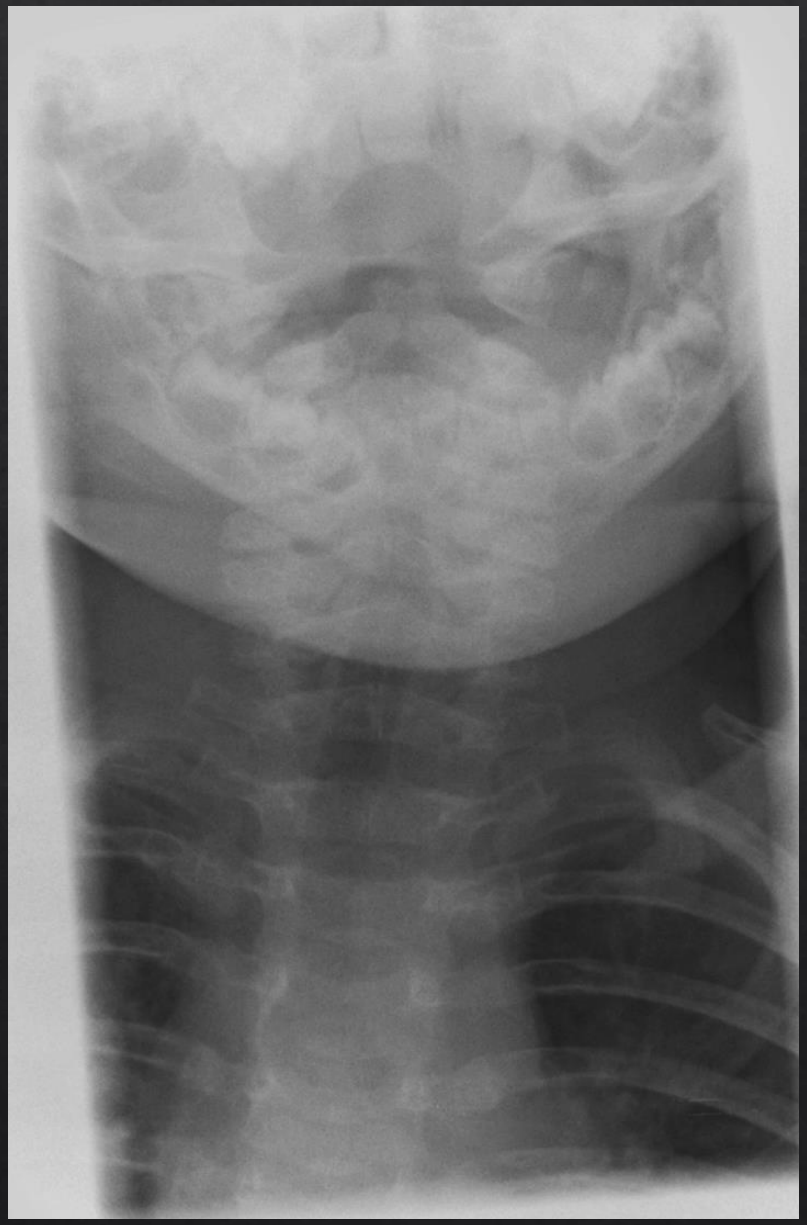


6 mdr. gammel pige.

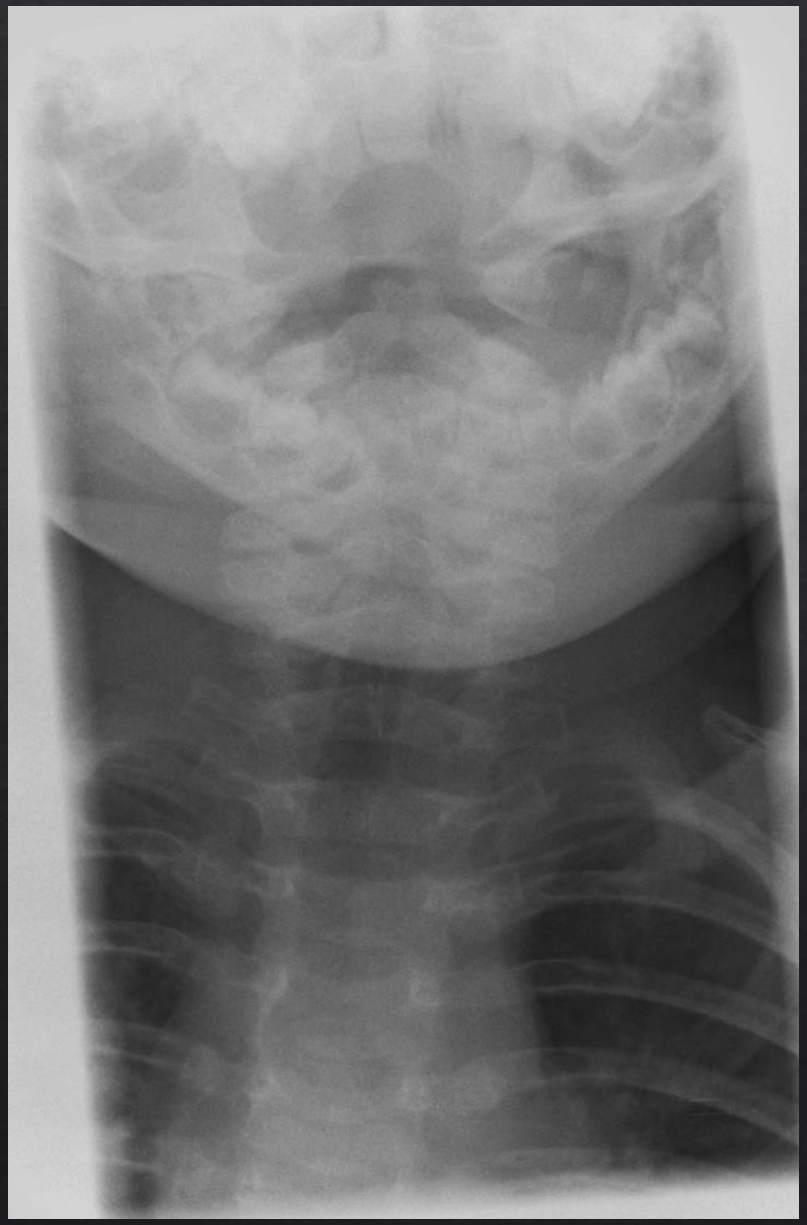

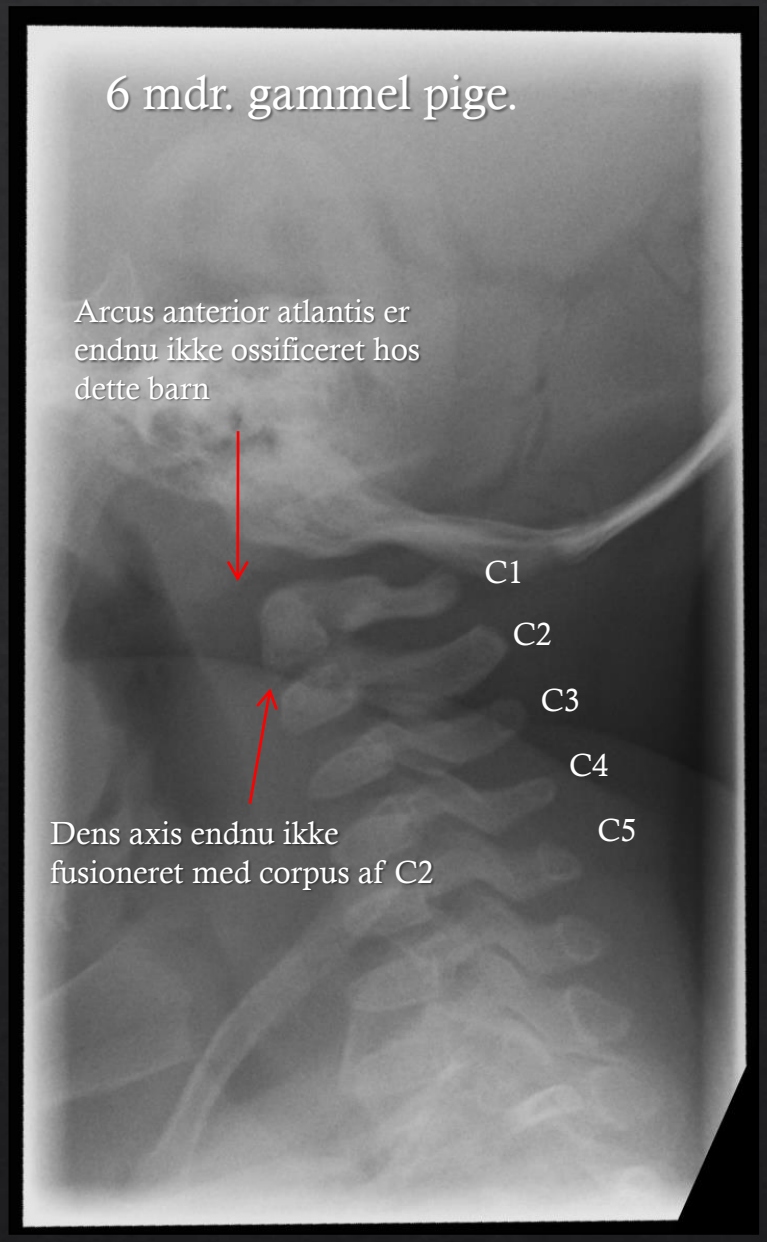
6 mdr. gammel pige.
Arcus anterior atlantis er endnu ikke ossificeret hos dette barn
C1
C2
C3
C4
C5
Dens axis endnu ikke fusioneret med corpus af C2

7 mdr. gammel pige.

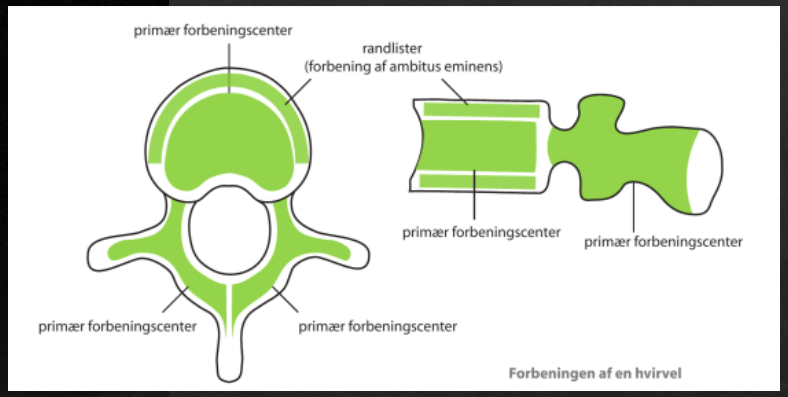

Bevægeapparatets anatomi, 13. udg.

7 mdr. gammel pige.

Der er endnu en synchondrose mellem de primære ossifikations centre. Denne er af brusk, og kan ikke ses på røntgenbilleder

Arcus

Corpus

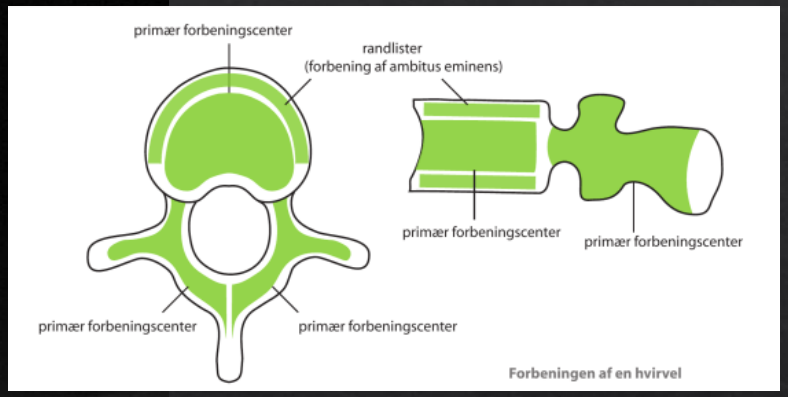

Bevægeapparatets anatomi, 13. udg.


Pige 8
år

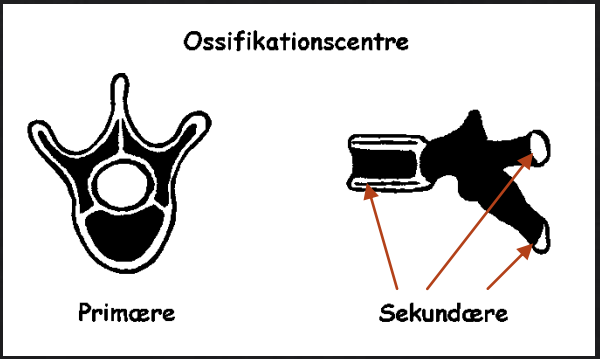
Ossifikationscentre
Primære
Sekundære

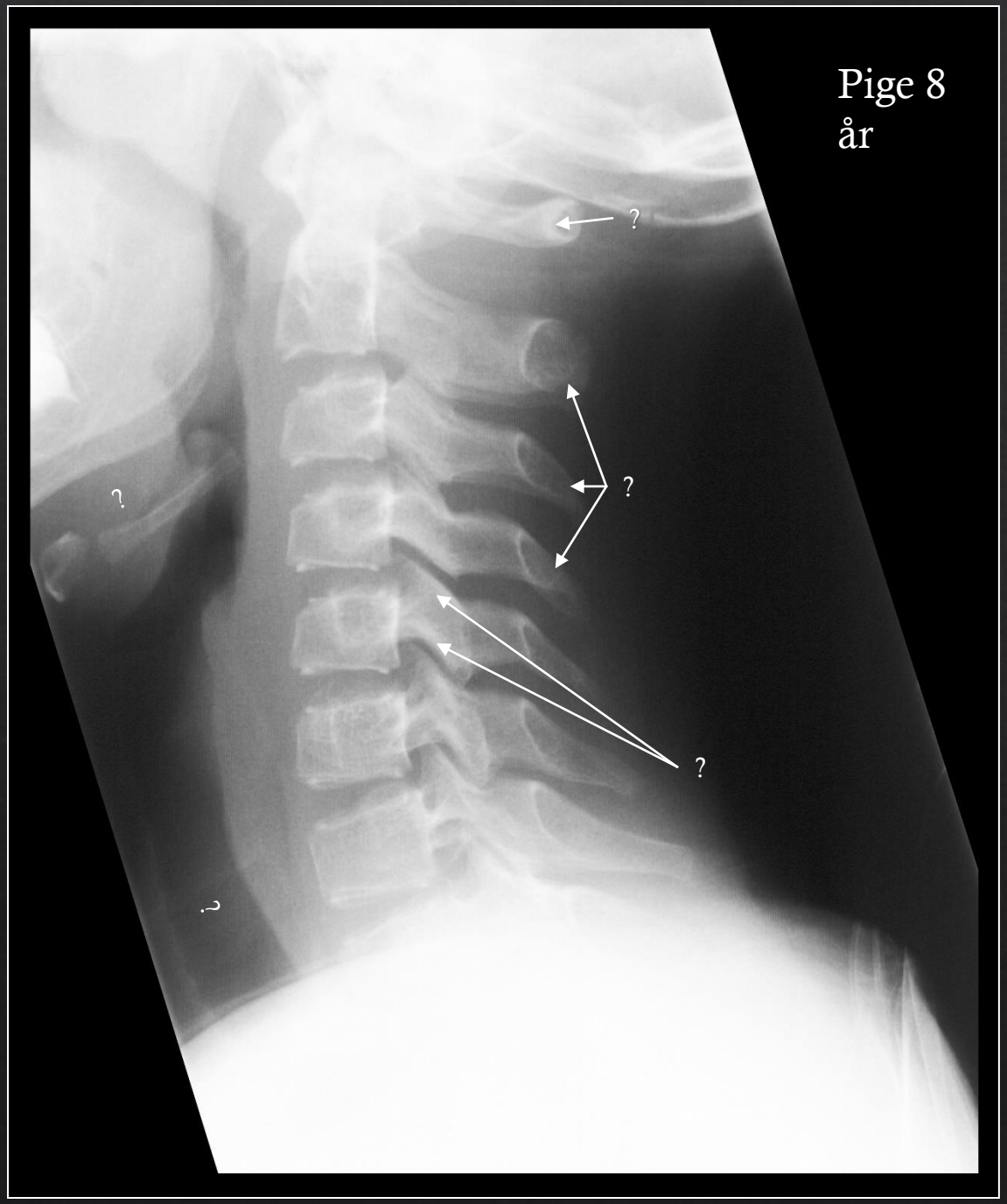
Pige 8 år
?
?
?
?

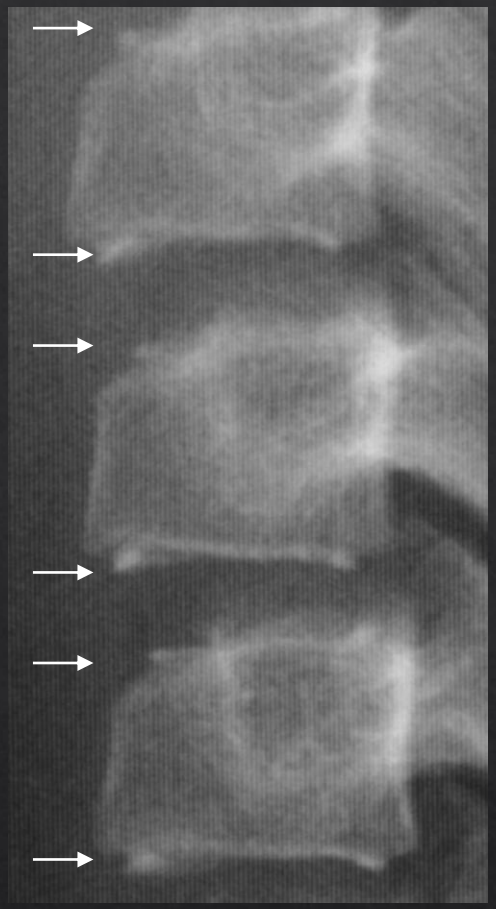

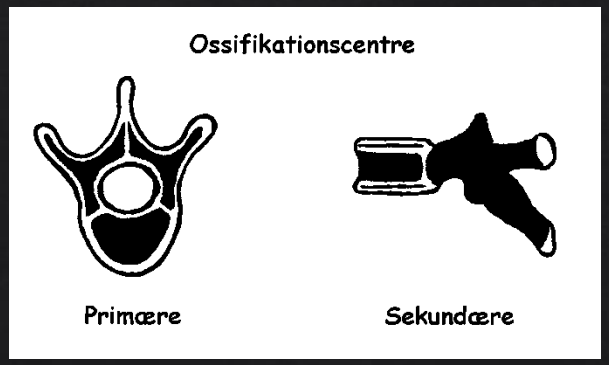
Ossifikationscentre
Primære
Sekundære

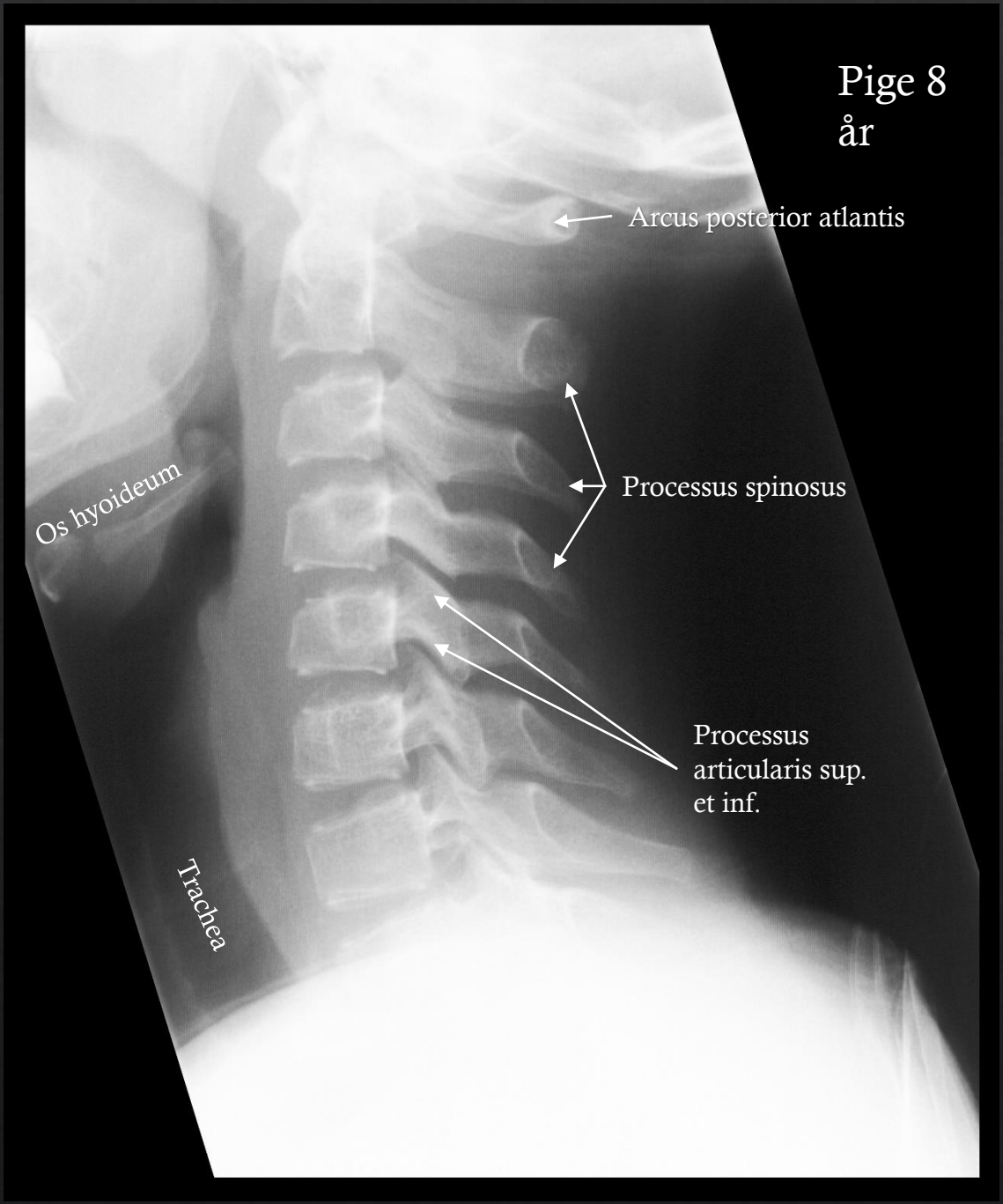
Pige 8 år
Arcus posterior atlantis
Os hyoideum
Processus spinosus
Processus articularis sup. et inf.
Trachea

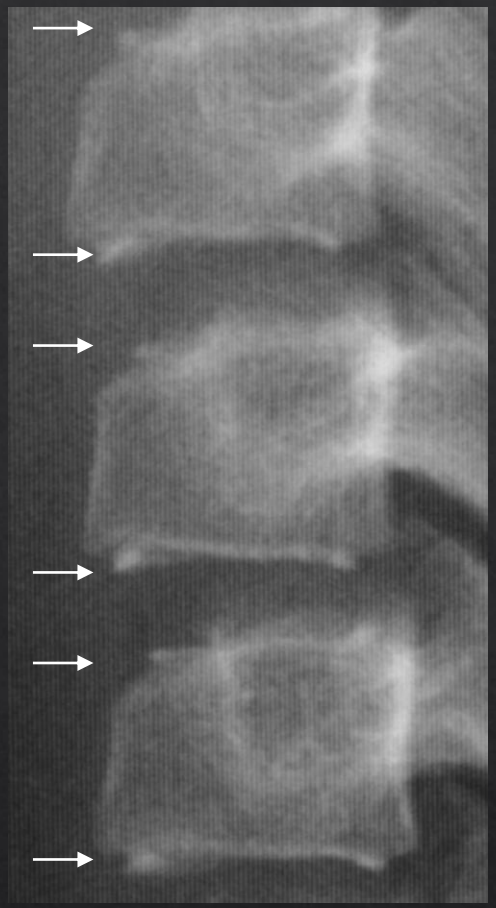

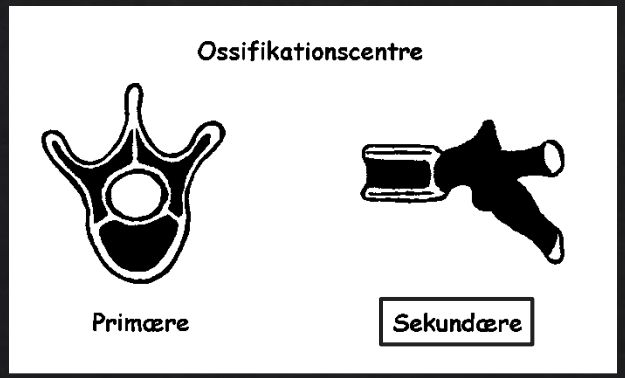
Ossifikationscentre
Primære
Sekundære

Dreng 16 år

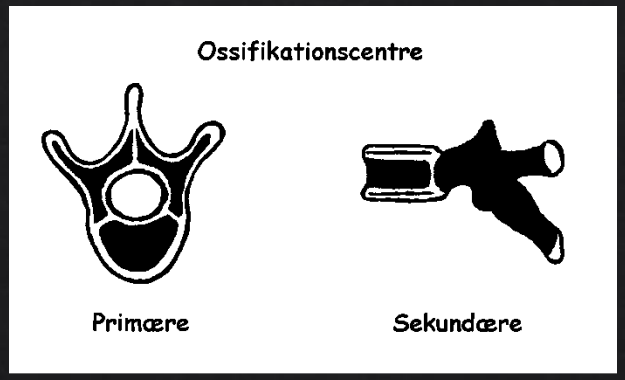

Dreng 16 år

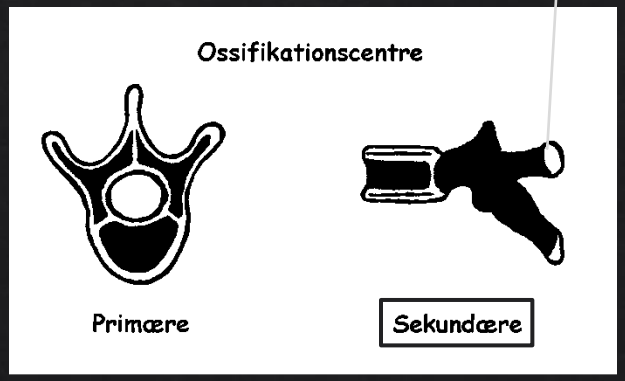

Columna cervicalis

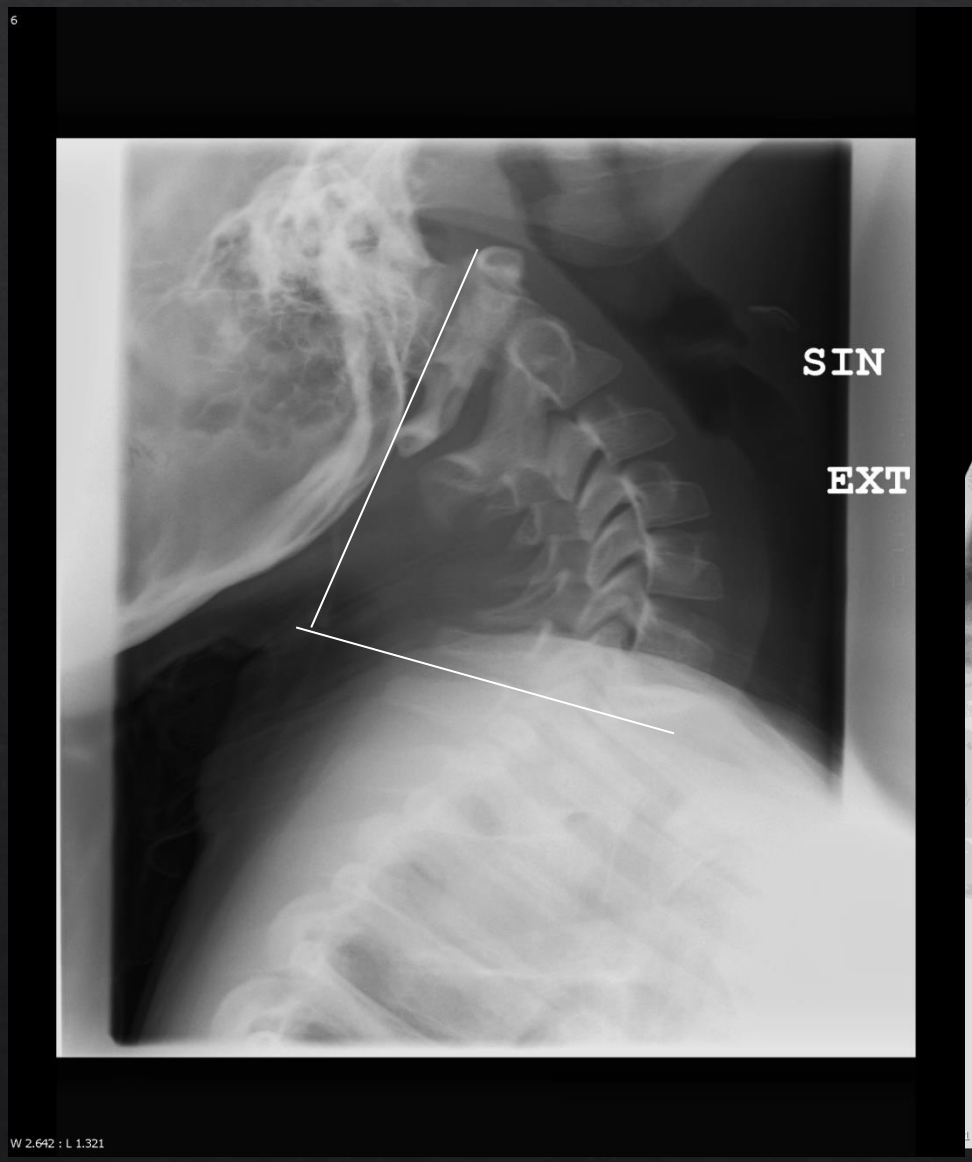

Pige, 8 år

Extension

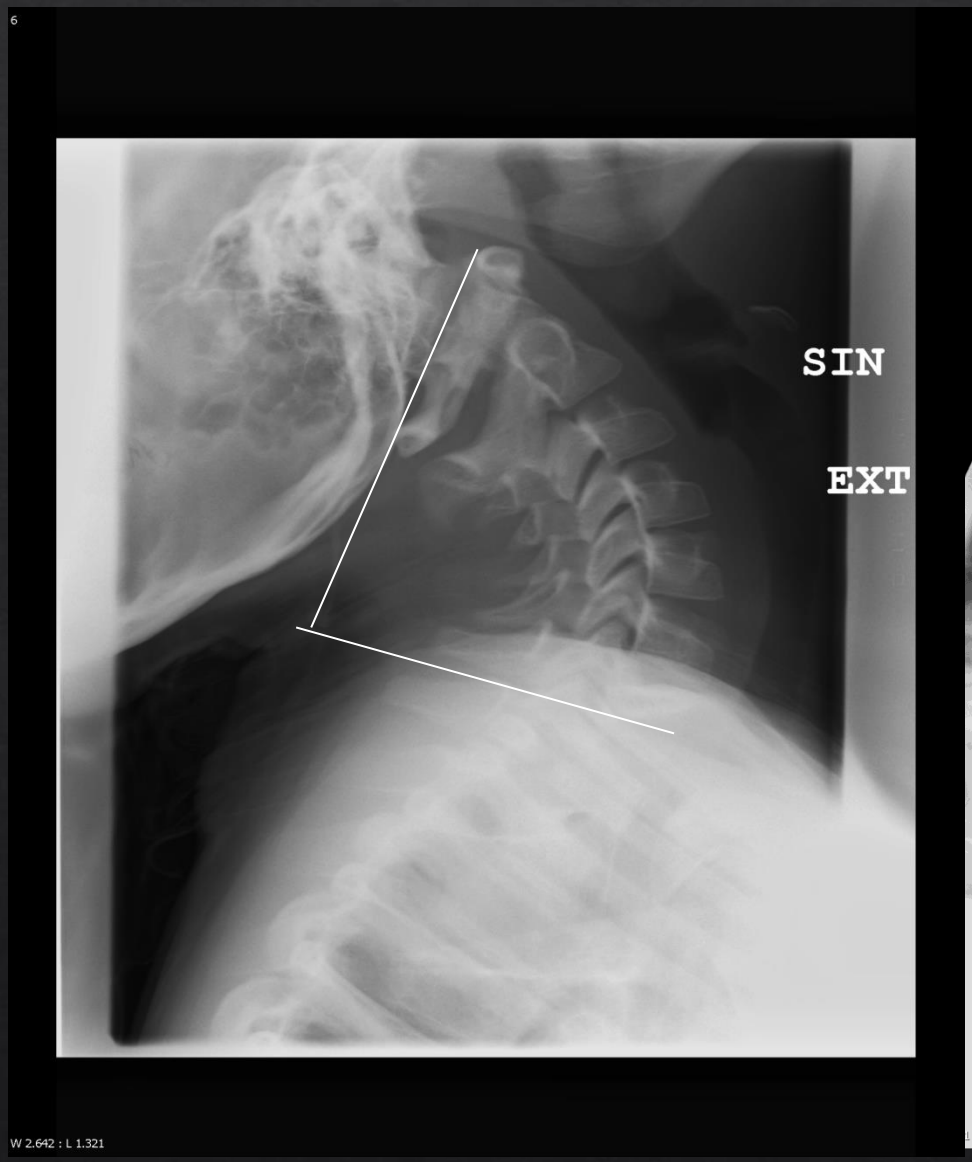

Flexion

Pige, 8 år

Densoptagelse

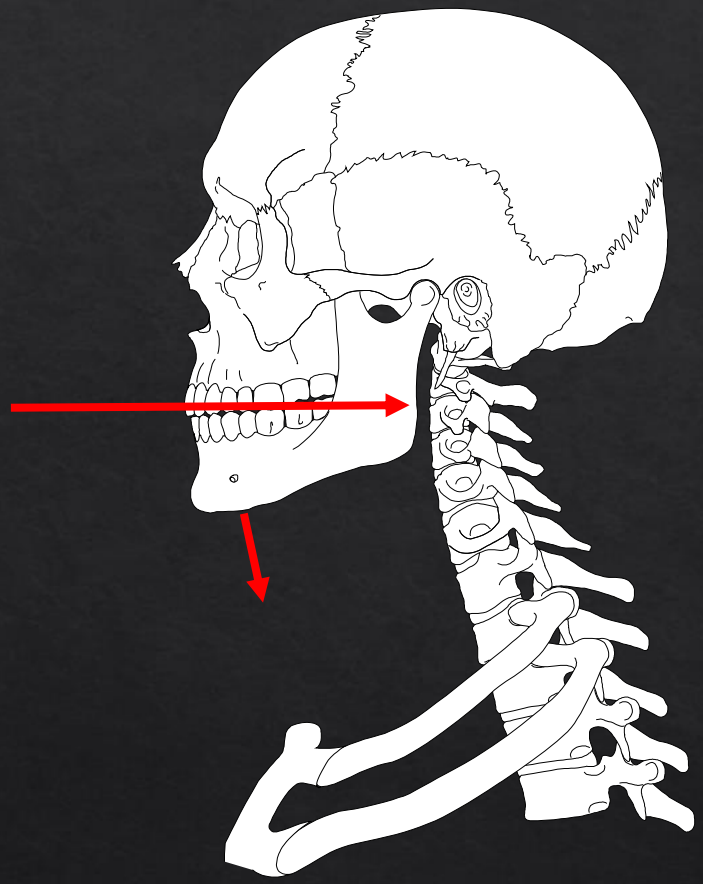

Densoptagelse

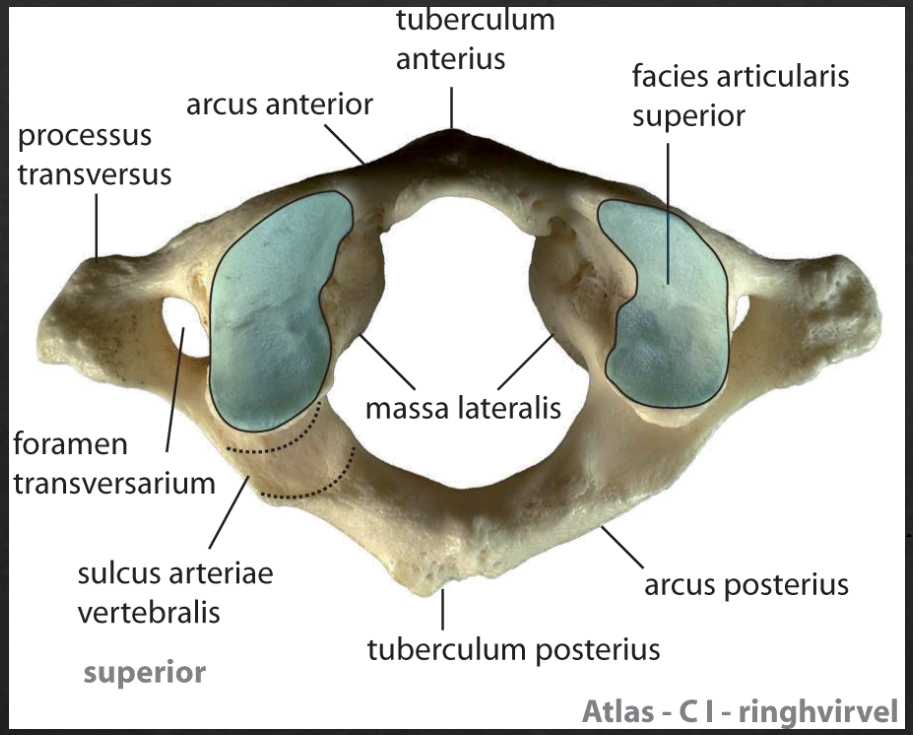

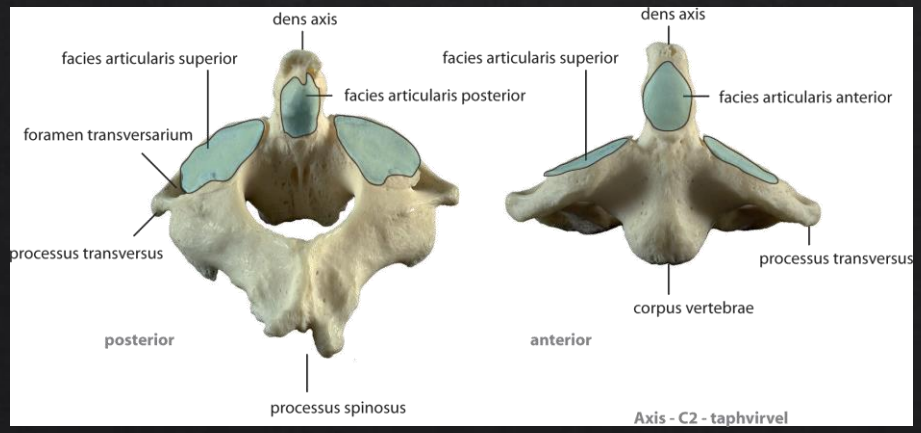

Densoptagelse

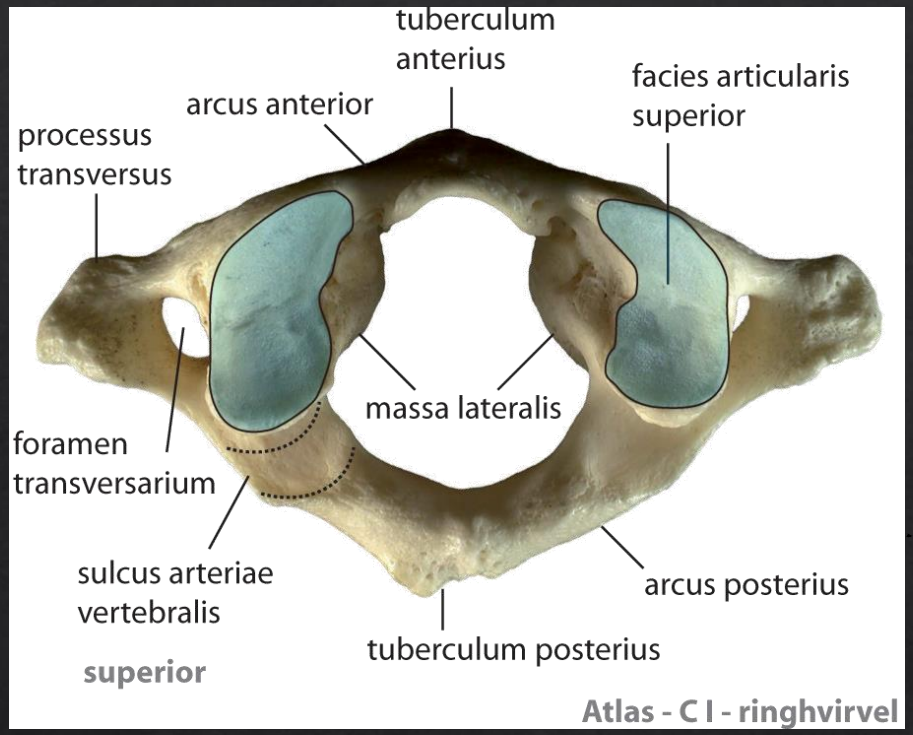

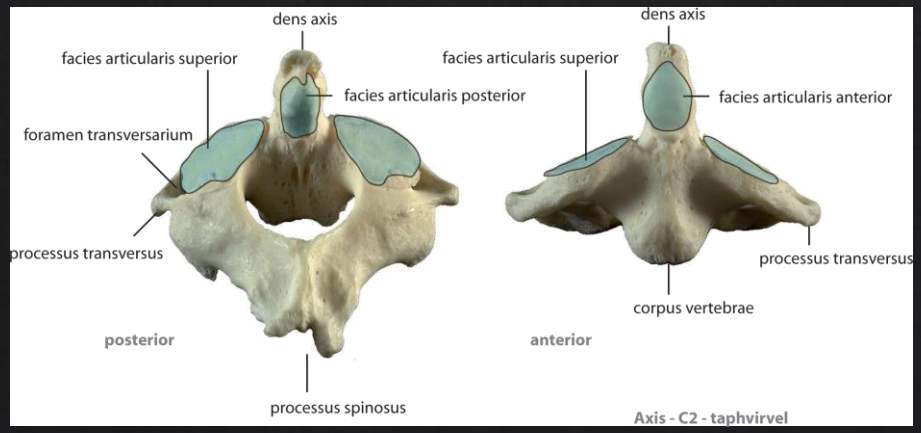

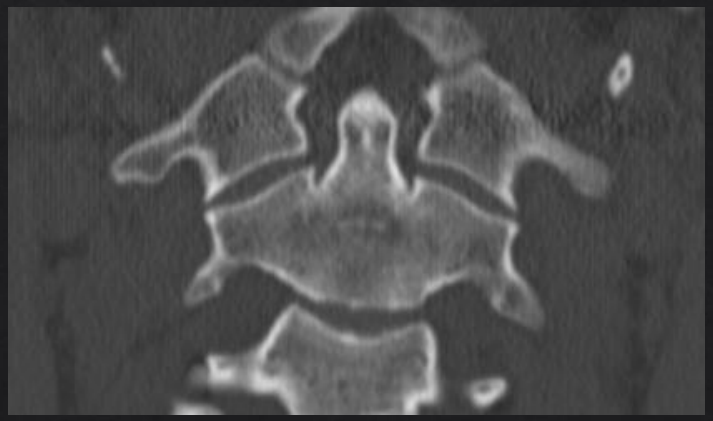

Densoptagelse

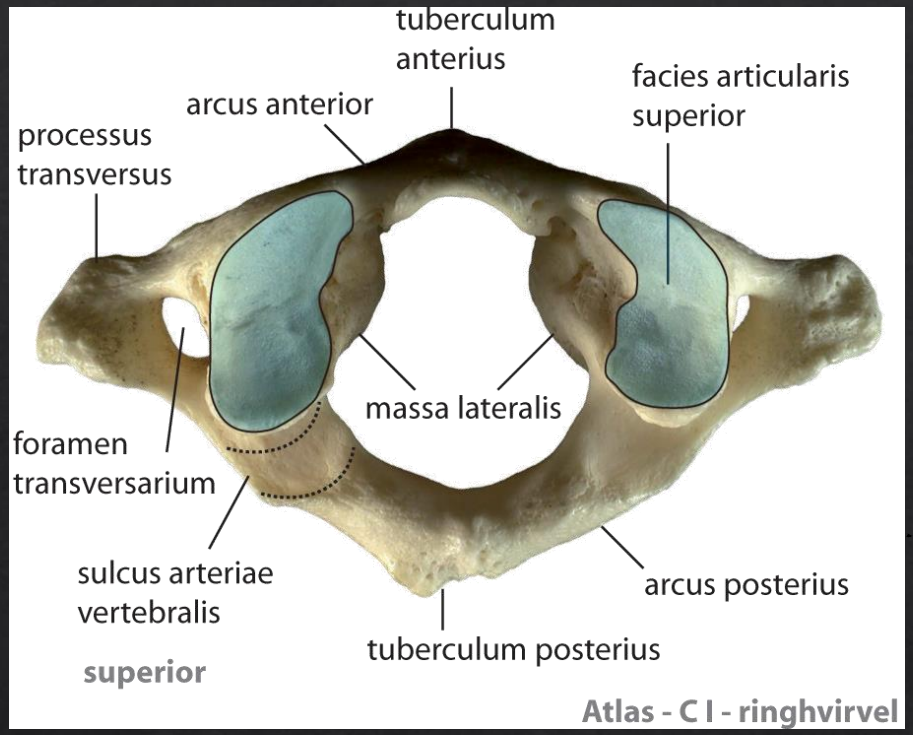

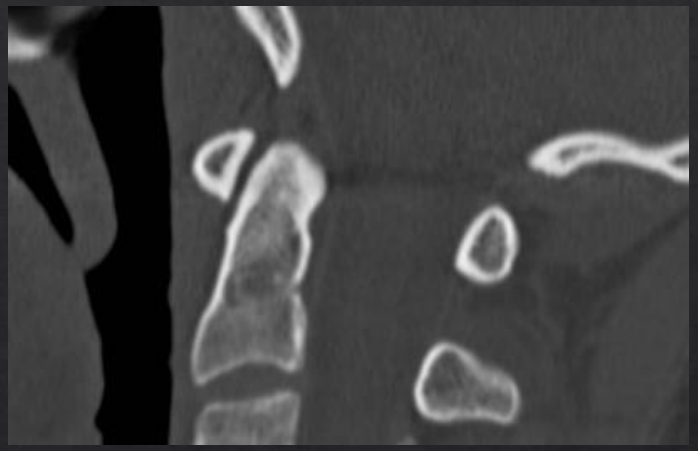

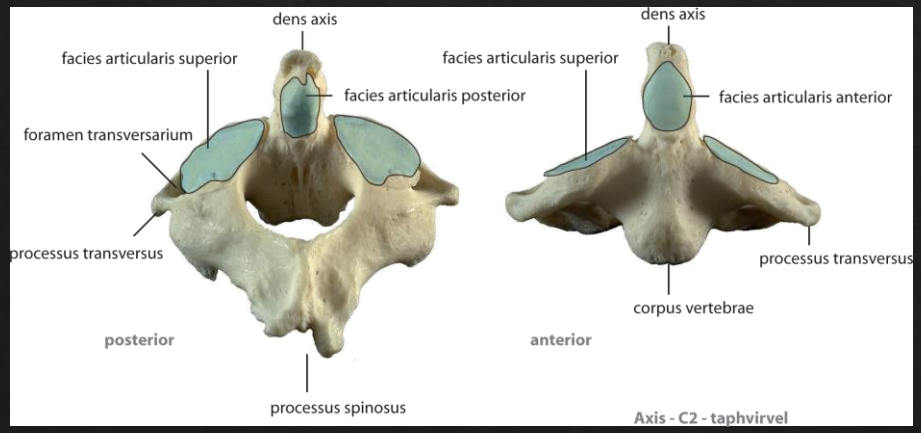

Densoptagelse

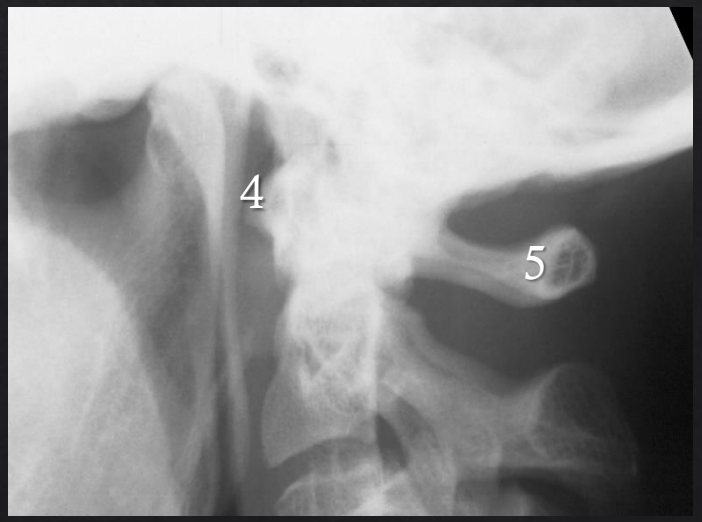

Densoptagelse

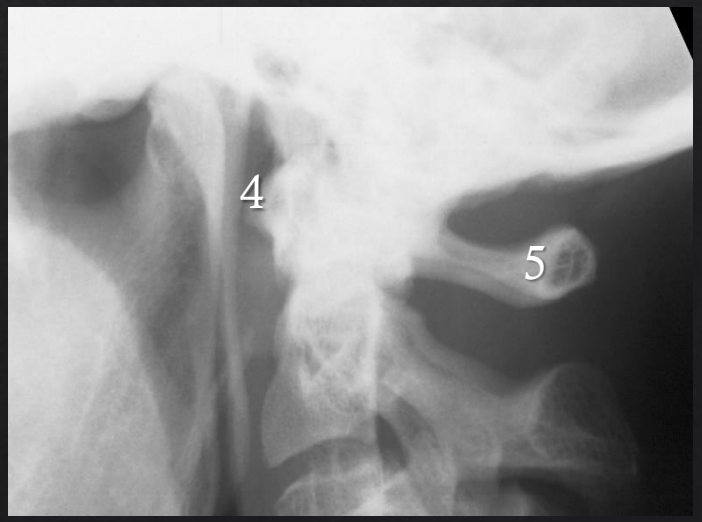

1) Dens axis
2) Massa lateralis atlantis
3) Processus transversus CI
4) Arcus anterior atlantis
5) Arcus posterior atlantis

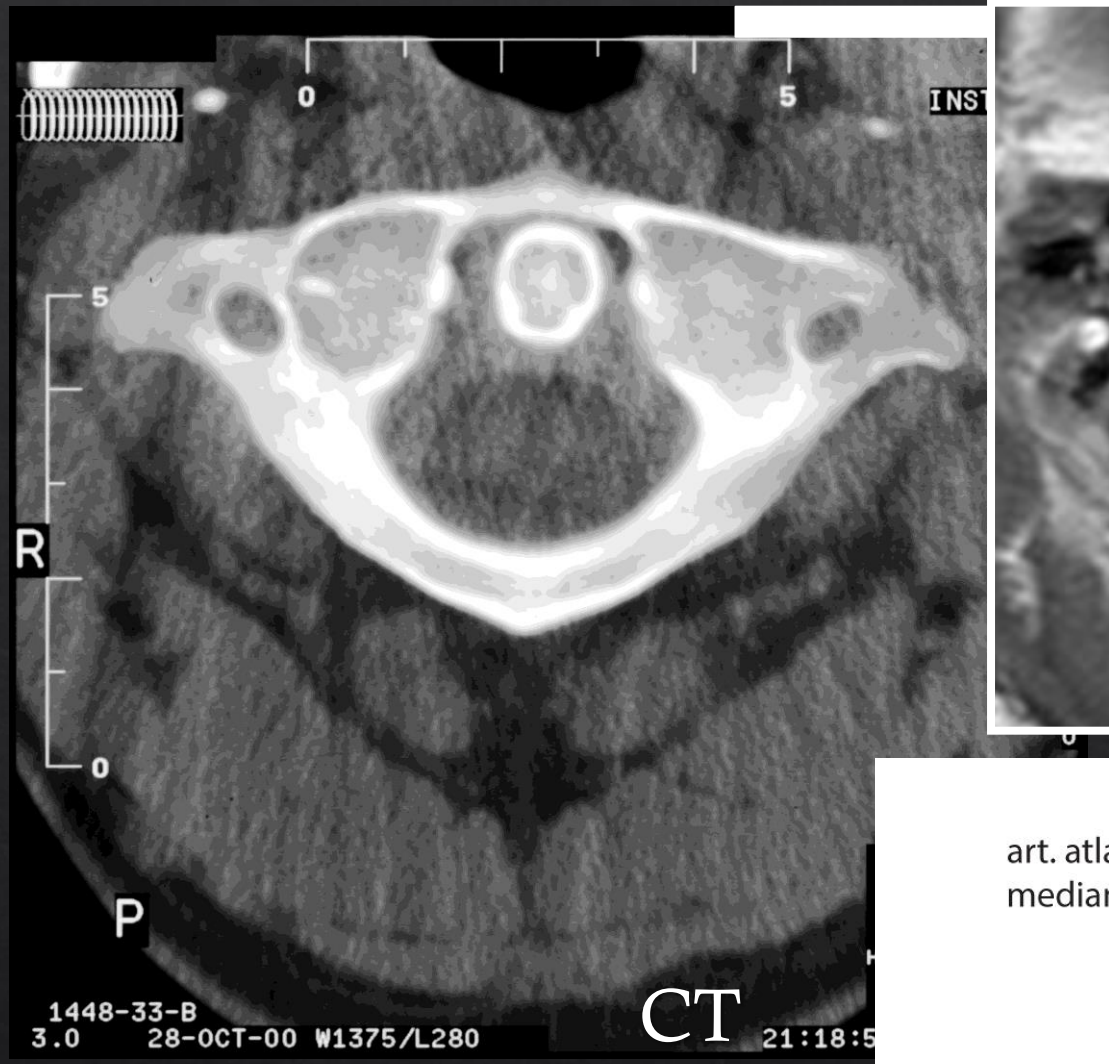
0
5
INST
5
R
0
P
1448-33-B
3.0 28-OCT-00 W1375/L280
CT
21:18:5


MR (T2)

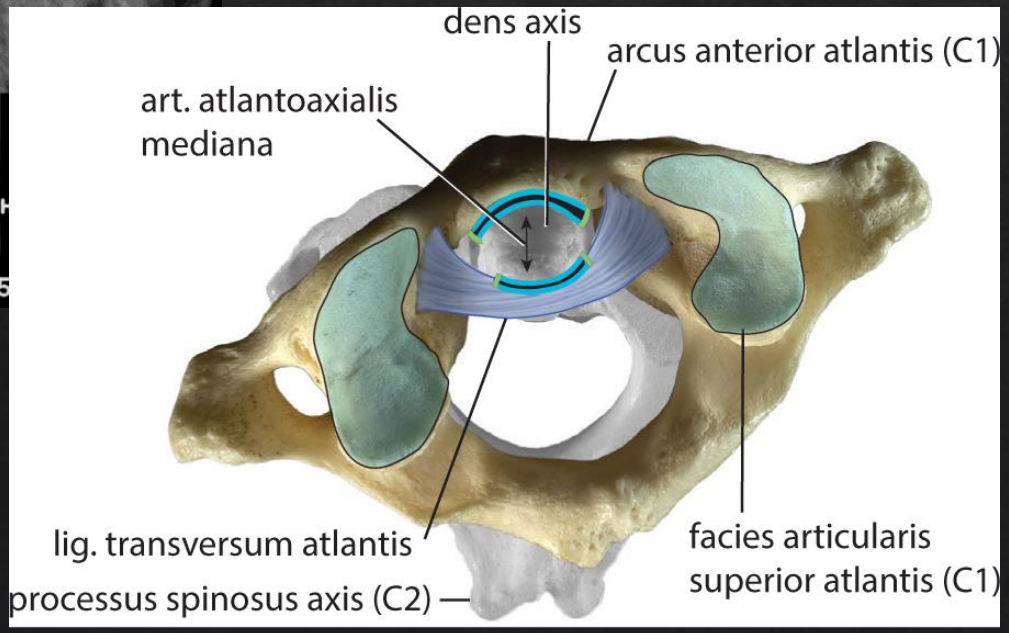
dens axis
arcus anterior atlantis (C1)
art. atlantoaxialis mediana
lig. transversum atlantis
processus spinosus axis (C2)
facies articularis superior atlantis (C1)

Atlas


0
5
INST
6
2
5
R
7
P
CT
1448-33-B
3.0 28-OCT-00 W1375/L280
21:18:50.32

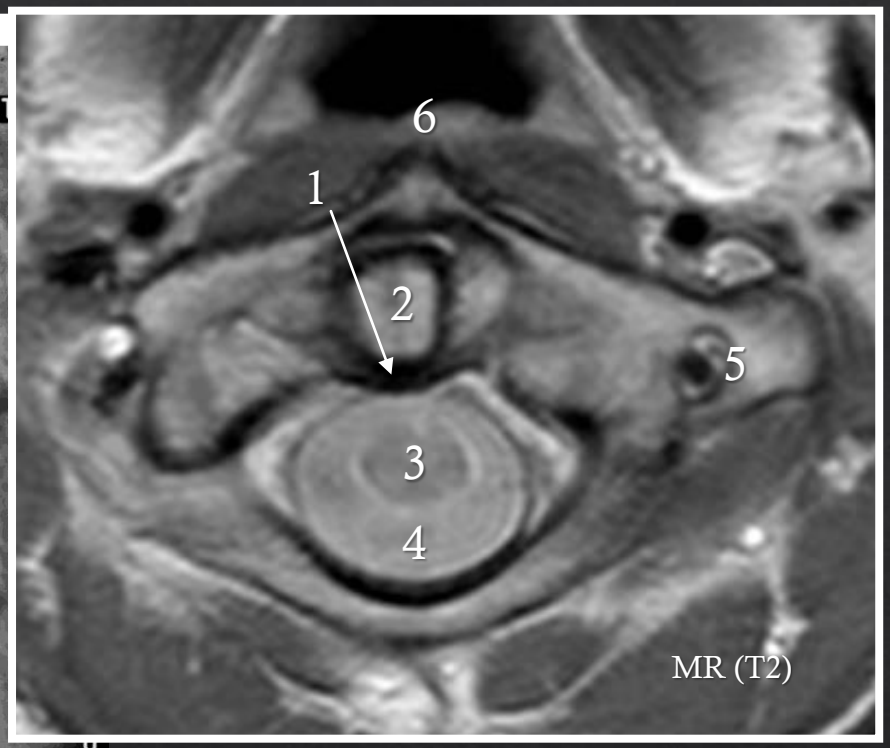
6
1
2
5
3
4
MR (T2)

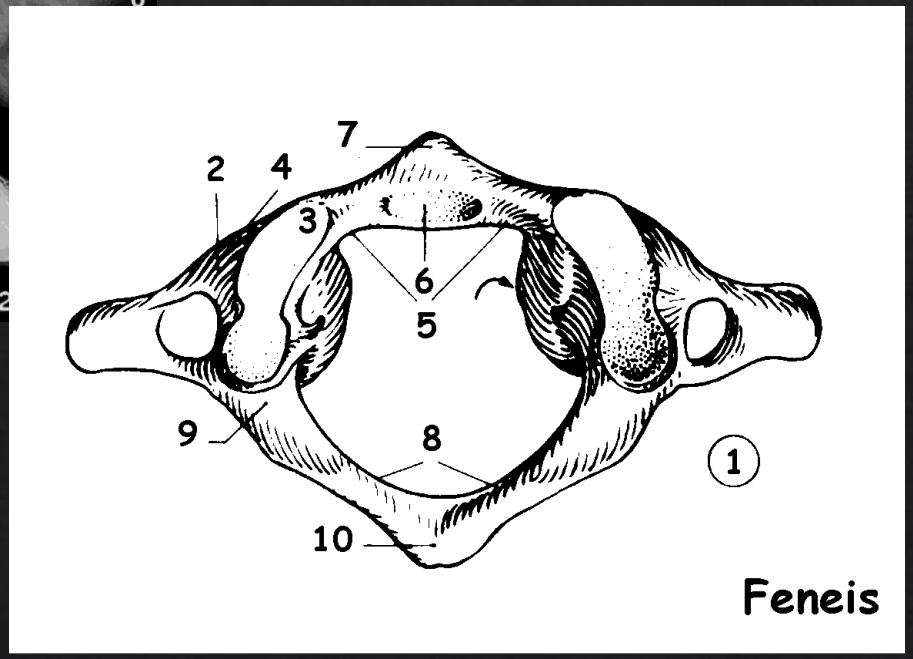
7
2
4
3
6
5
9
8
10
1
Feneis

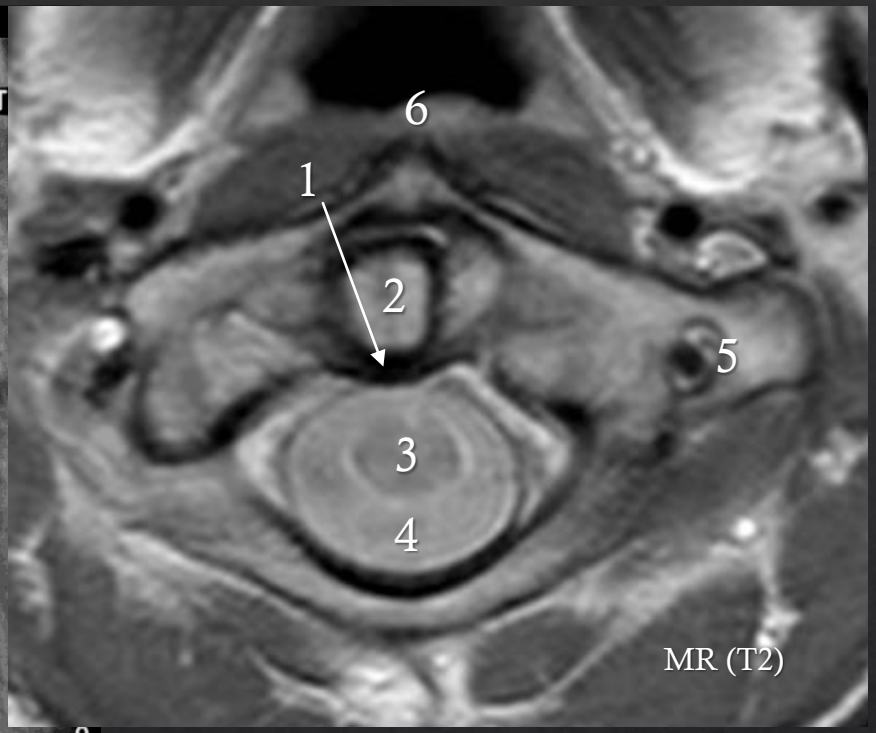

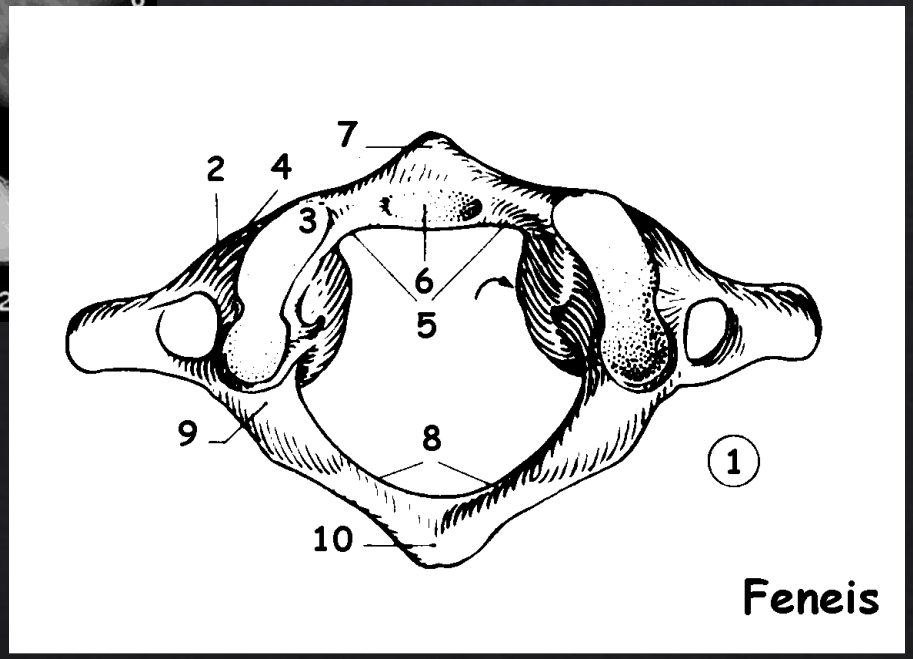

1) Ligamentum transversum atlantis
2) Dens axis
3) Medulla spinalis
4) Liquor cerebrospinalis
5) Foramen transversarium (med a. vertebralis – sort)
6) Tuberculum anterius
7) Tuberculum posterius

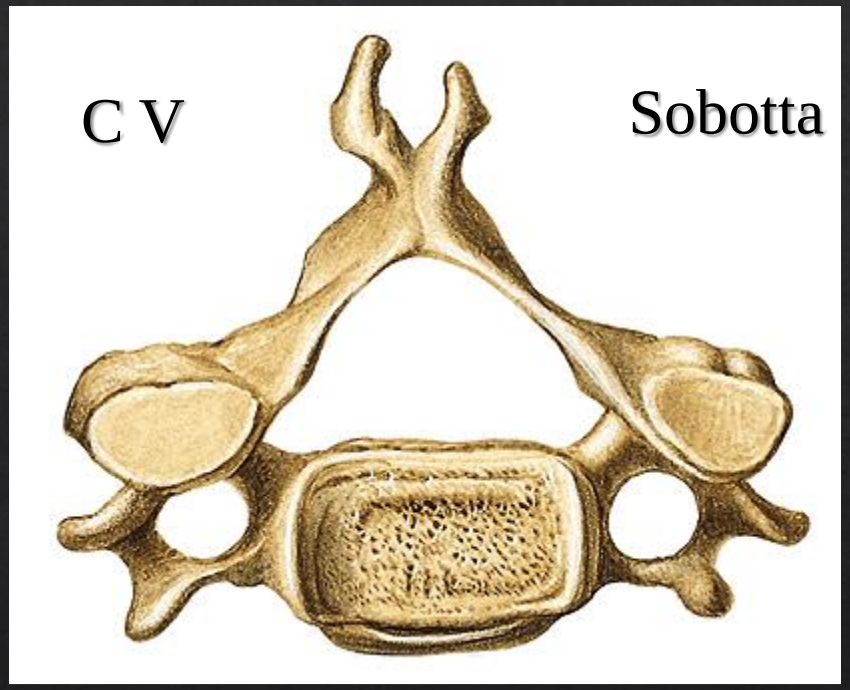
C V
Sobotta

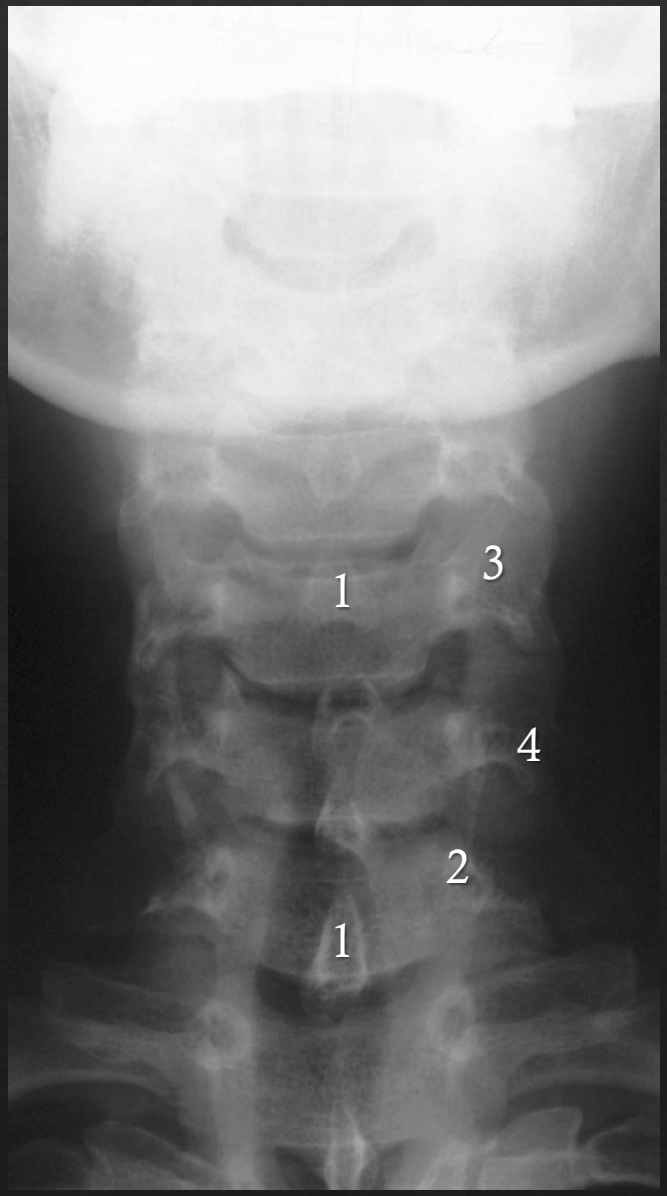
1
3
4
2
1

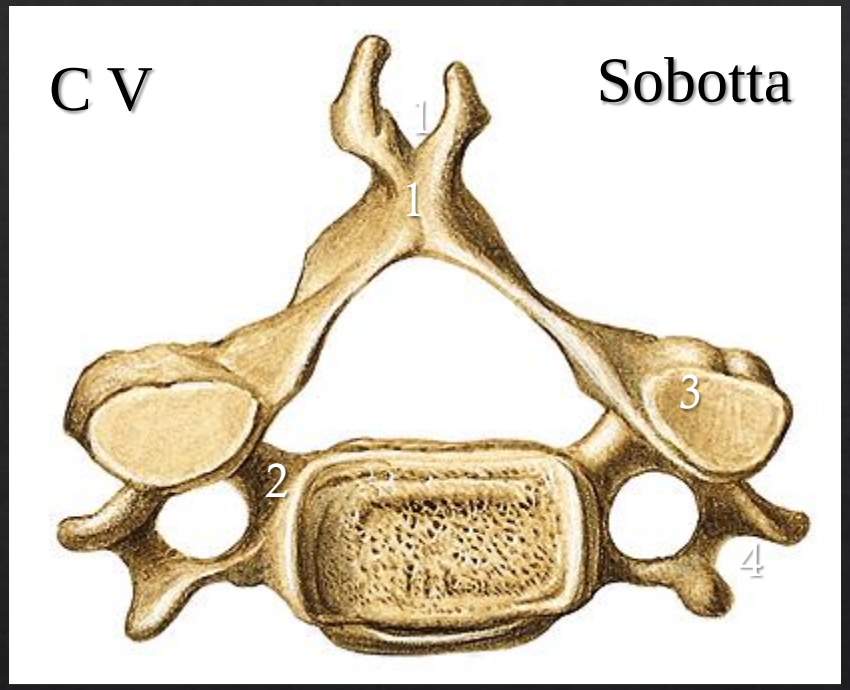
C V
Sobotta
1
1
3
2
4

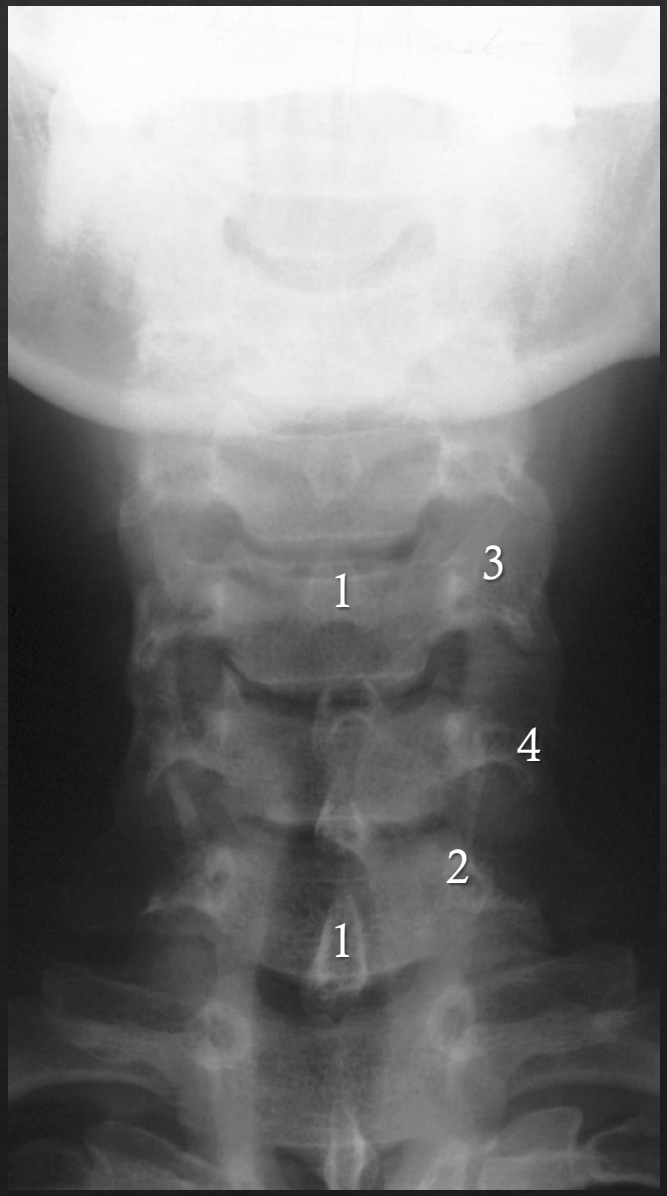

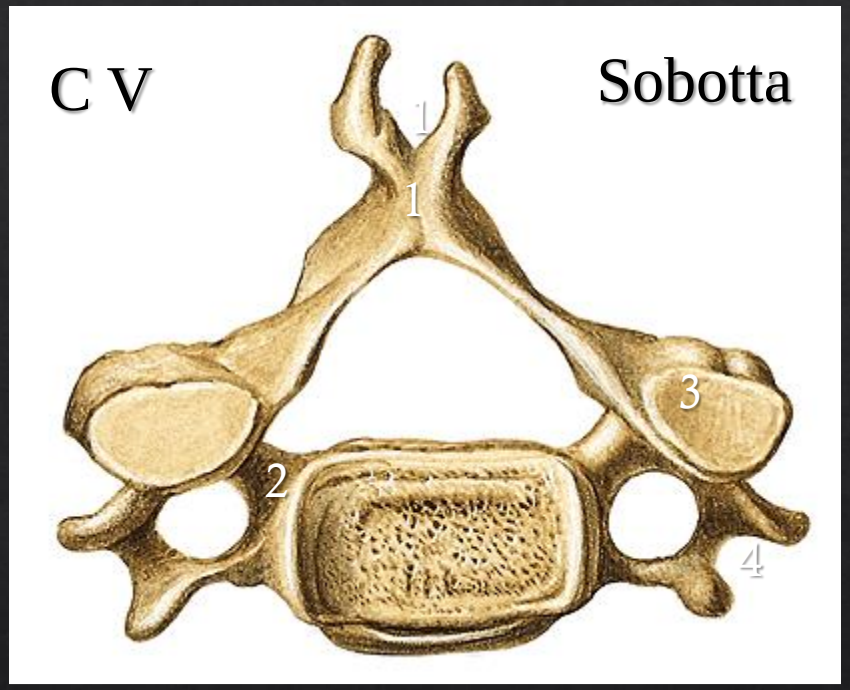

1) Processus spinosus
2) Pediculus
3) Processus articularis (inf. et sup.)
4) Processus transversus

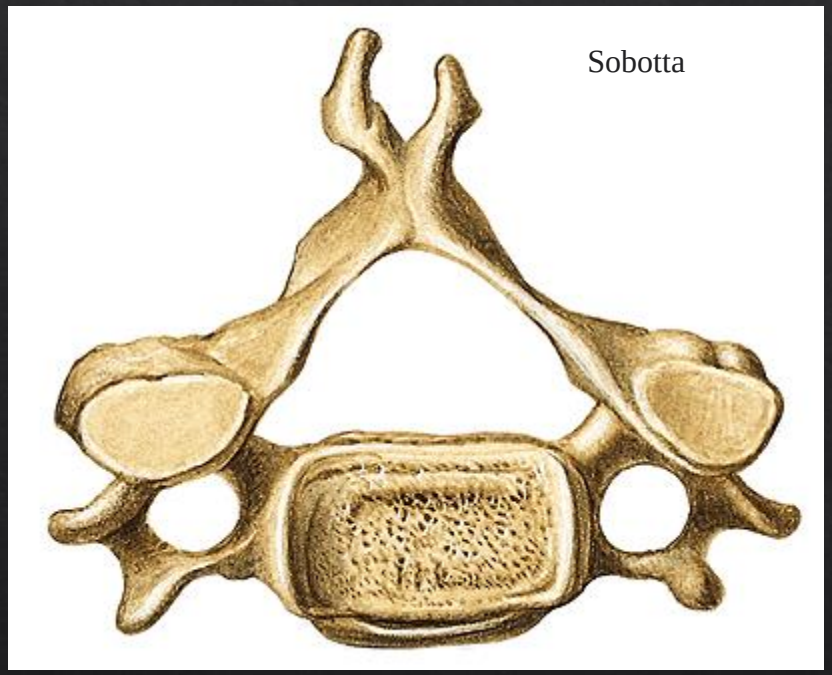
Sobotta

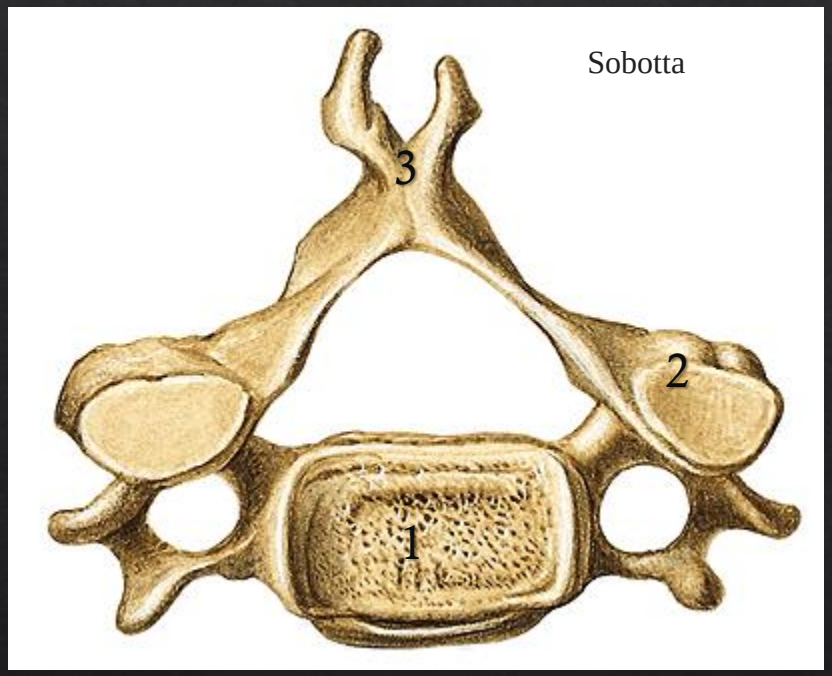
Sobotta
3
2
1

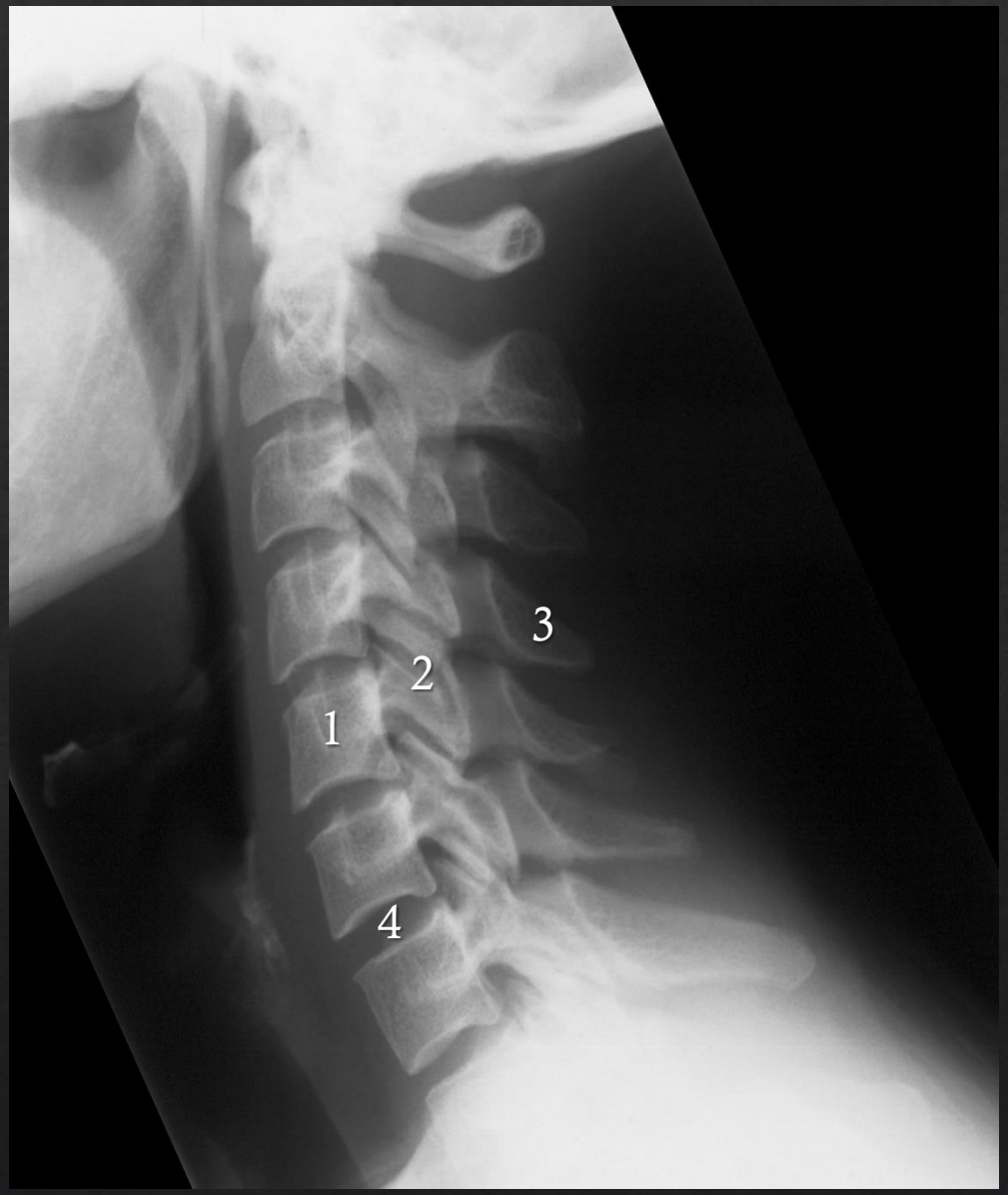
3
2
1
4

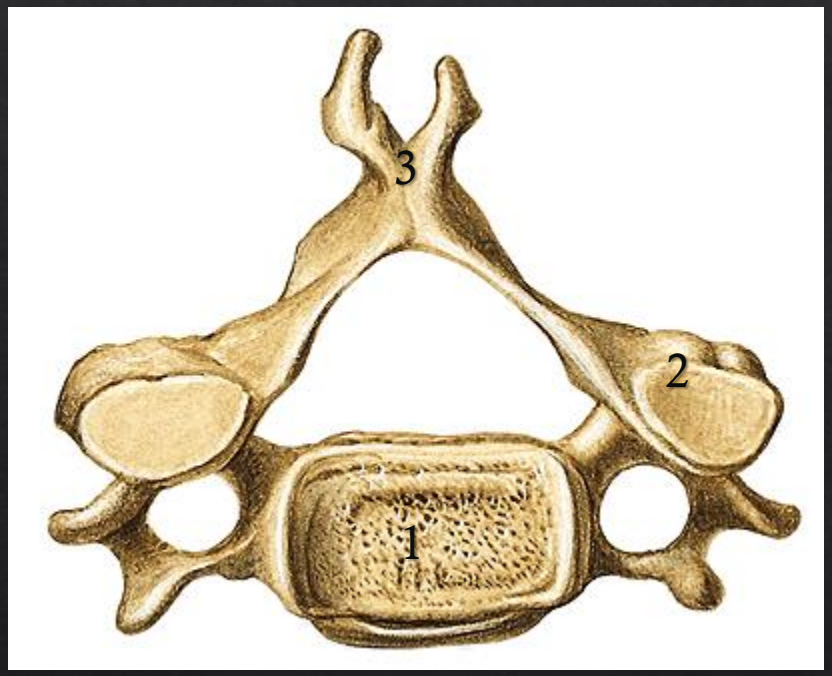

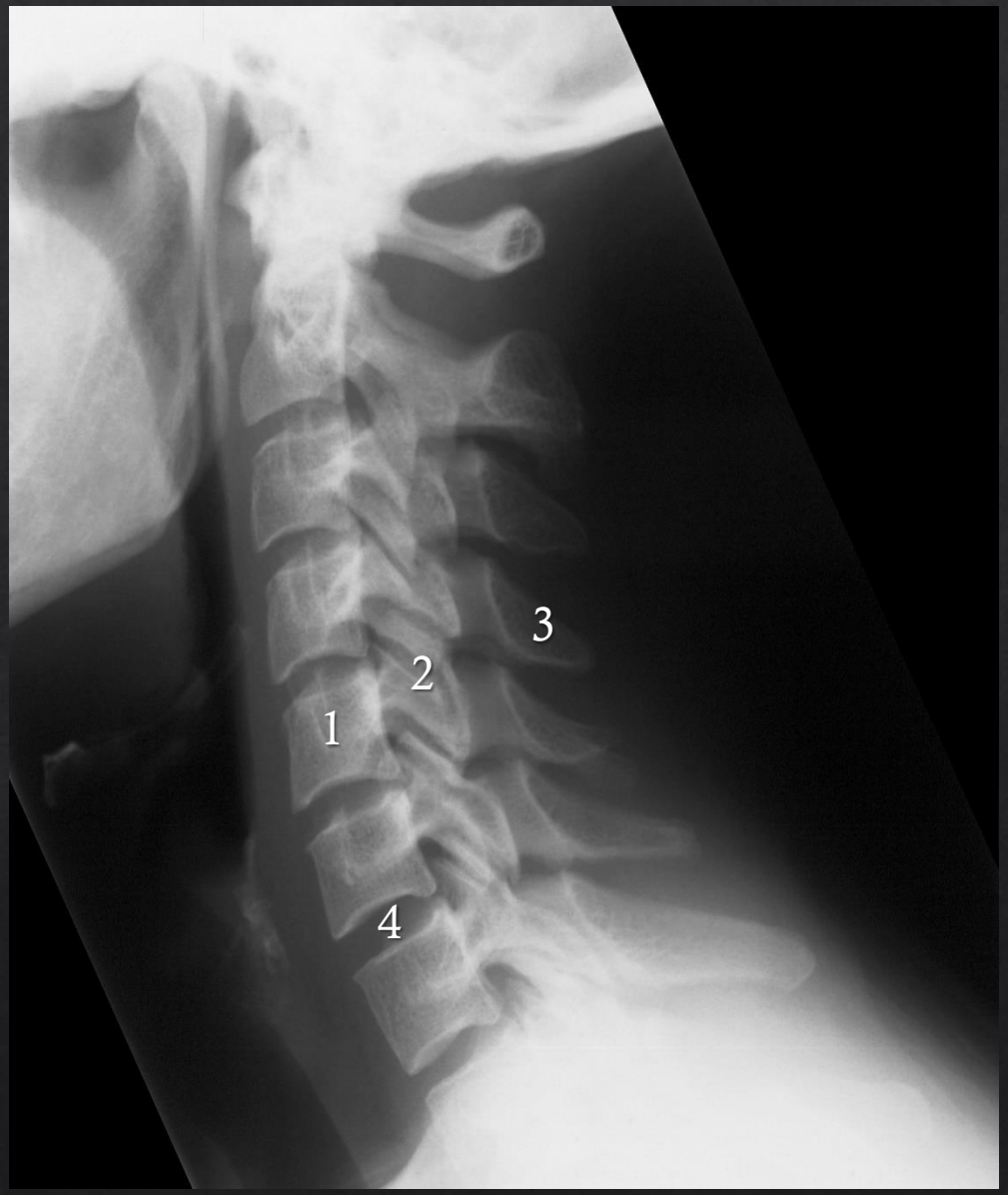

1) Corpus vertebrae C V
2) Articulatio zygapophysialis (Facetled)
3) Processus spinosus vertebrae C IV
4) Discus intervertebralis C VI/VII

CT 3D

www.radiology.dk

Skråoptagelse af columna cervicalis

www.radiology.dk

Skråoptagelse af columna cervicalis

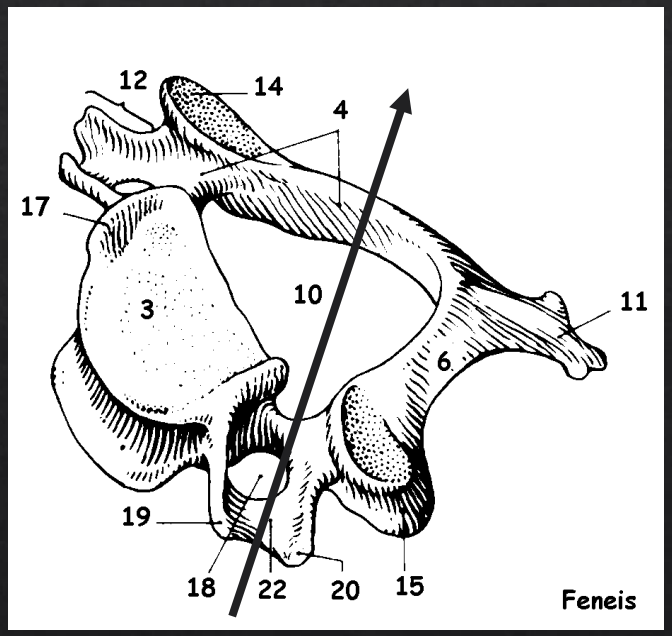

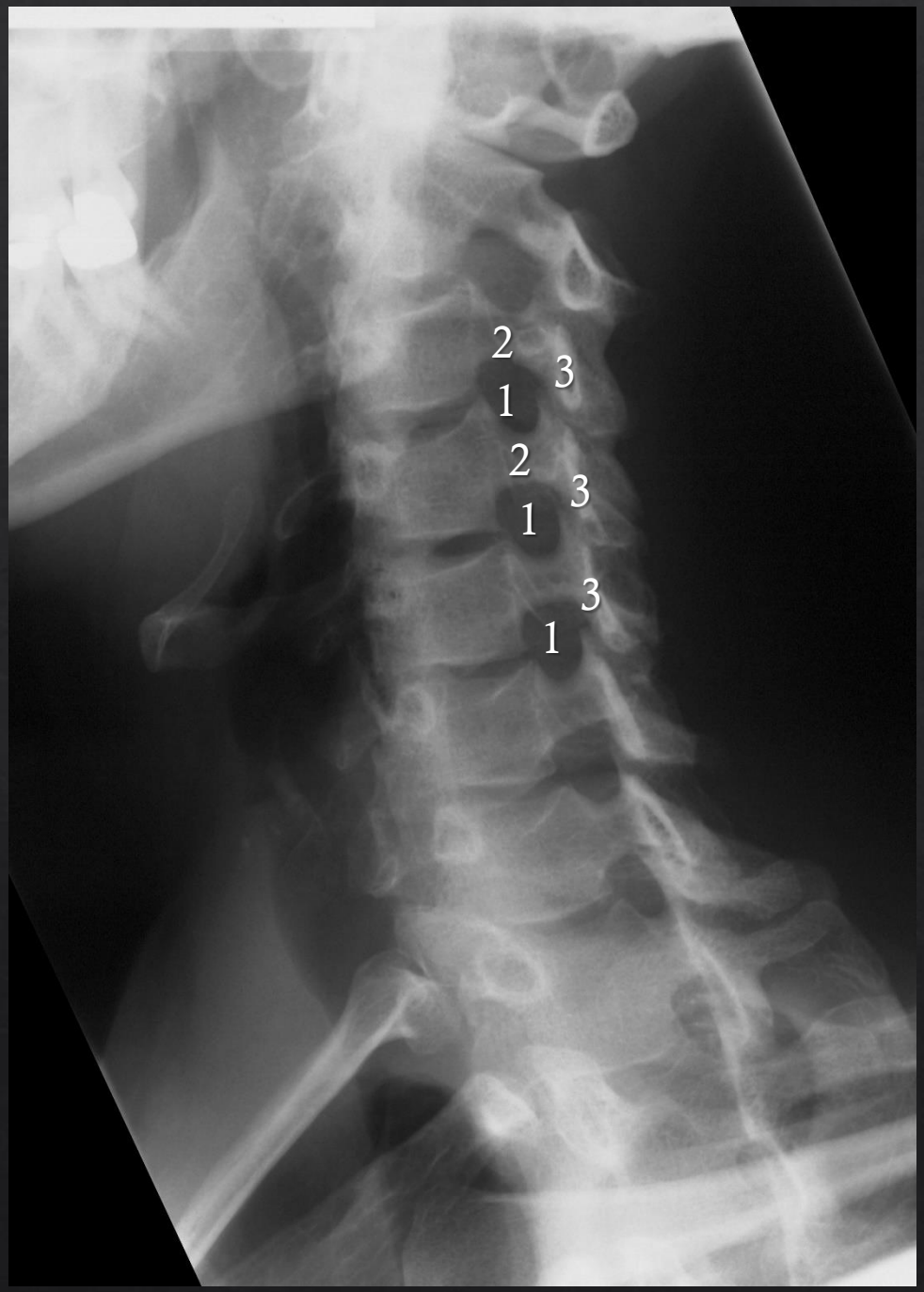

Skråoptagelse

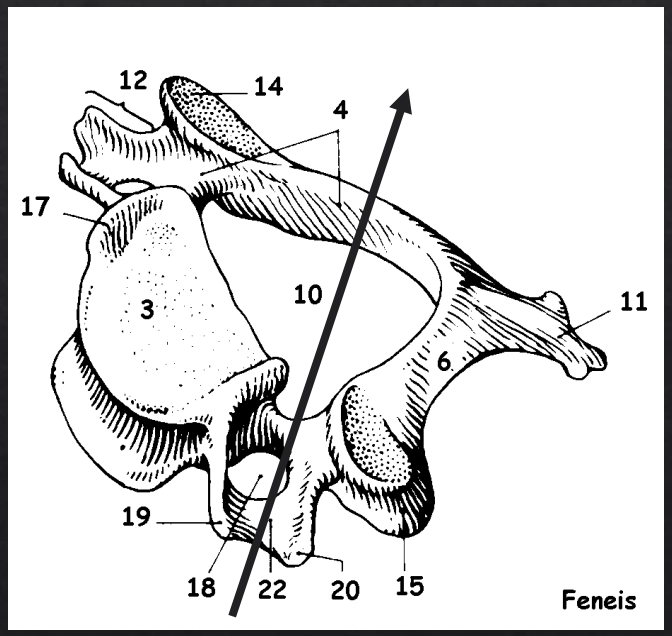

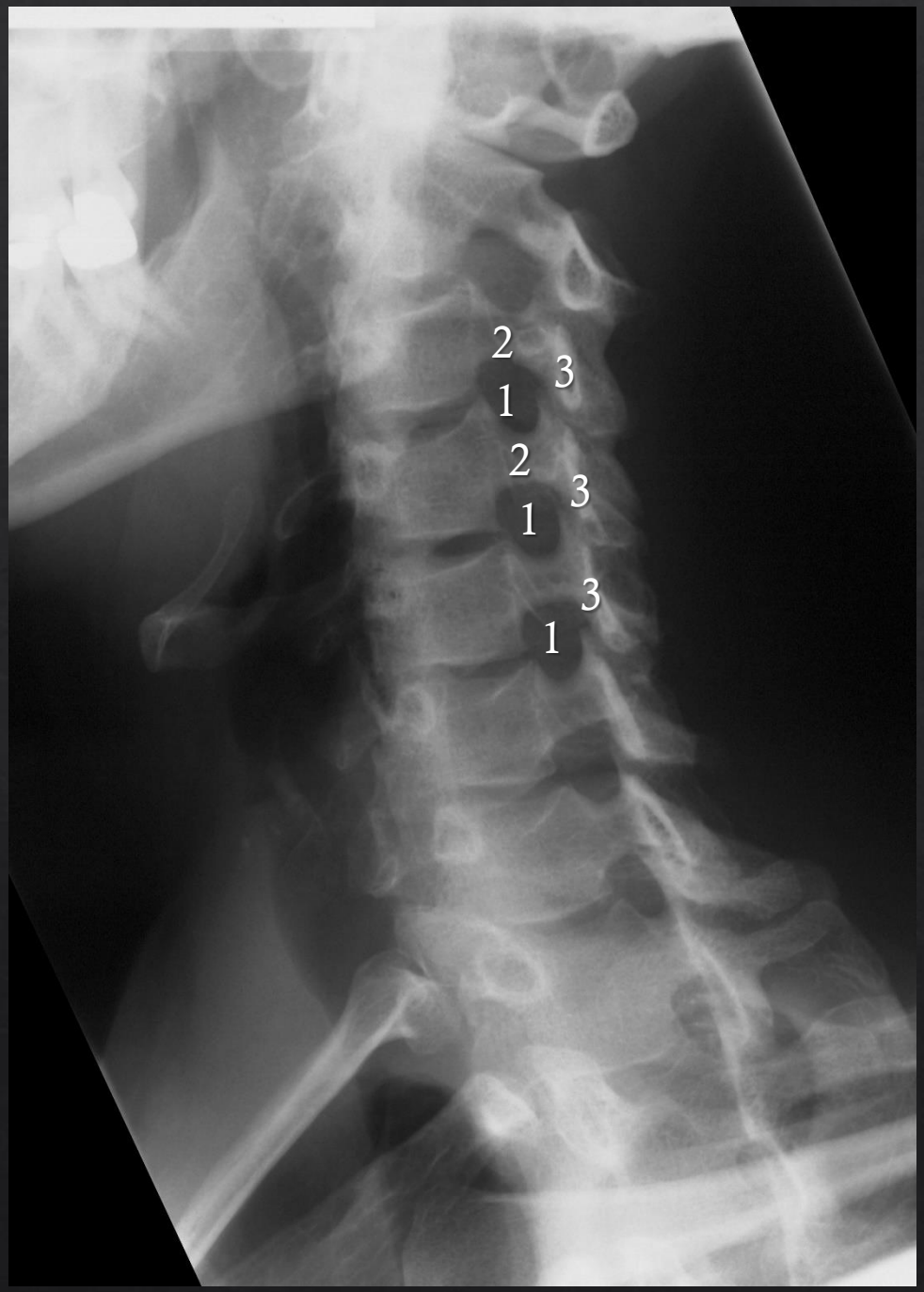

Skråoptagelse

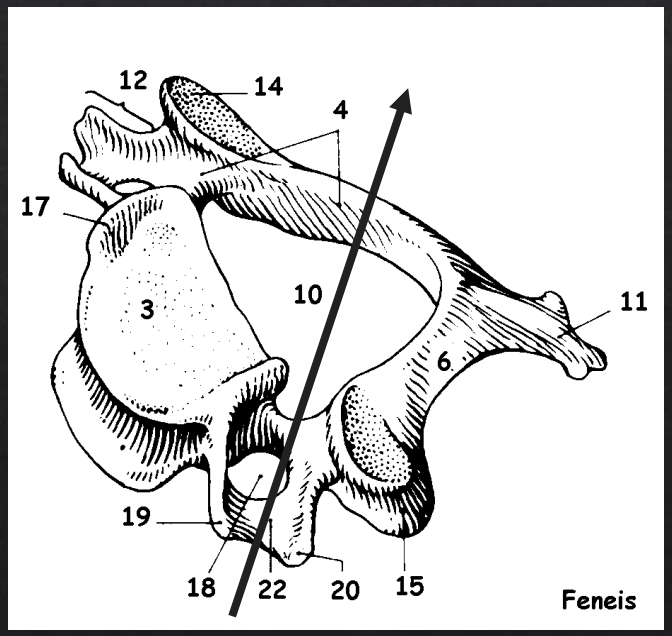

1) Foramen intervertebrale
2) Pediculis arcus vertebrae
3) Lamina arcus vertebrae

Costa cervicalis

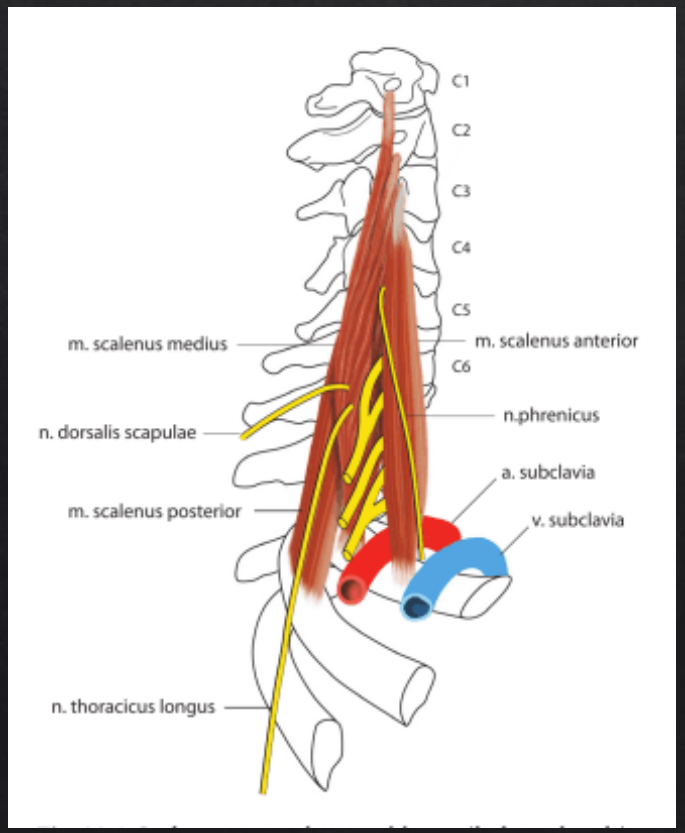

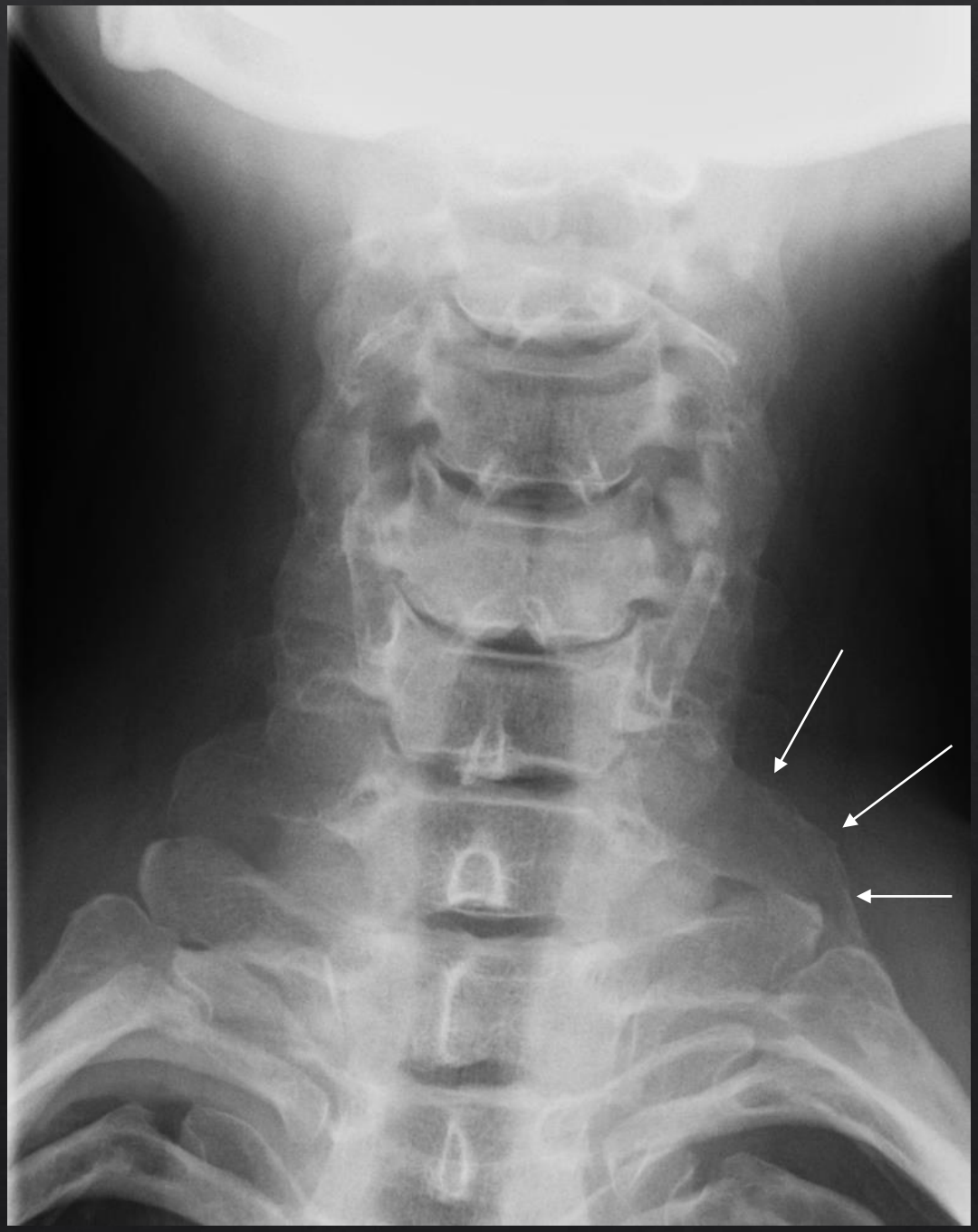

Costa cervicalis

Et langt costa cervicalis kan give tryk på nabostrukturerne, eksempelvis a. subclavia.

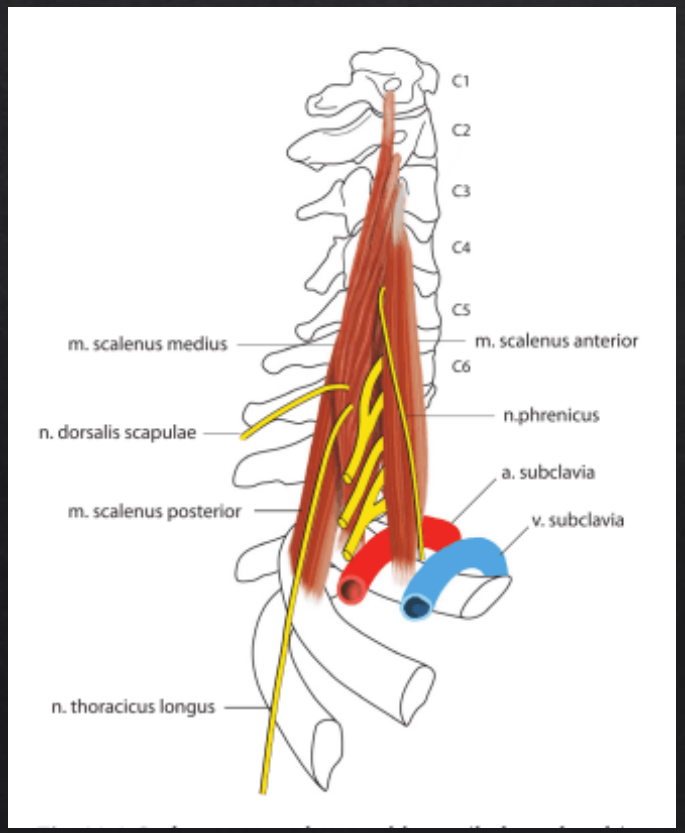

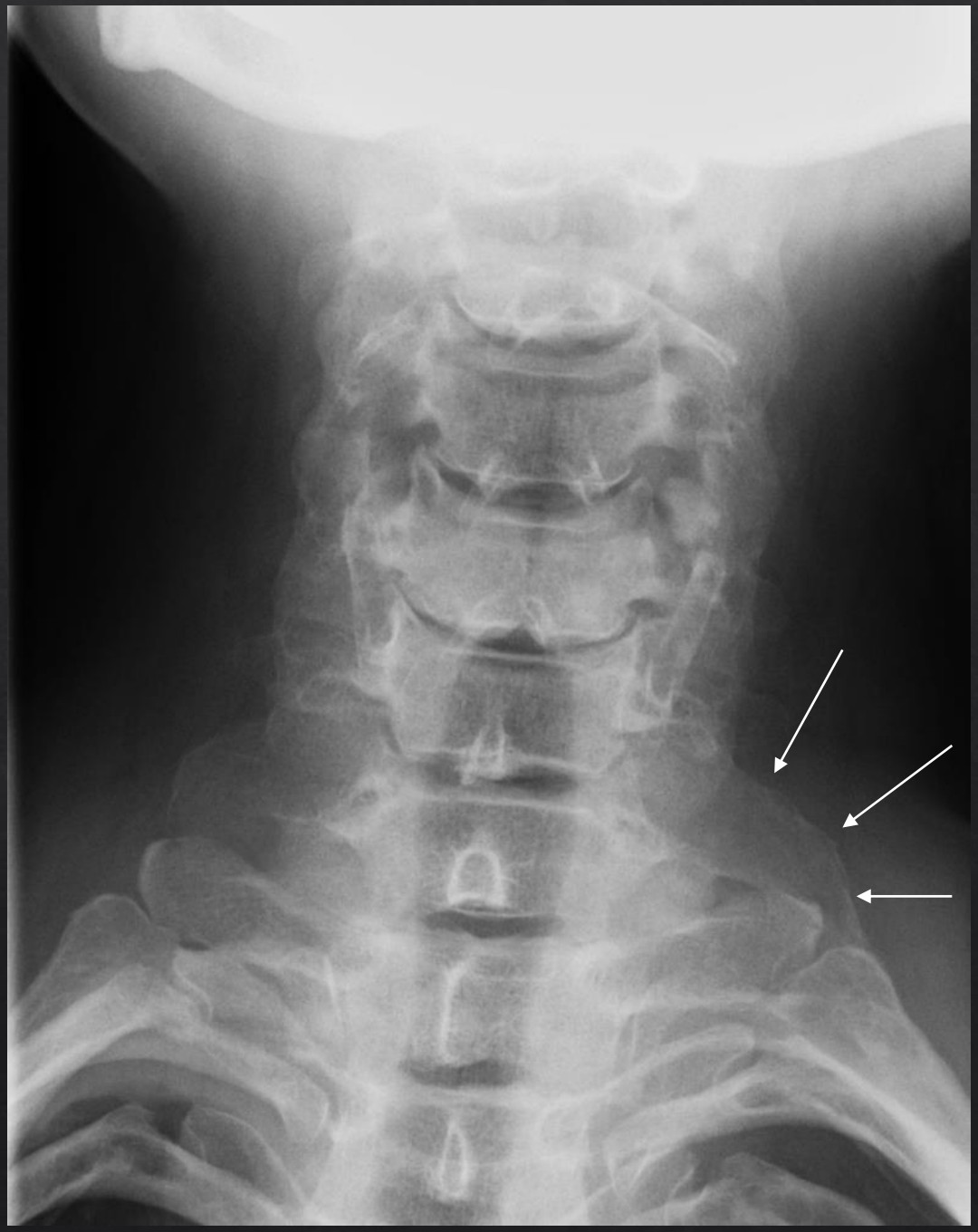

73-årig mand med slidforandringer i cervikal columna

Yngre til sammenligning

Yngre til sammenligning

Yngre person til sammenligning

Spinalkanalen

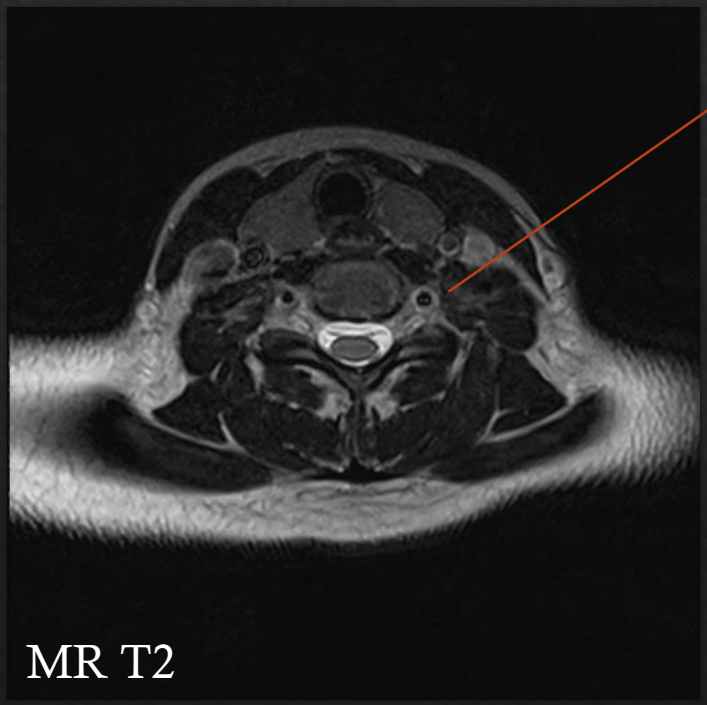

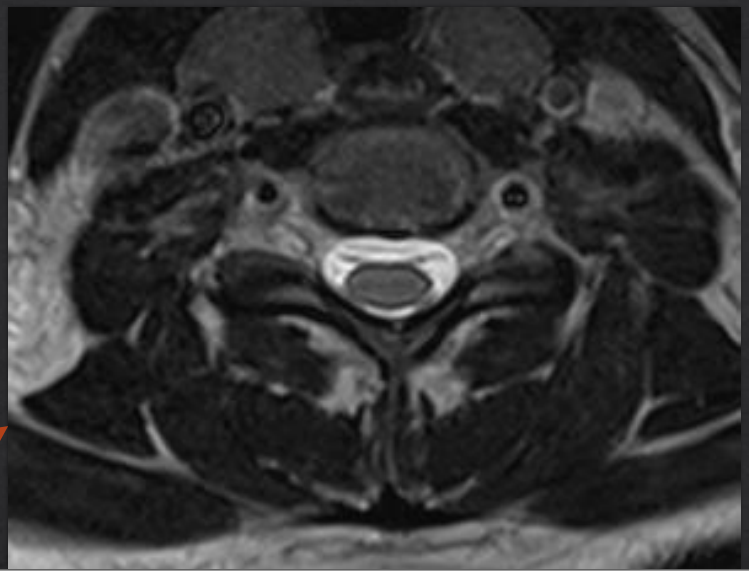

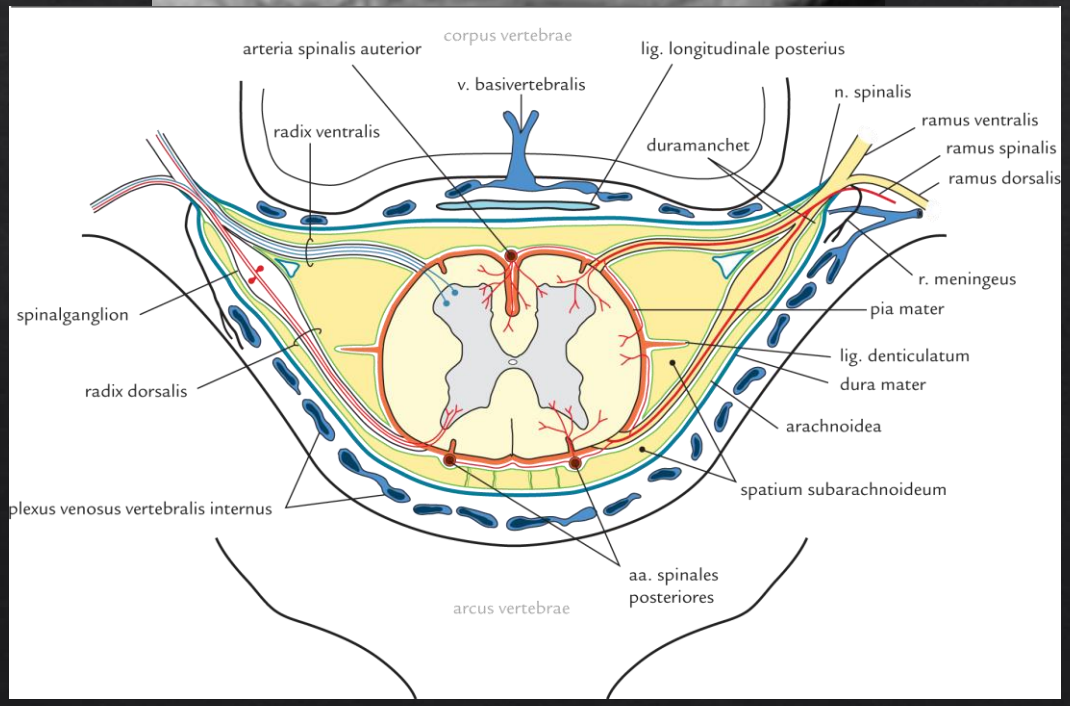

MR af columna cervicalis

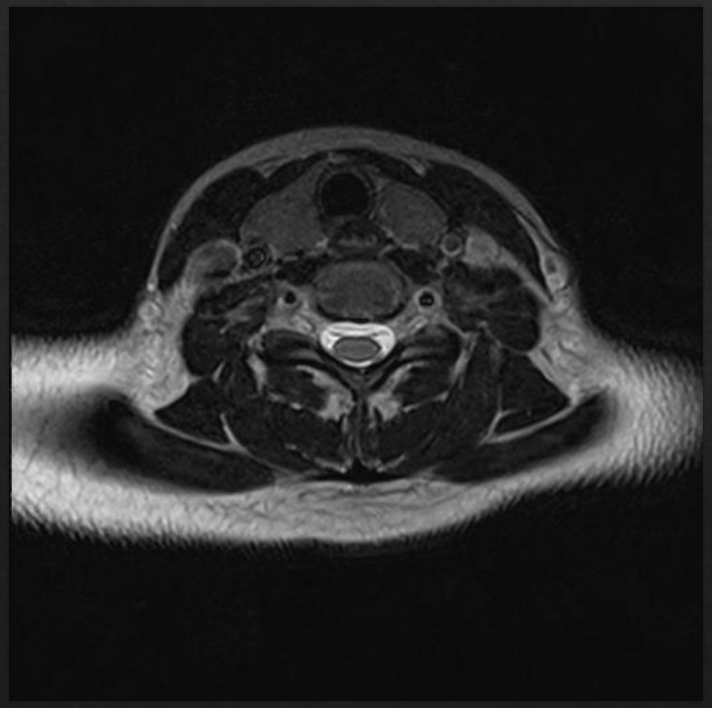

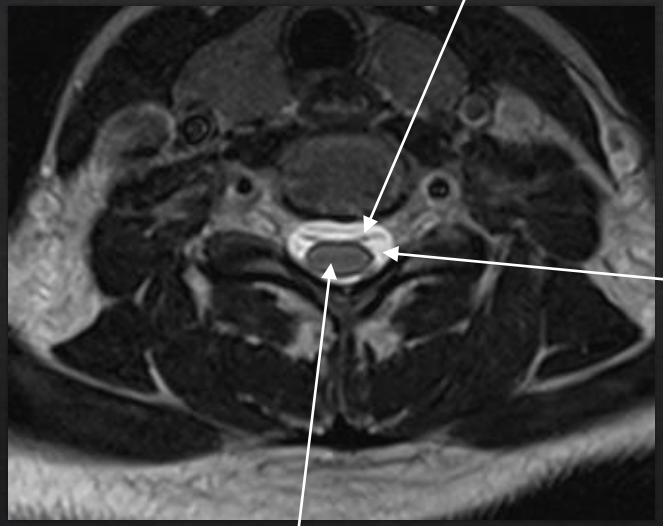

- Cervical discus prolaps

Cervical discus prolaps

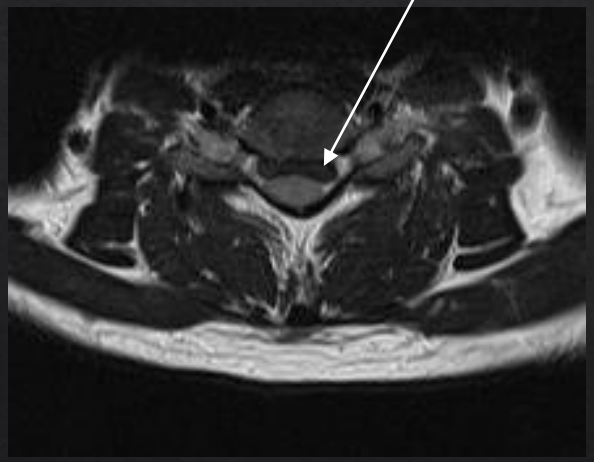

Cervical discus prolaps

De følgende MR snit er lavet som skrå frontale snit, se billedet til højre.

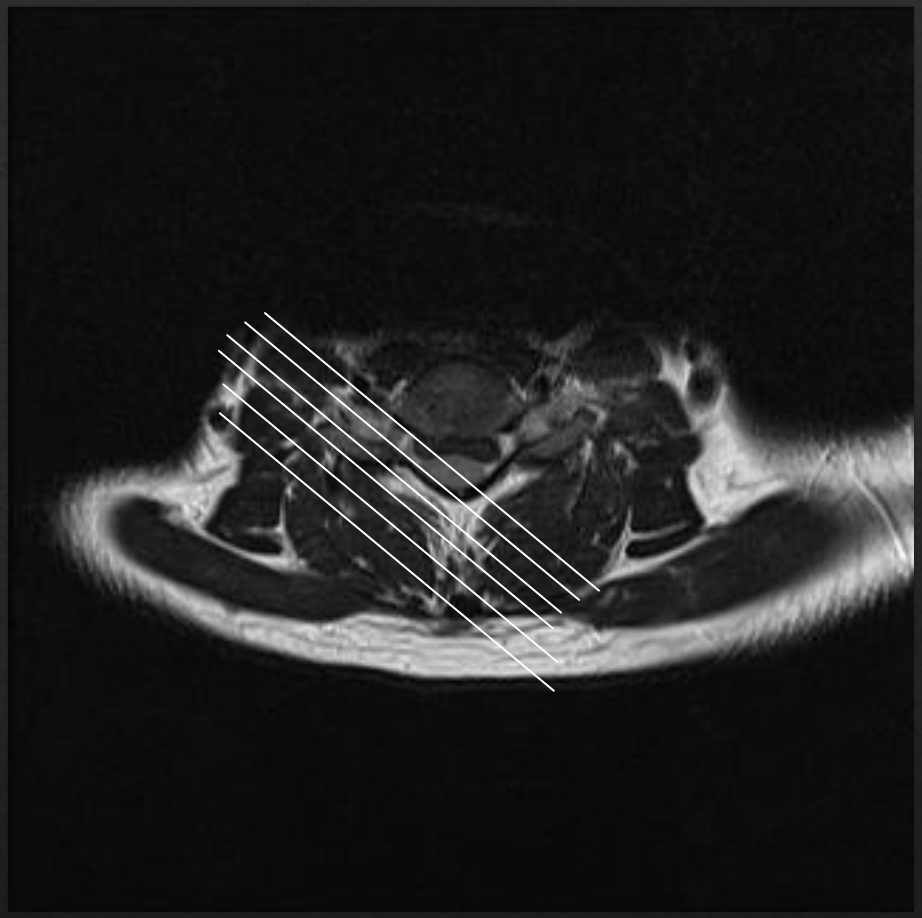

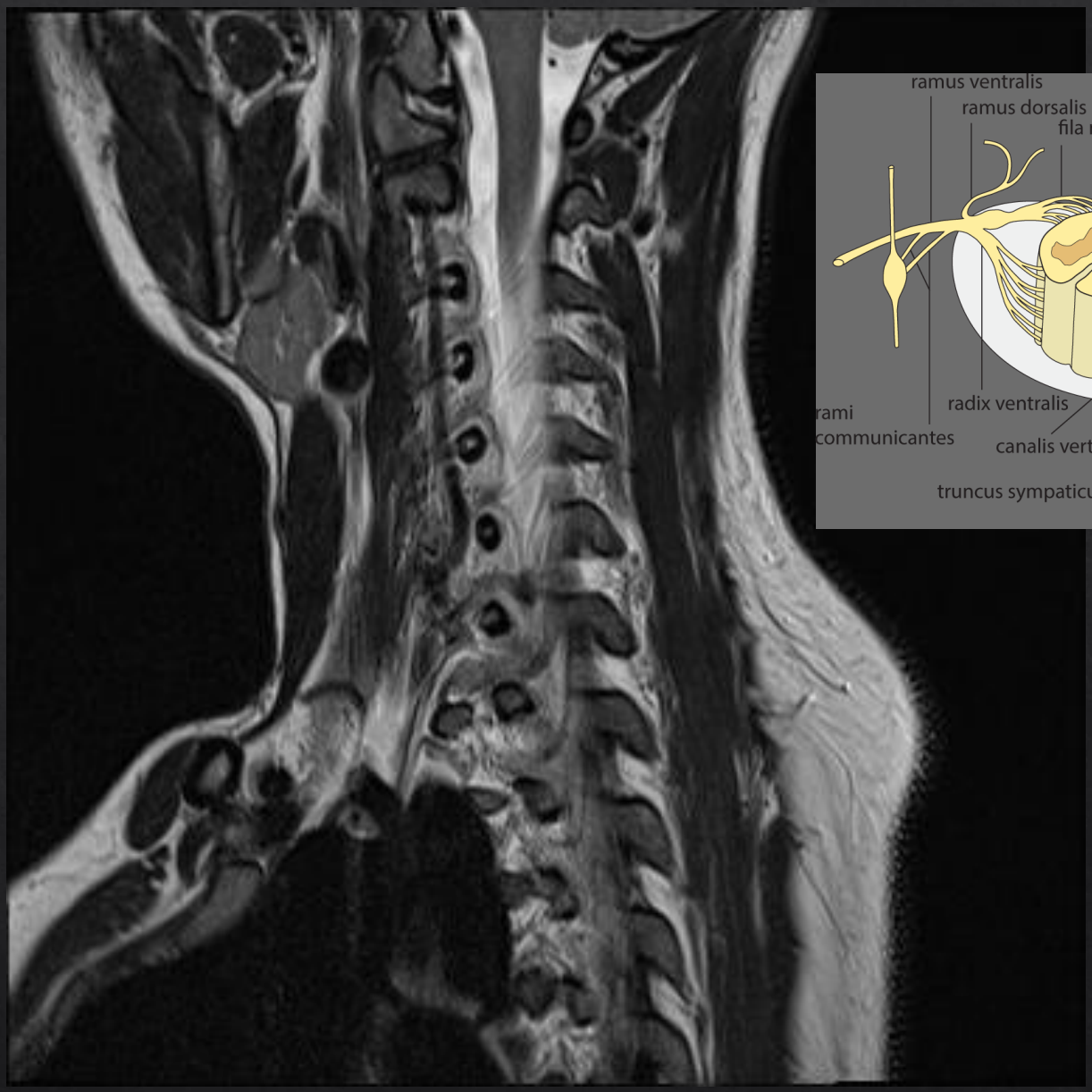

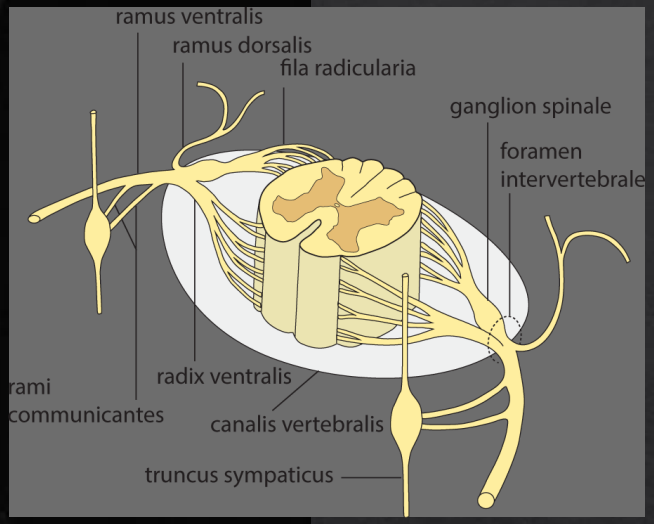
ramus ventralis
ramus dorsalis
fila radicularia
ganglion spinale
foramen
intervertebrale
radix ventralis
rami
communicantes
canalis vertebralis
truncus sympaticus


1
2
3
4

1. Cerebellum
2. Medulla spinalis
3. Liquor cerebrospinalis
4. Fila radicularia

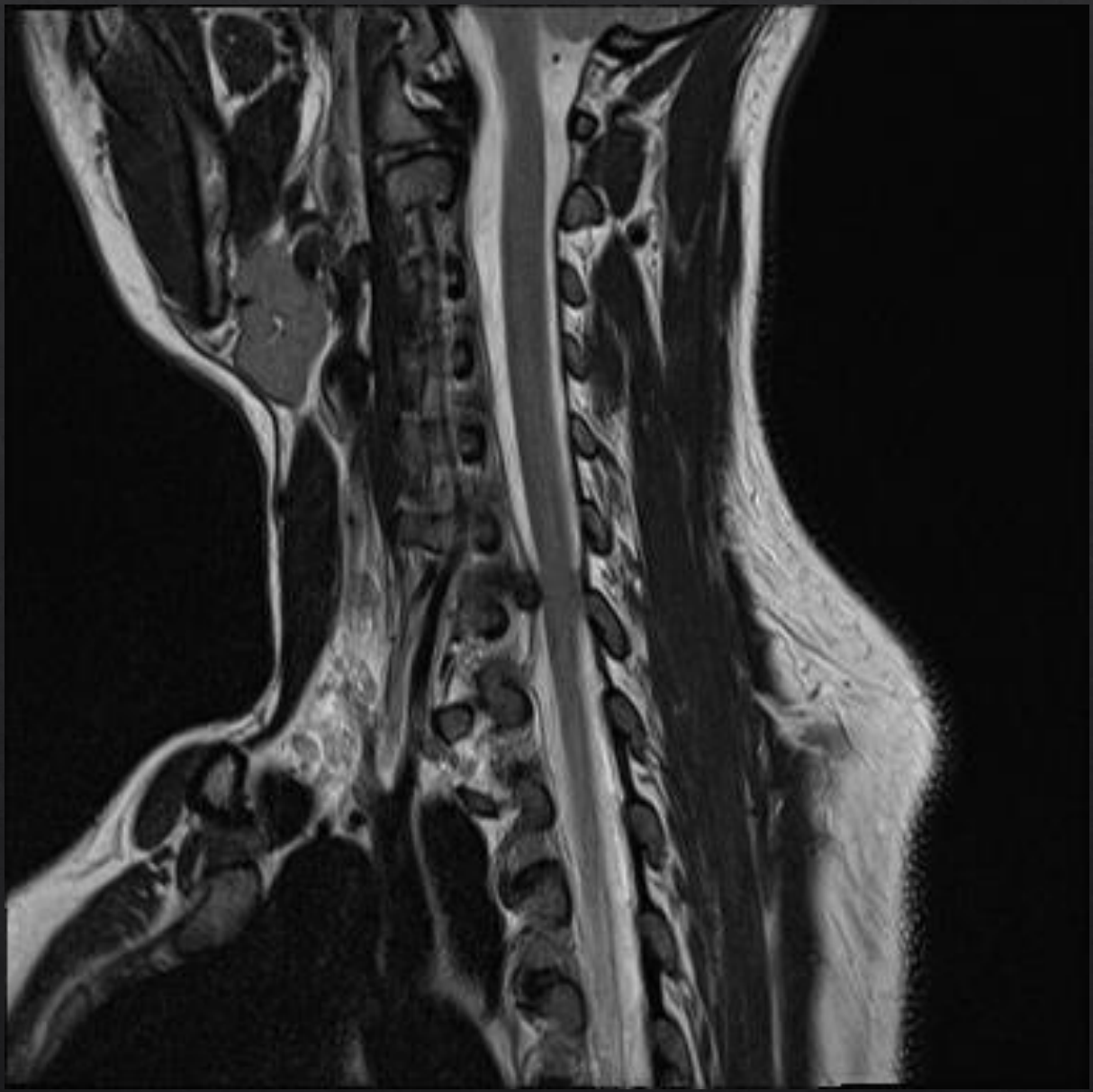

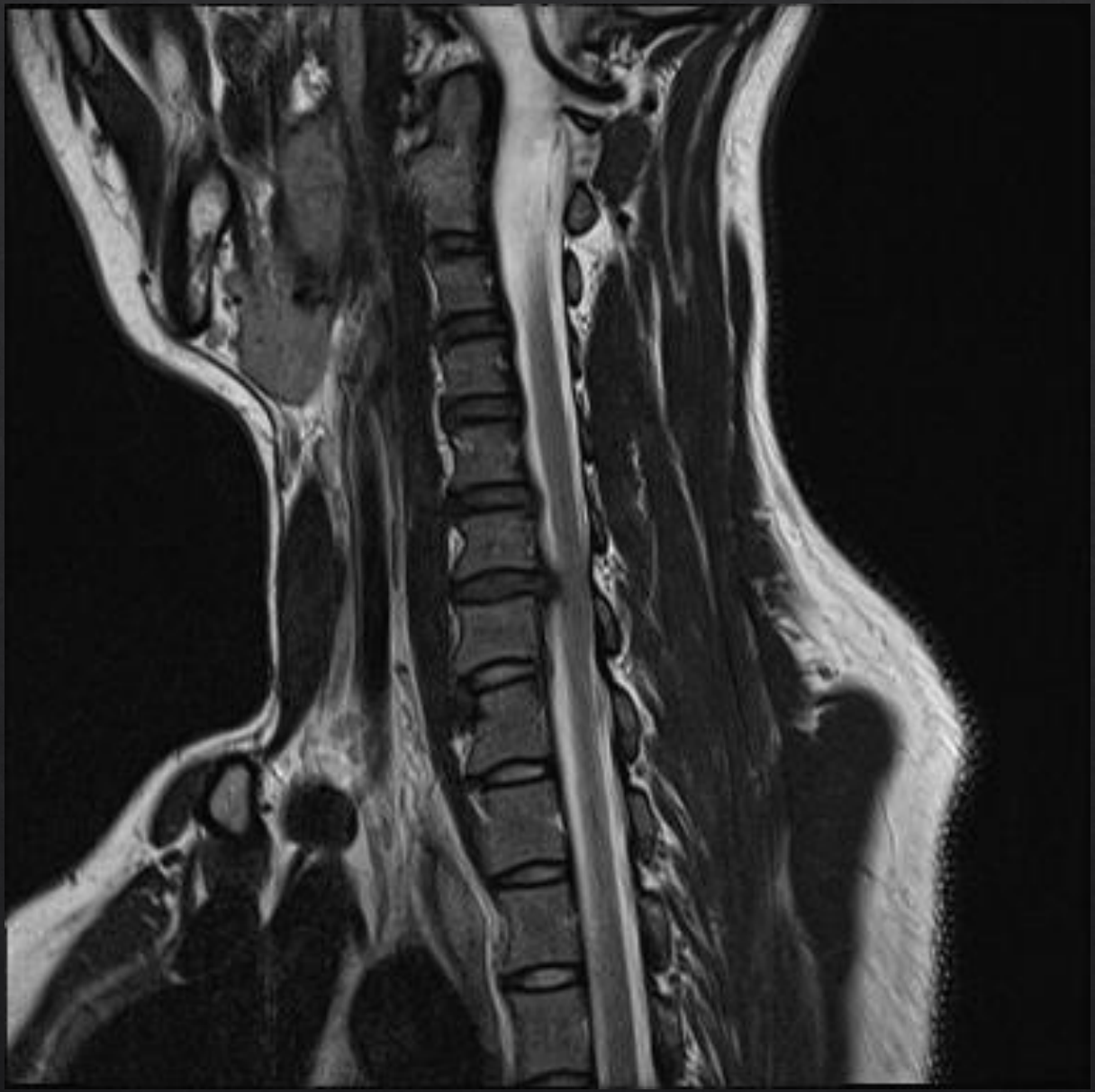


Discus prolaps

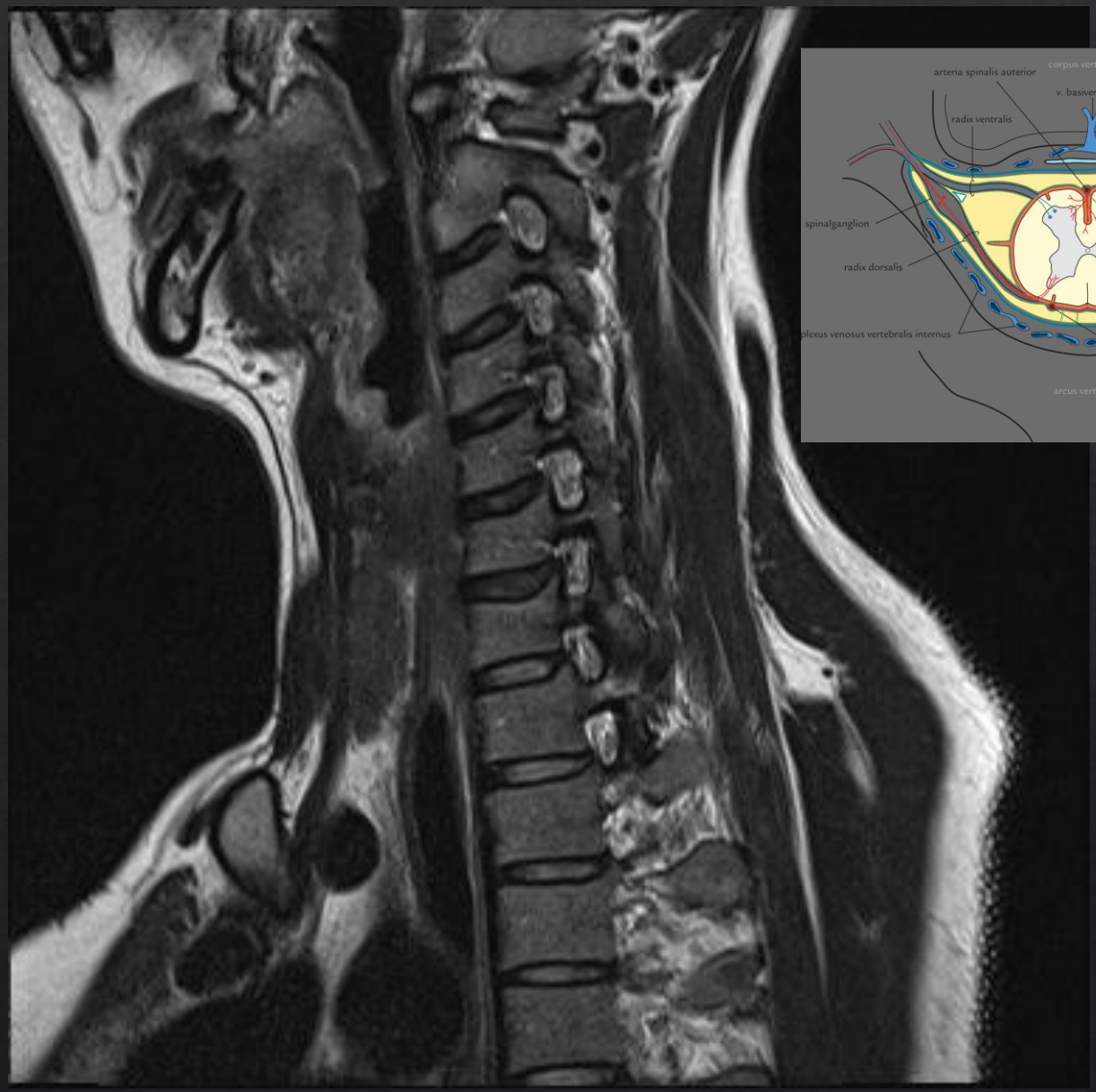

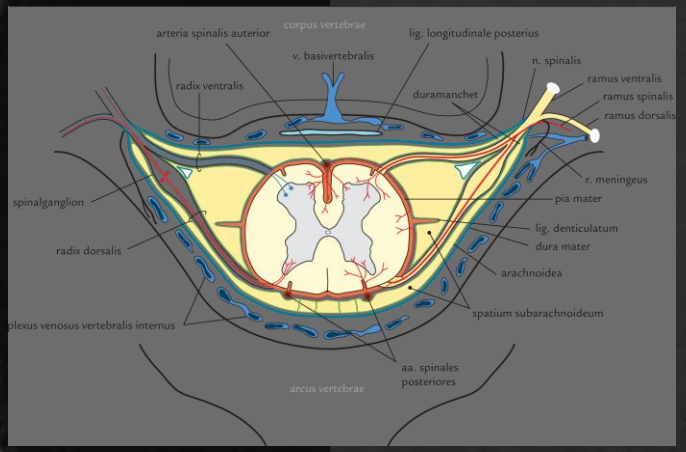
corpus vertebrae
arteria spinalis auterior
lig. longitudinale posterius
v. basivertebralis
n. spinalis
ramus ventralis
ramus spinalis
ramus dorsalis
radix ventralis
duramanchet
r. meningeus
spinalganglion
pia mater
lig. denticulatum
dura mater
radix dorsalis
arachnoidea
spatium subarachnoideum
plexus venosus vertebralis internus
aa. spinales posteriores
arcus vertebrae

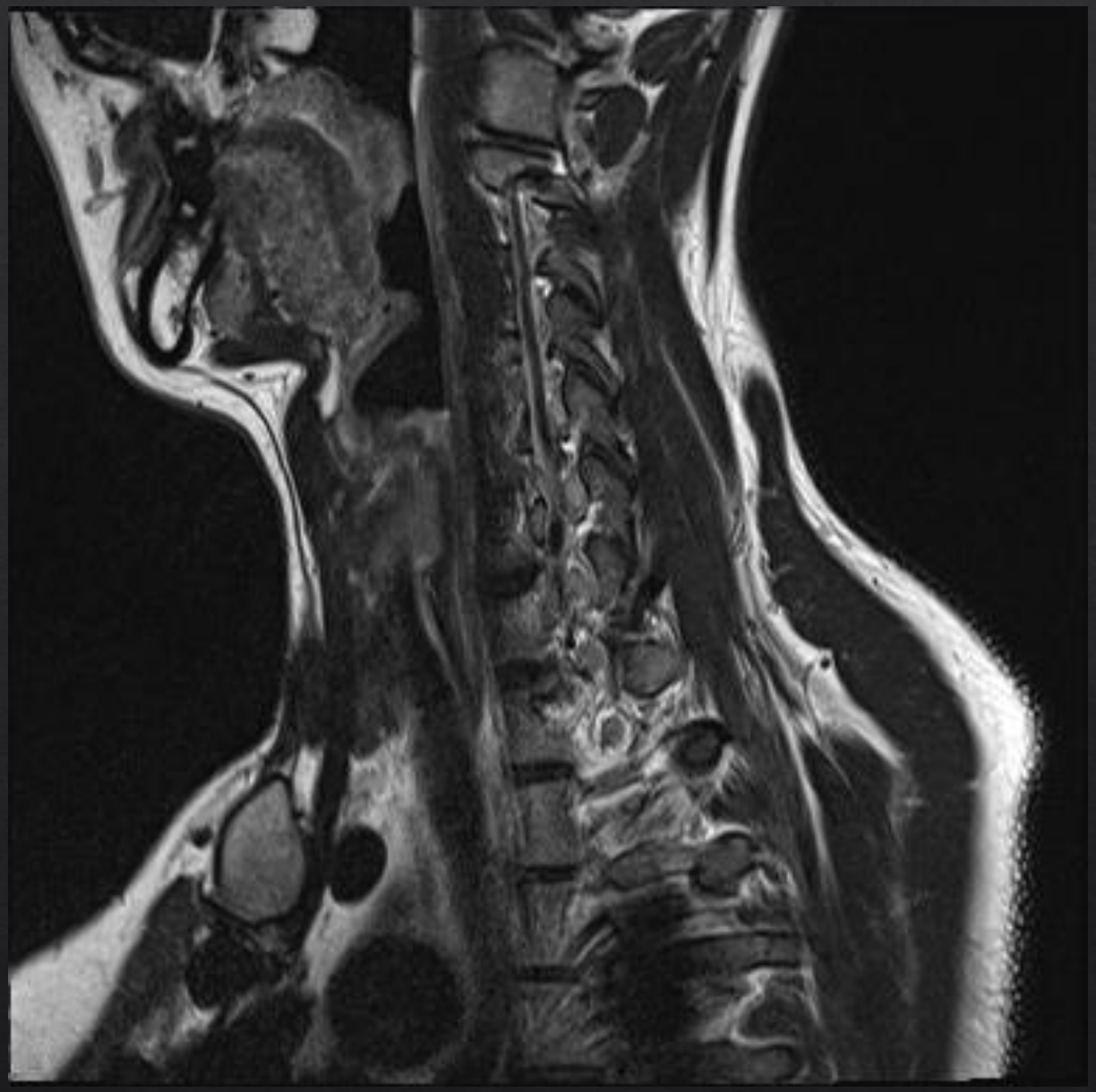

Cervikal discusprolaps på niveau C5/6

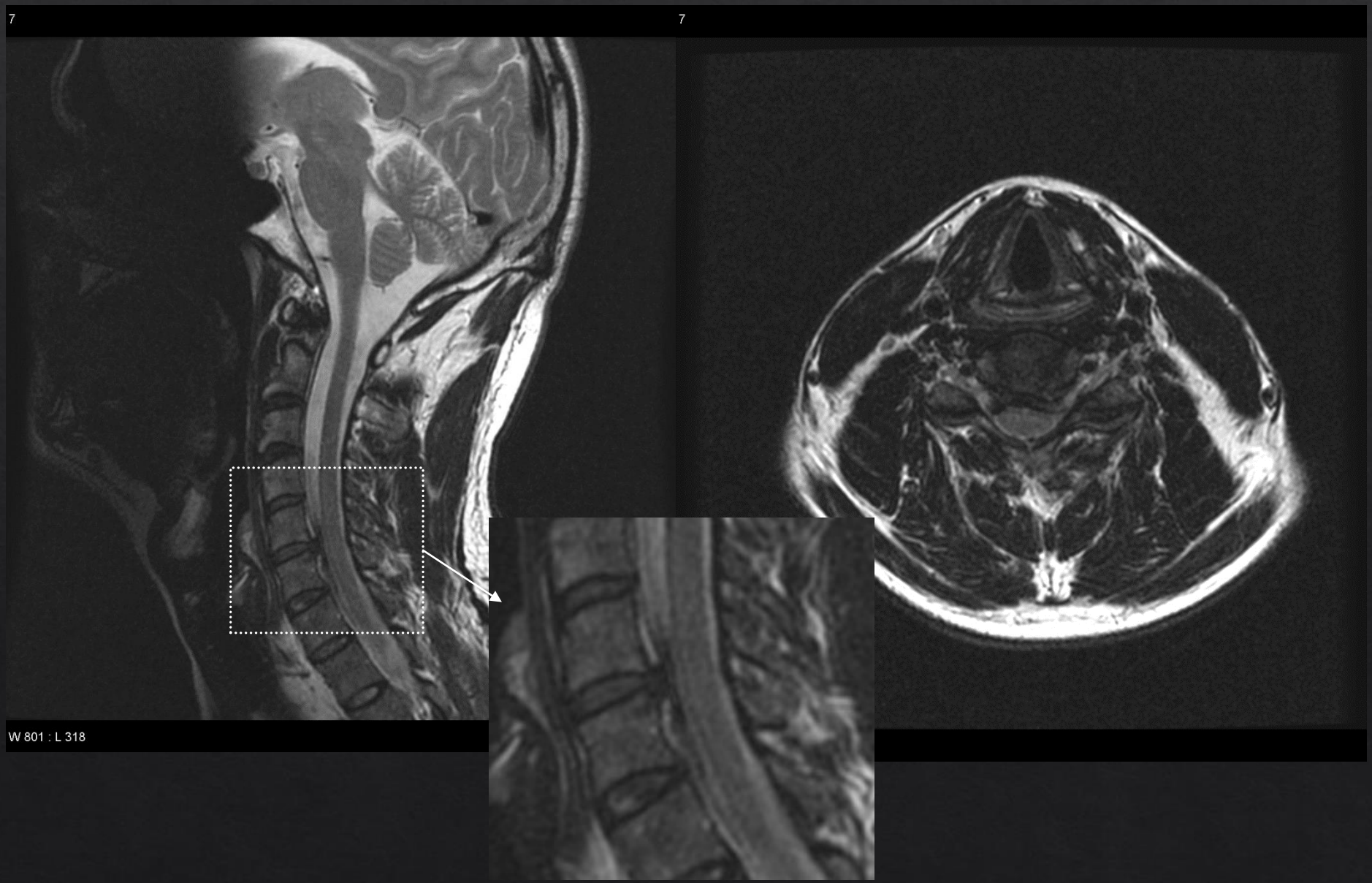

Cervikal discusprolaps på niveau C5/6

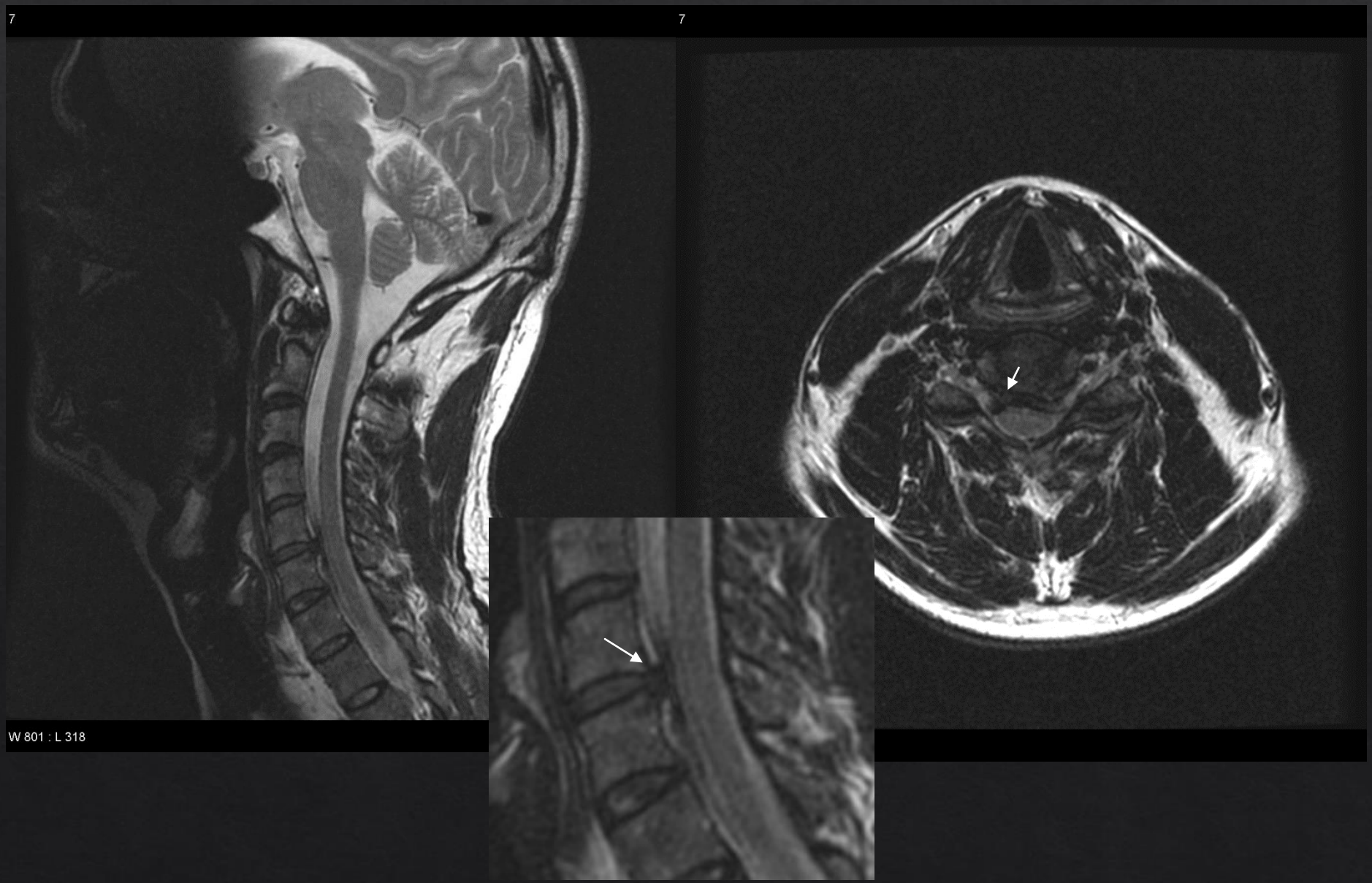

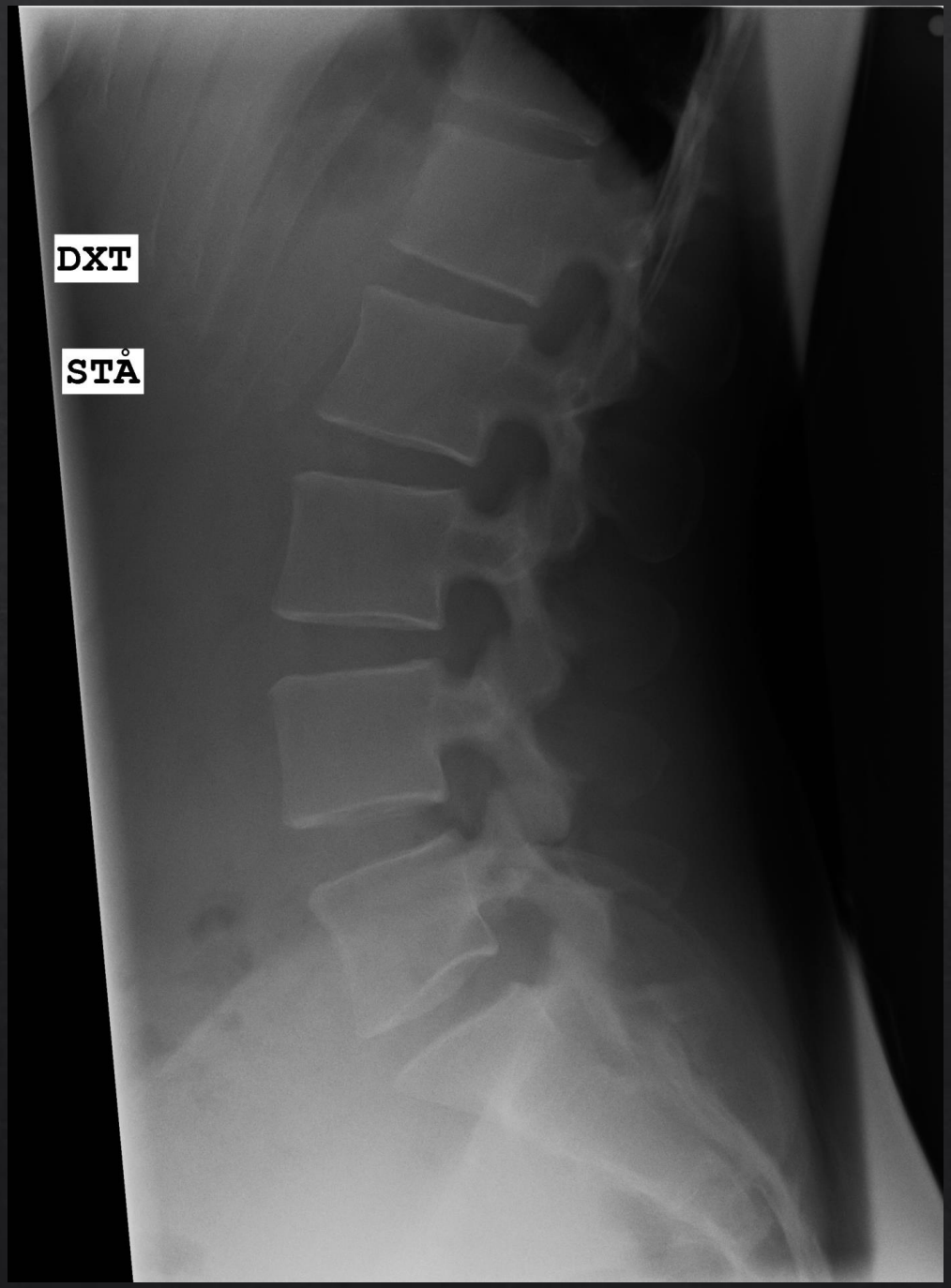
DXT
STÅ

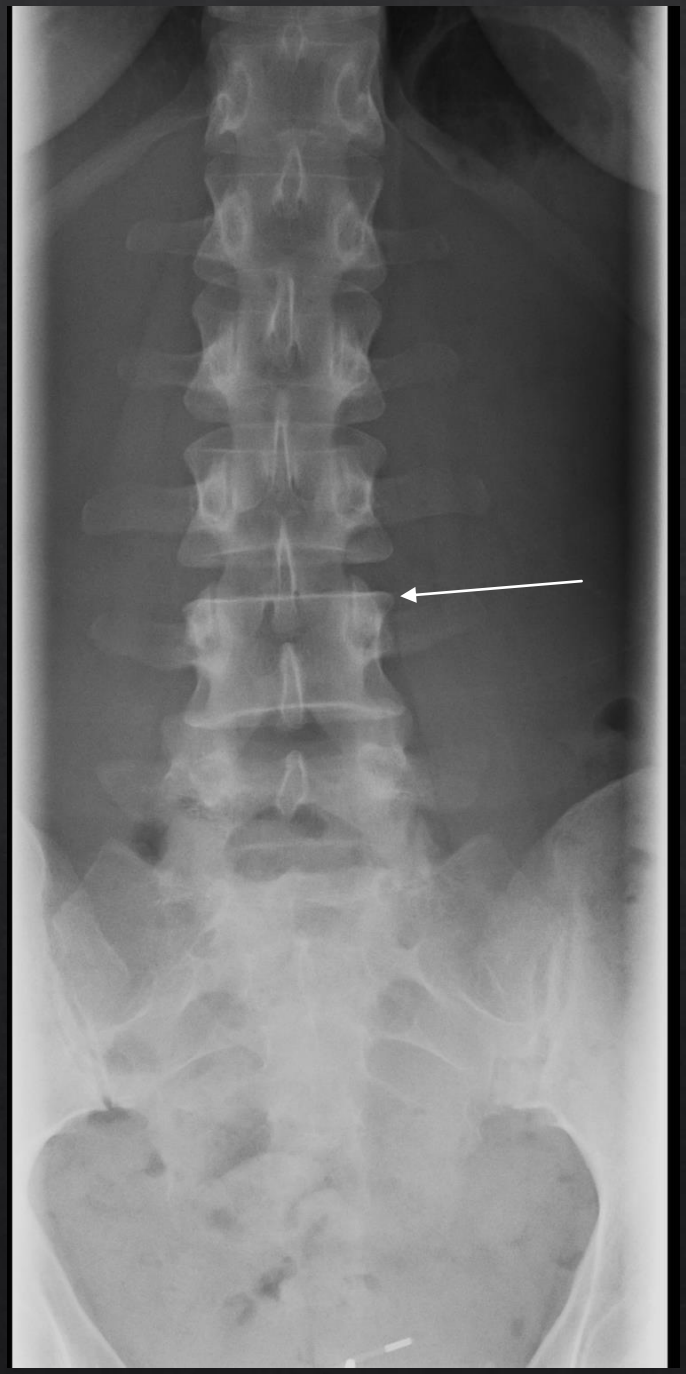

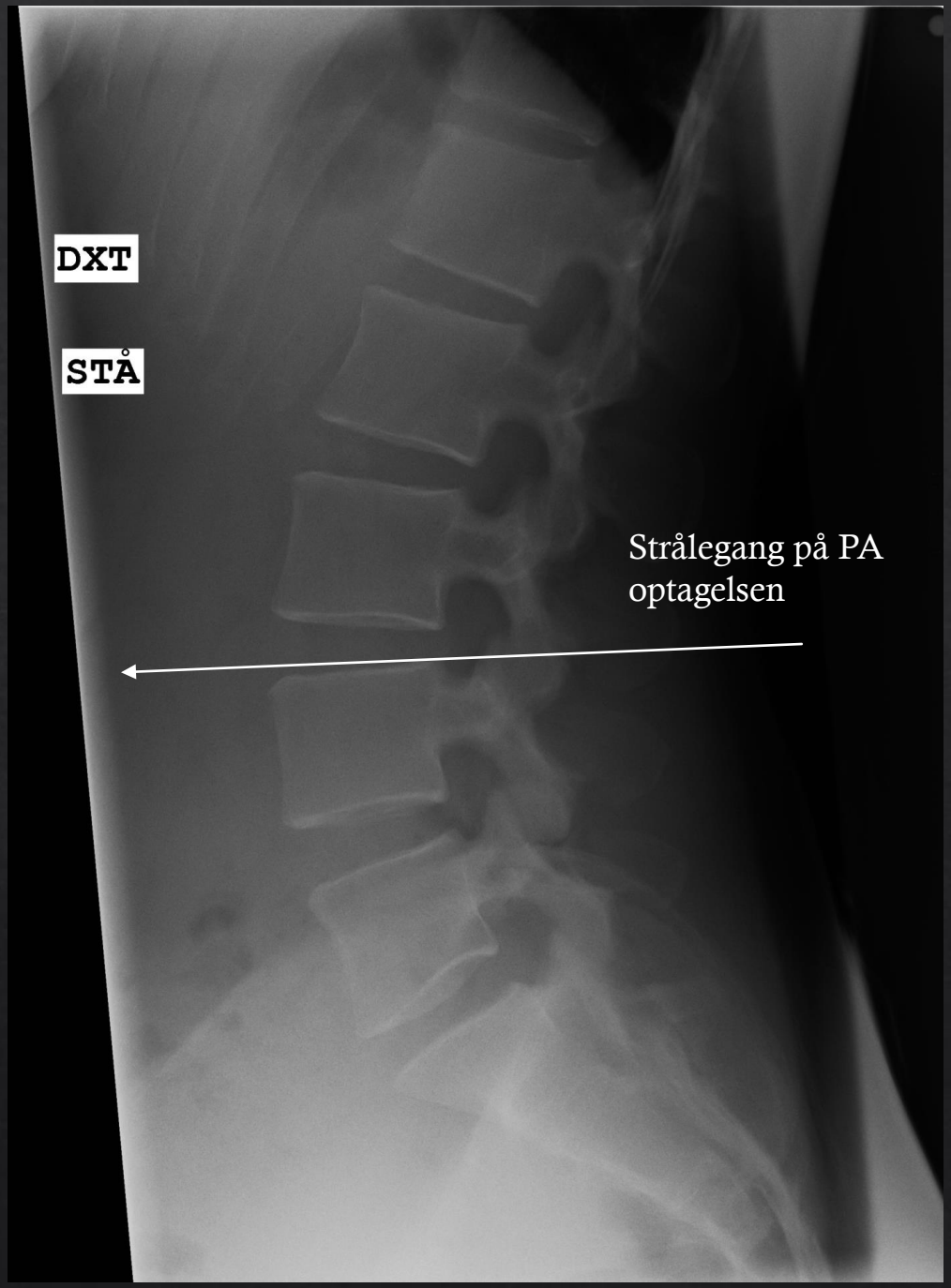
DXT
STÅ
Strålegang på PA
optagelsen


DXT
STÅ

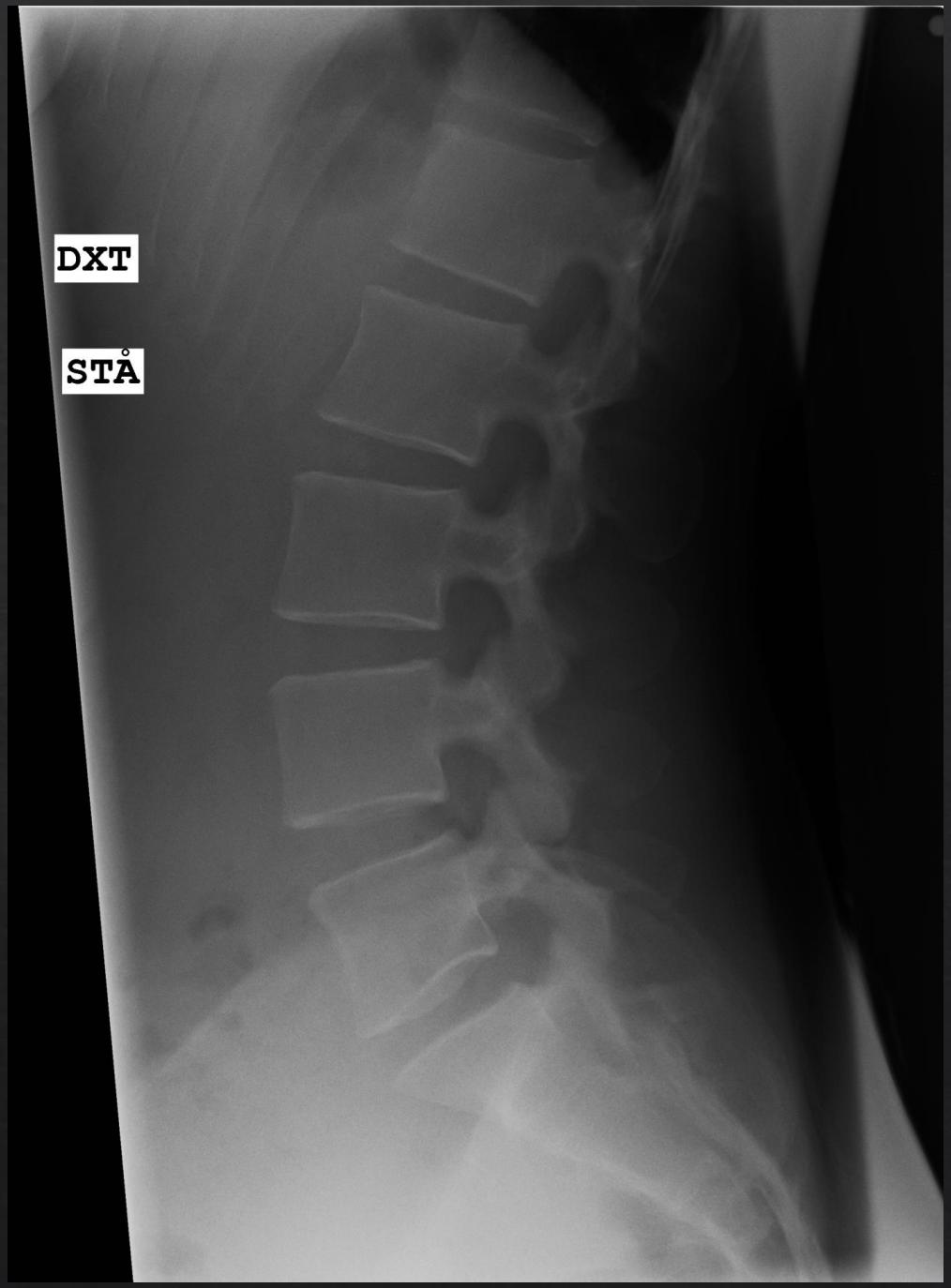
DXT
STÅ

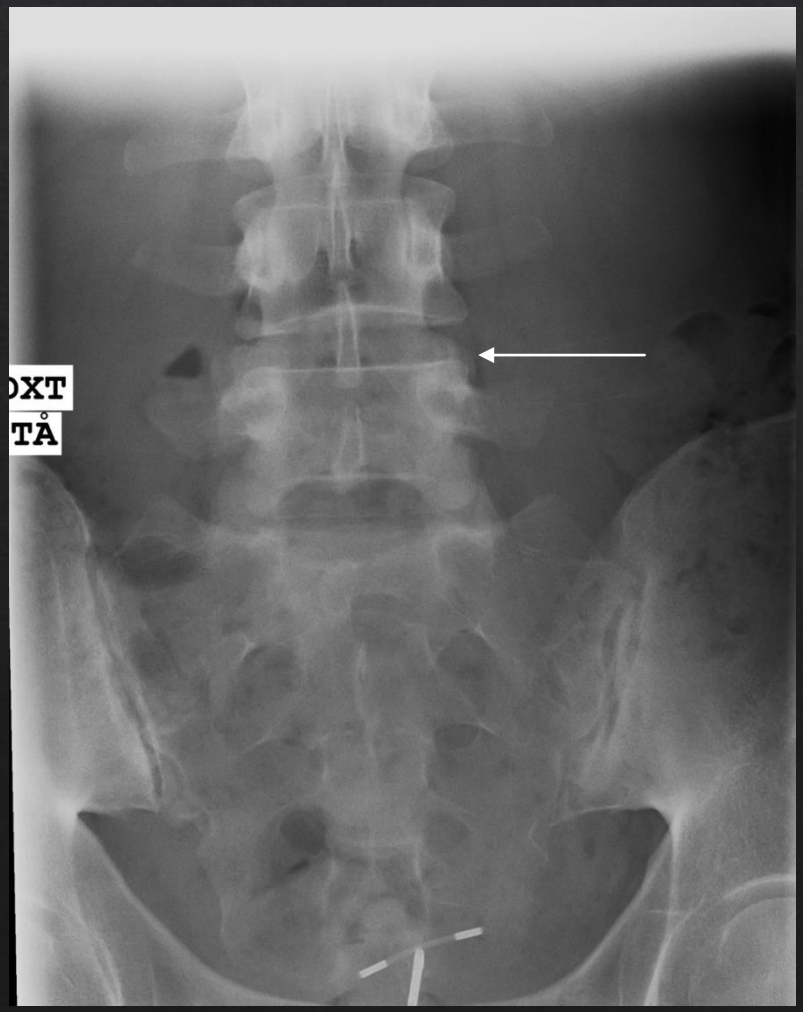
DXT
STÅ

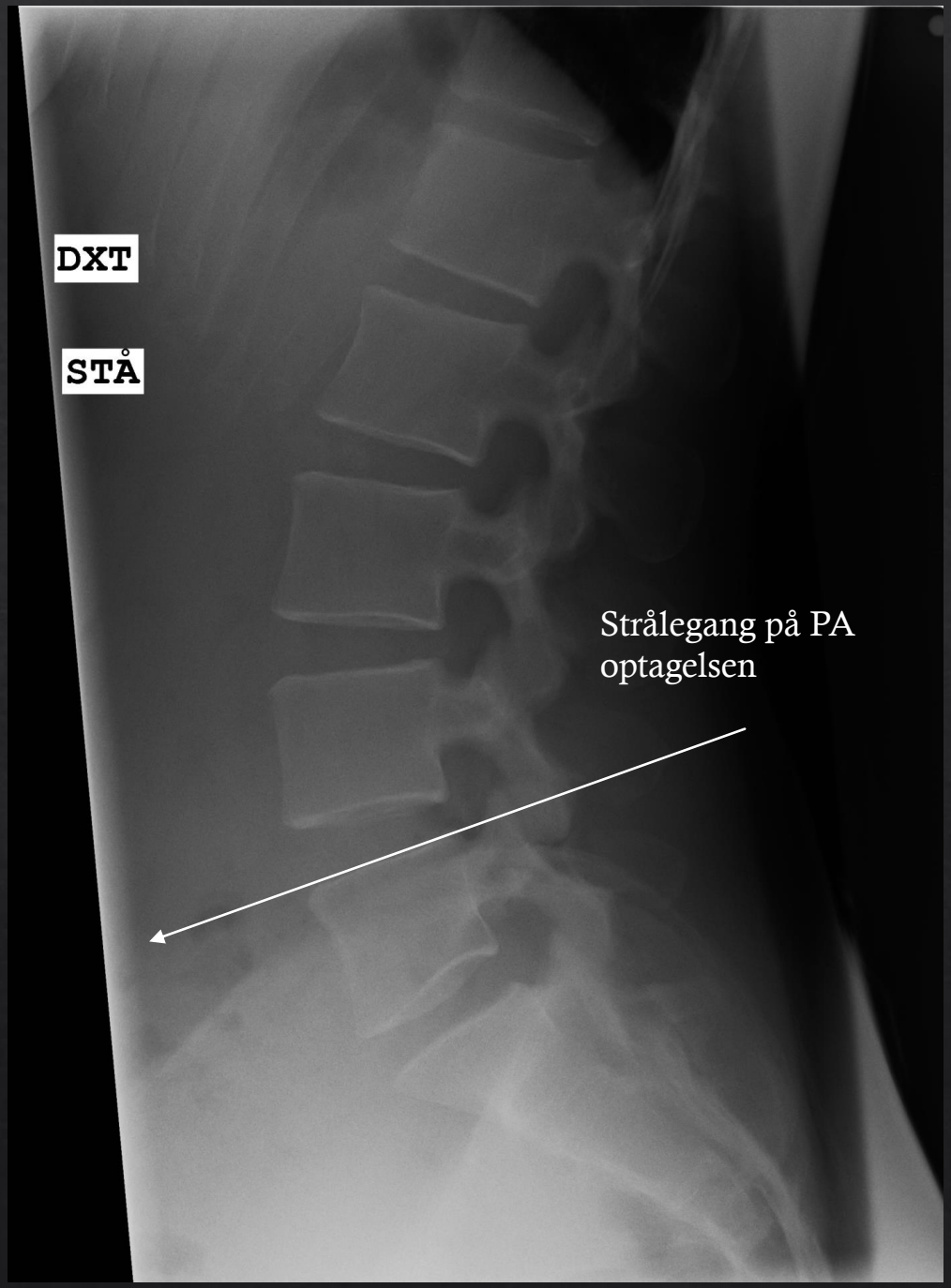
DXT
STÅ
Strålegang på PA
optagelsen

Lumbosakral overgangshvirvel


DXT

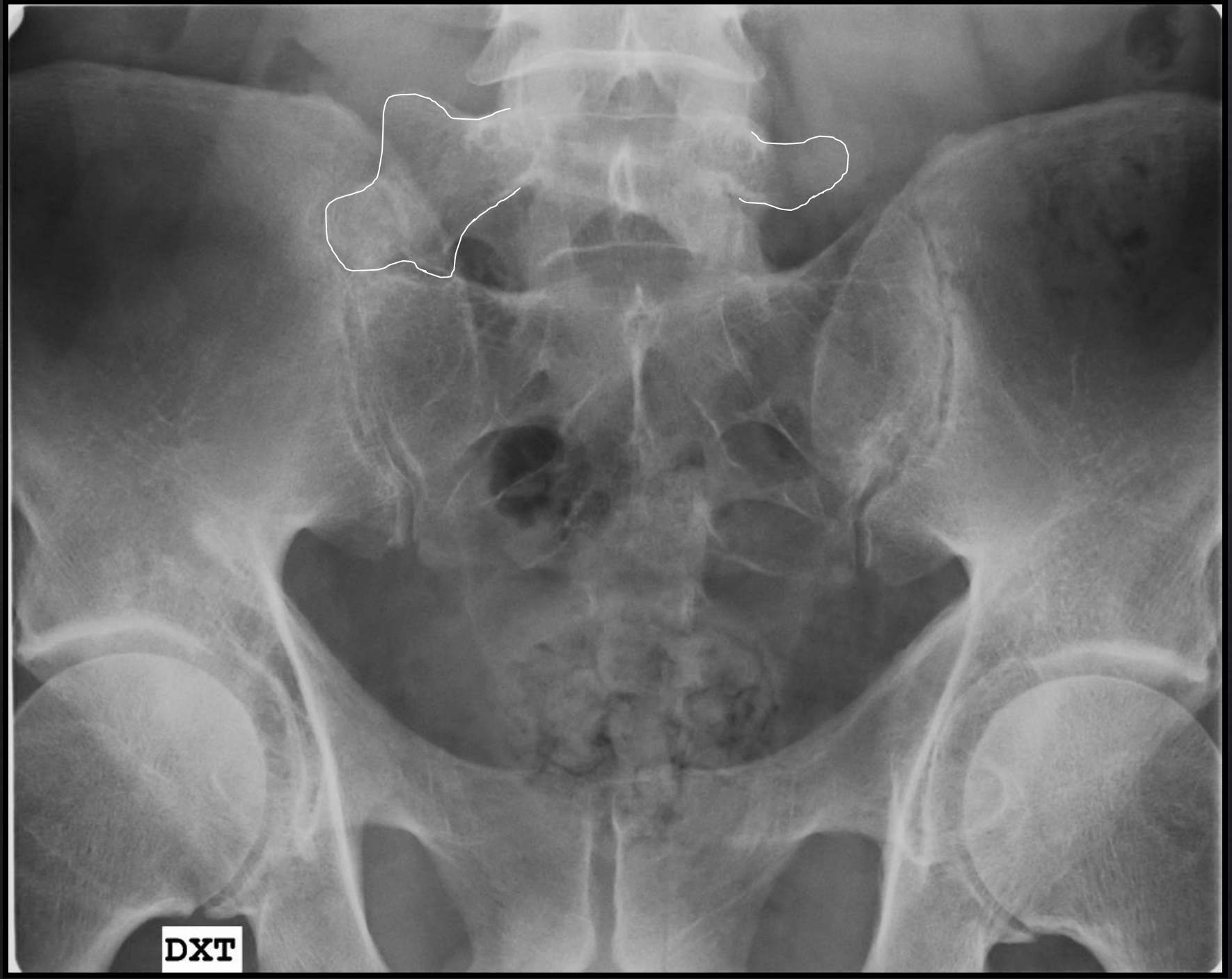
DXT

Columnas blodforsyning

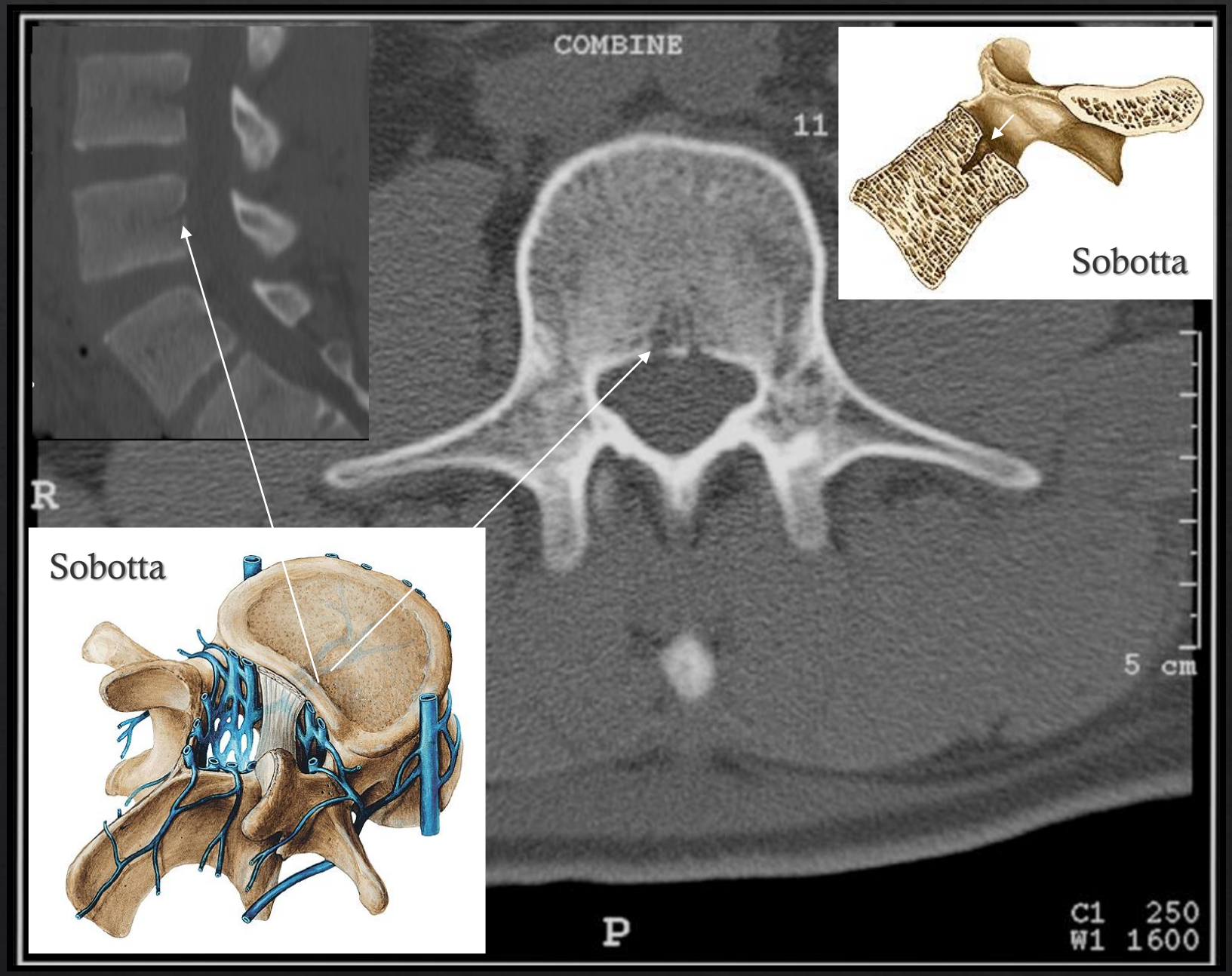
COMBINE
11
R
P
5 cm
C1 250
W1 1600
Sobotta
Sobotta

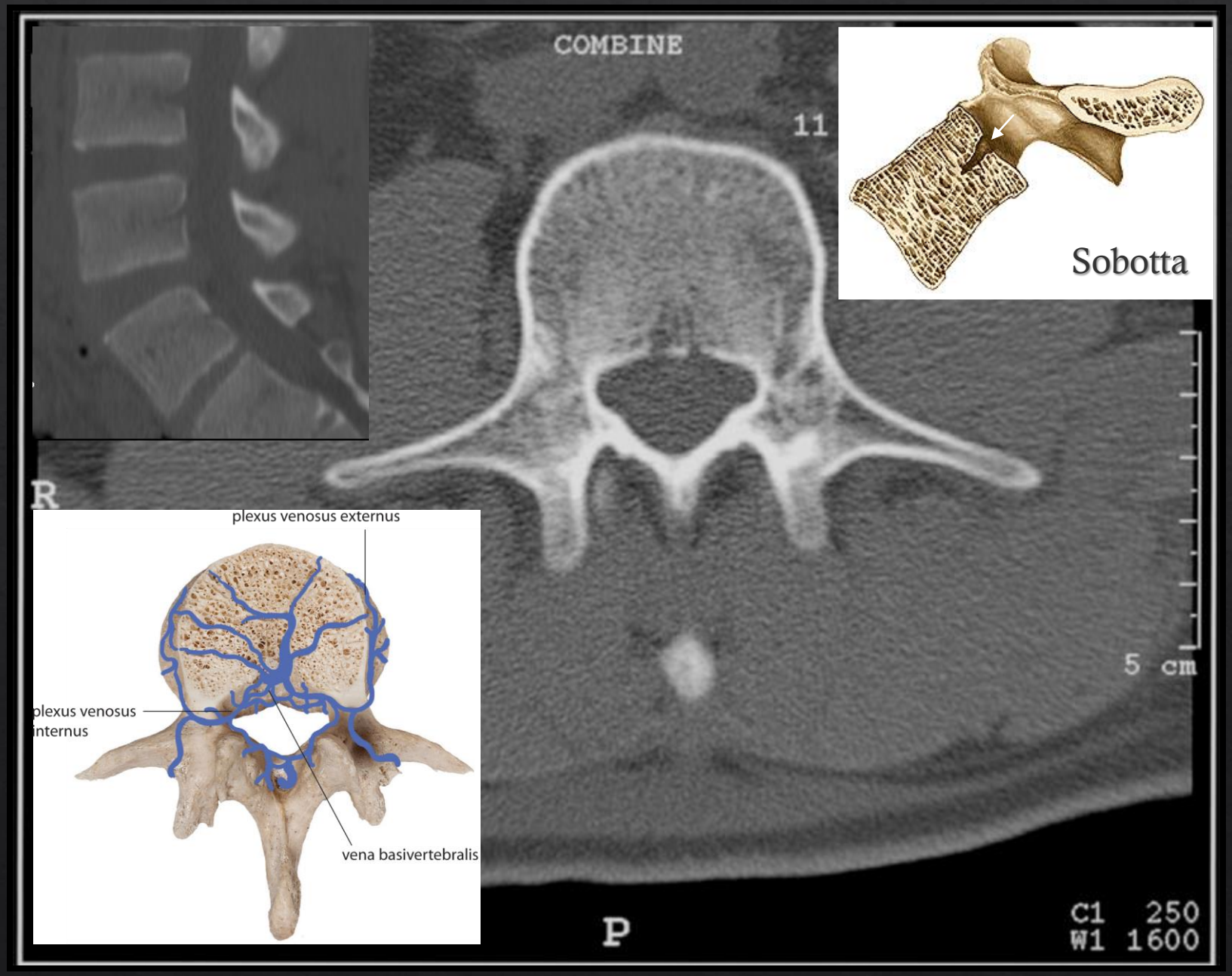
COMBINE
11
R
P
5 cm
C1 250
W1 1600
Sobotta
plexus venosus externus
plexus venosus
internus
vena basivertebralis

Ældre kvinde med smerter på thorakolumbale overgang.


SIN
AP
STÅ


DXT
STÅ

Osteolytisk metastase

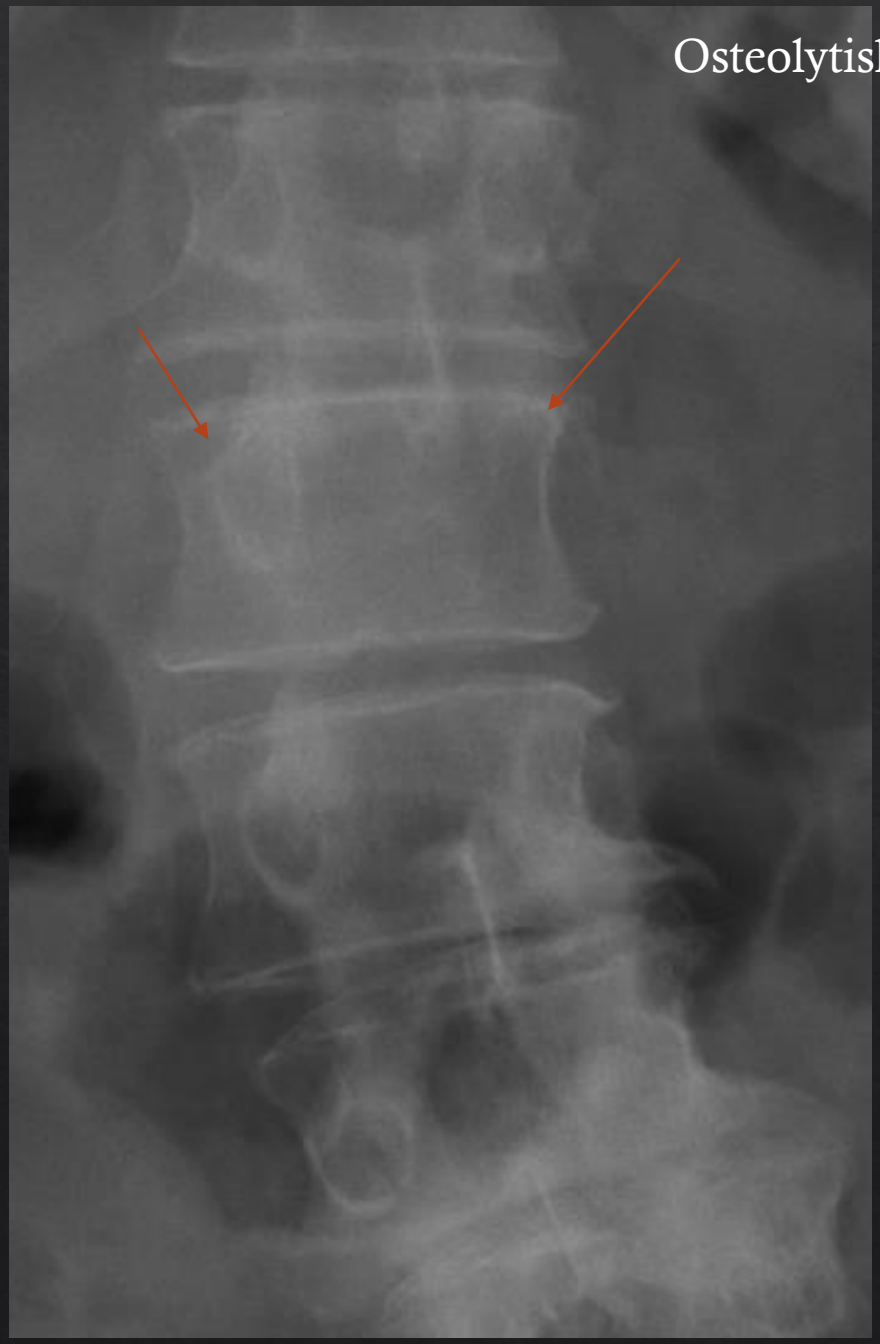

Knoglemarven

T1: TR og TE kort

T2: TR og TE lang

STIR: Fedt suppression

Yngre barn

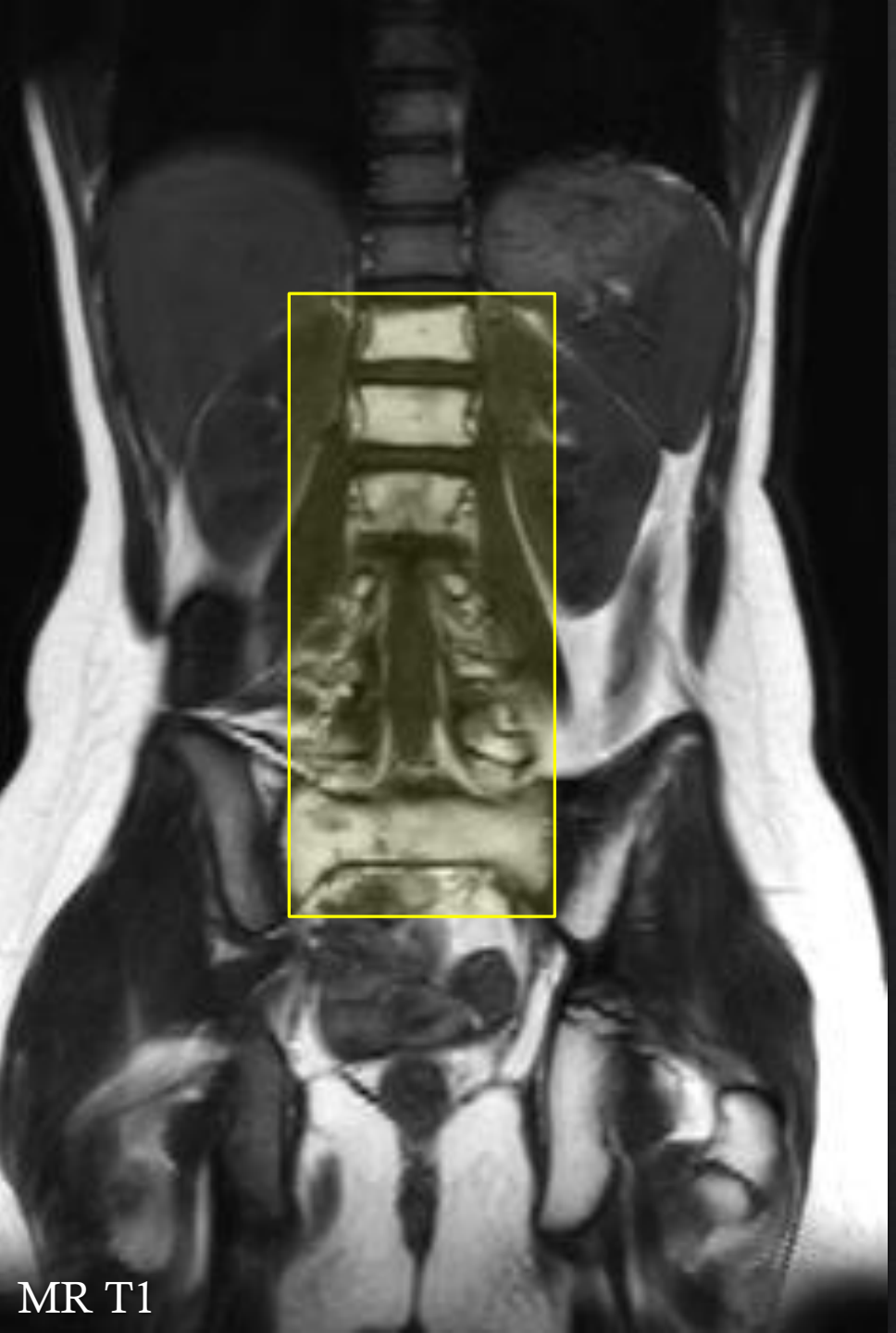

Yngre barn

- Følger efter strålebehandling, med konvertering af rød knoglemarv til gul knoglemarv. (Det hæmopoietiske væv går til grunde).

Patologisk knoglemarv

Marvinfiltration

Metastaser (fjern spredning af kræft):
Marvinfiltration (Svulstcellerne ligger fokalt i knoglemarven)
Osteolyse (Påvirkning af knoglevævet der fokalt forsvinder)
Osteosklerose (Påvirkning af knoglevævet, der fokalt øges i tæthed)

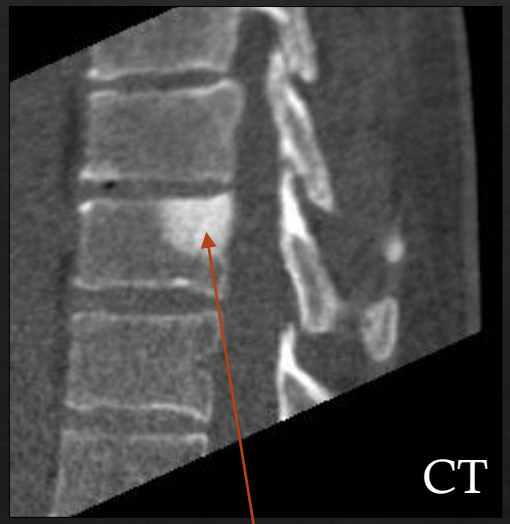

Osteosklerotisk metastase

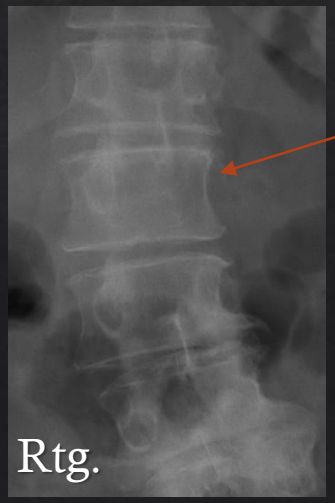

Osteolytisk metastase (pediklet på venstre side er forsvundet)

Bløddelene

Discus intervertebralis

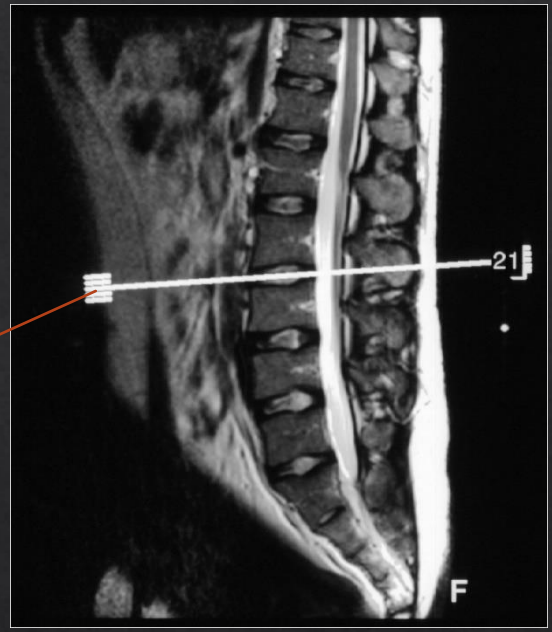

Snit lige gennem lumbal discus
(MR T2)

Bevægeapparatets
anatomi

Medulla spinalis
Conus medullaris
Cauda equina
Liquor cerebrospinalis
Ligg. supraspinalia
Ligg. interspinalia
Ligg. flava
Lig. longitudinale ant.
Lig. longitudinale post.
Discus intervertebralis

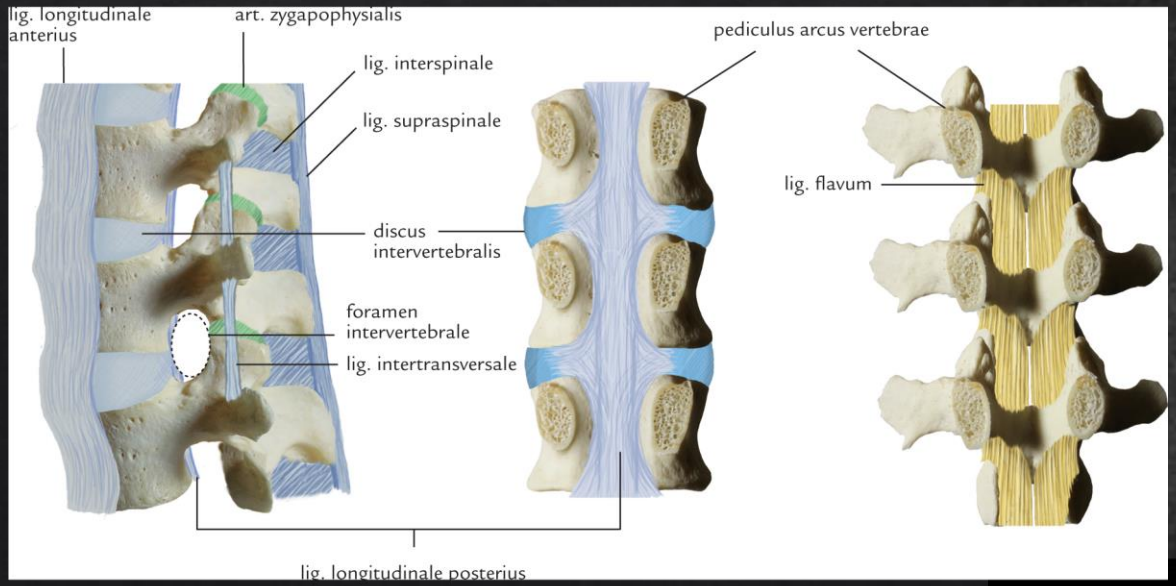


1
10
7
5
2
8
6
5
3
8
9
4

1) Medulla spinalis
2) Conus medullaris
3) Cauda equina
4) Liquor cerebrospinalis
5) Ligg. supraspinalia
6) Ligg. interspinalia
7) Ligg. flava
8) Lig. longitudinale ant.
9) Lig. longitudinale post.
10) Discus intervertebralis

Lumbalpunktur

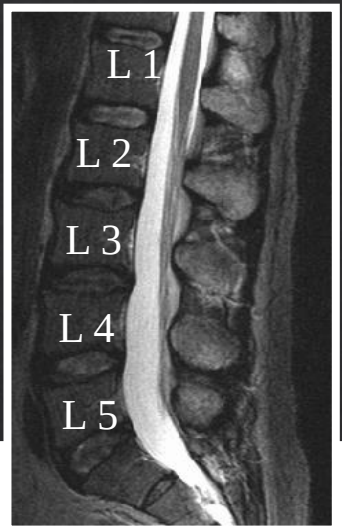
L 1
L 2
L 3
L 4
L 5

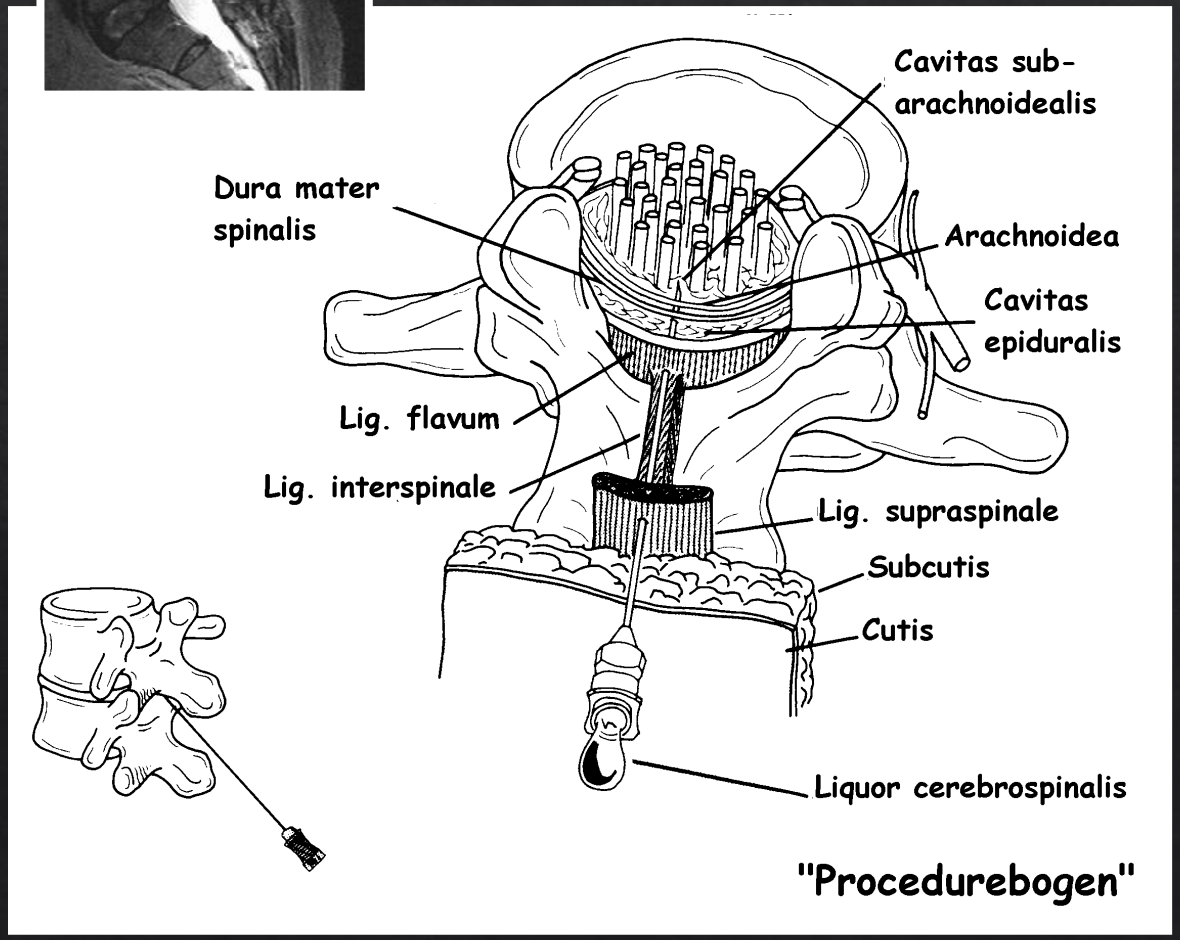
Cavitas sub-
arachnoidealis
Dura mater
spinalis
Arachnoidea
Cavitas
epiduralis
Lig. flavum
Lig. interspinale
Lig. supraspinale
Subcutis
Cutis
Liquor cerebrospinalis
"Procedurebogen"

Bughulens afgrænsninger.


Image 26
15:18:30
Scan 26
TP -415
ANTERIOR
RIGHT
TI 2*1
mA 165
kV 120
SL 10
GT 0
ZO 1.6
CE -7
0
AB 7555 oral
8-AUG-00
W 316
C 6
M -681

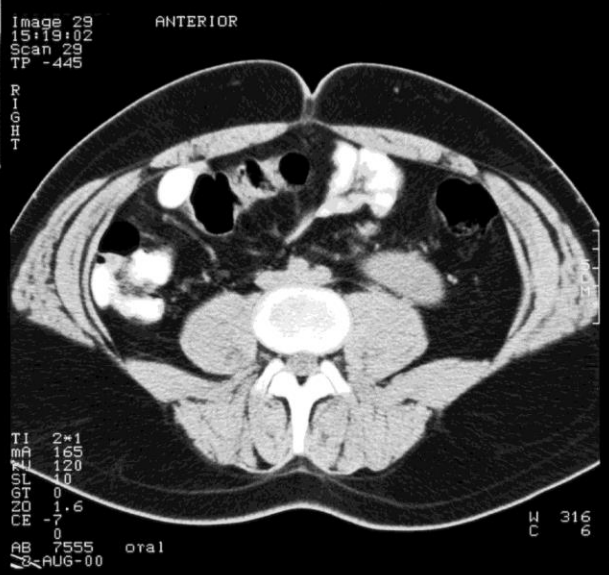
Image 29
15:19:02
Scan 29
TP -445
ANTERIOR
RIGHT
TI 2*1
mA 165
kV 120
SL 10
GT 0
ZO 1.6
CE -7
0
AB 7555 oral
8-AUG-00
W 316
C 6

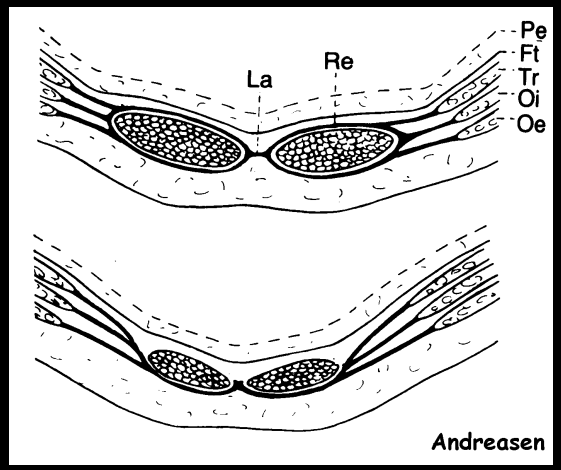
La
Re
Pe
Ft
Tr
Oi
Oe
Andreasen

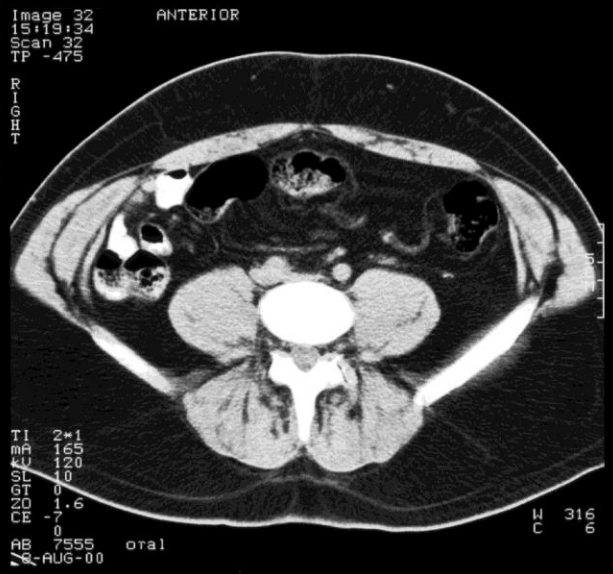
Image 32
15:19:34
Scan 32
TP -475
ANTERIOR
RIGHT
TI 2*1
mA 165
kV 120
SL 10
GT 0
ZO 1.6
CE -7
0
AB 7555 oral
8-AUG-00
W 316
C 6

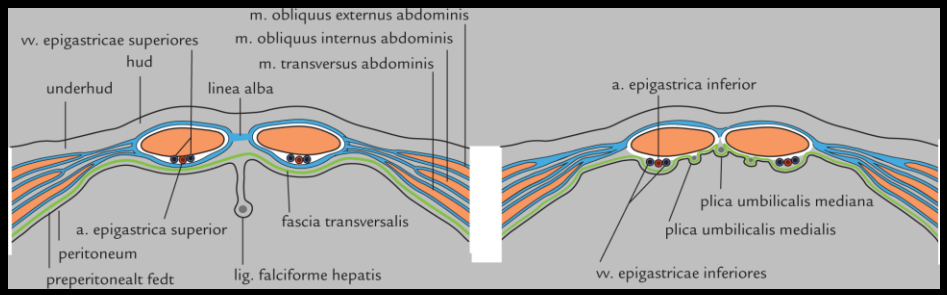
m. obliquus externus abdominis
vv. epigastricae superiores
m. obliquus internus abdominis
hud
m. transversus abdominis
underhud
linea alba
a. epigastrica inferior
plica umbilicalis mediana
plica umbilicalis medialis
a. epigastrica superior
fascia transversalis
peritoneum
preperitonealt fedt
lig. falciforme hepatis
vv. epigastricae inferiores

CT

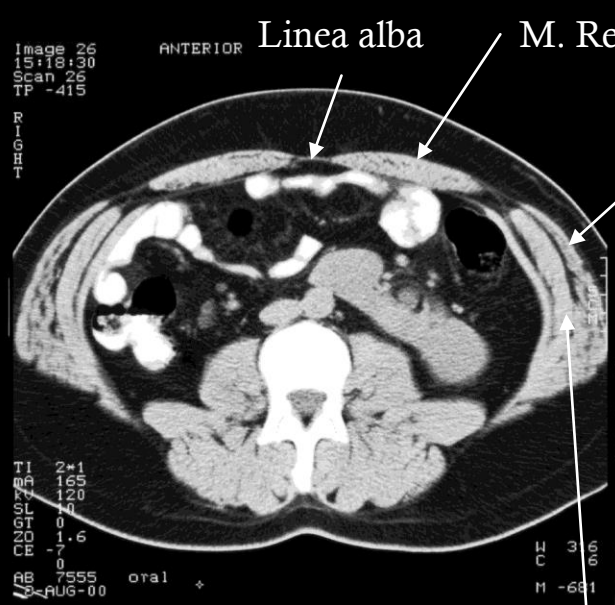

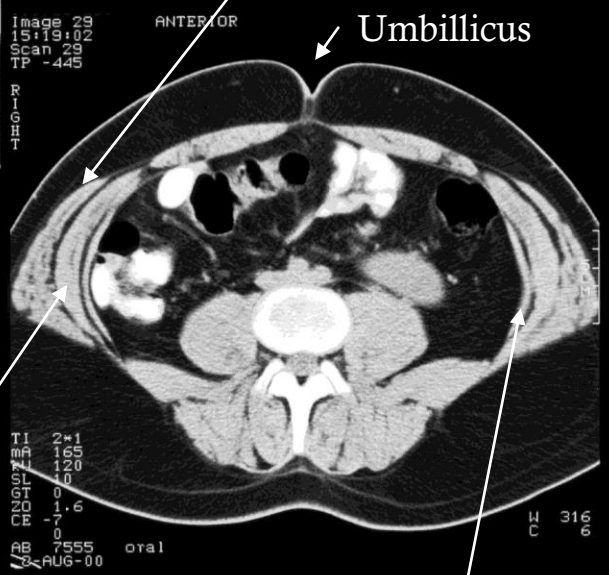

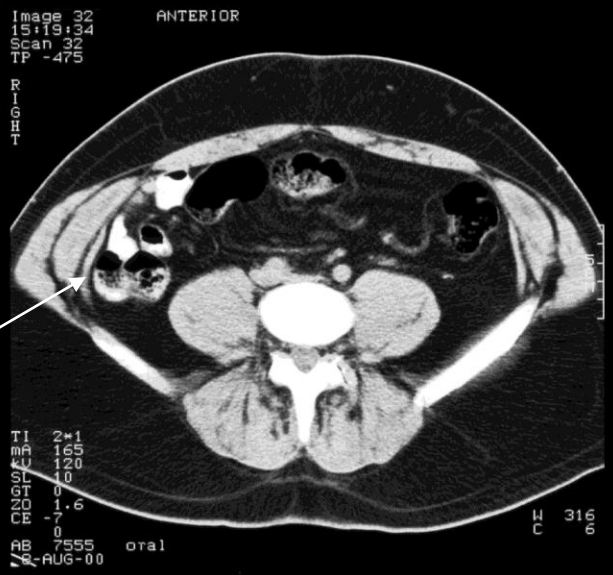

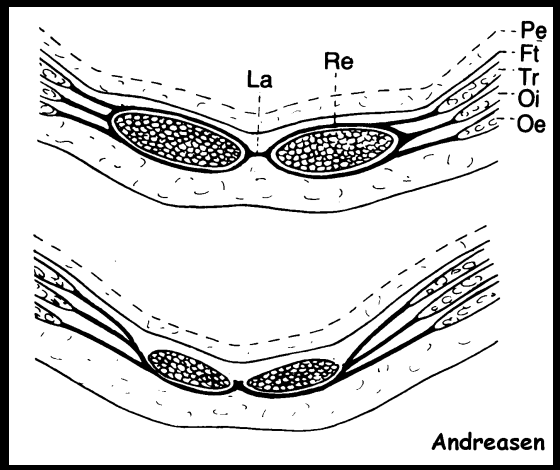

Linea alba

M. Rectus abdominis

M. obliquus externus abdominus

Umbillicus

M. obliquus internus abdominus

M. transversus abdominus

CT

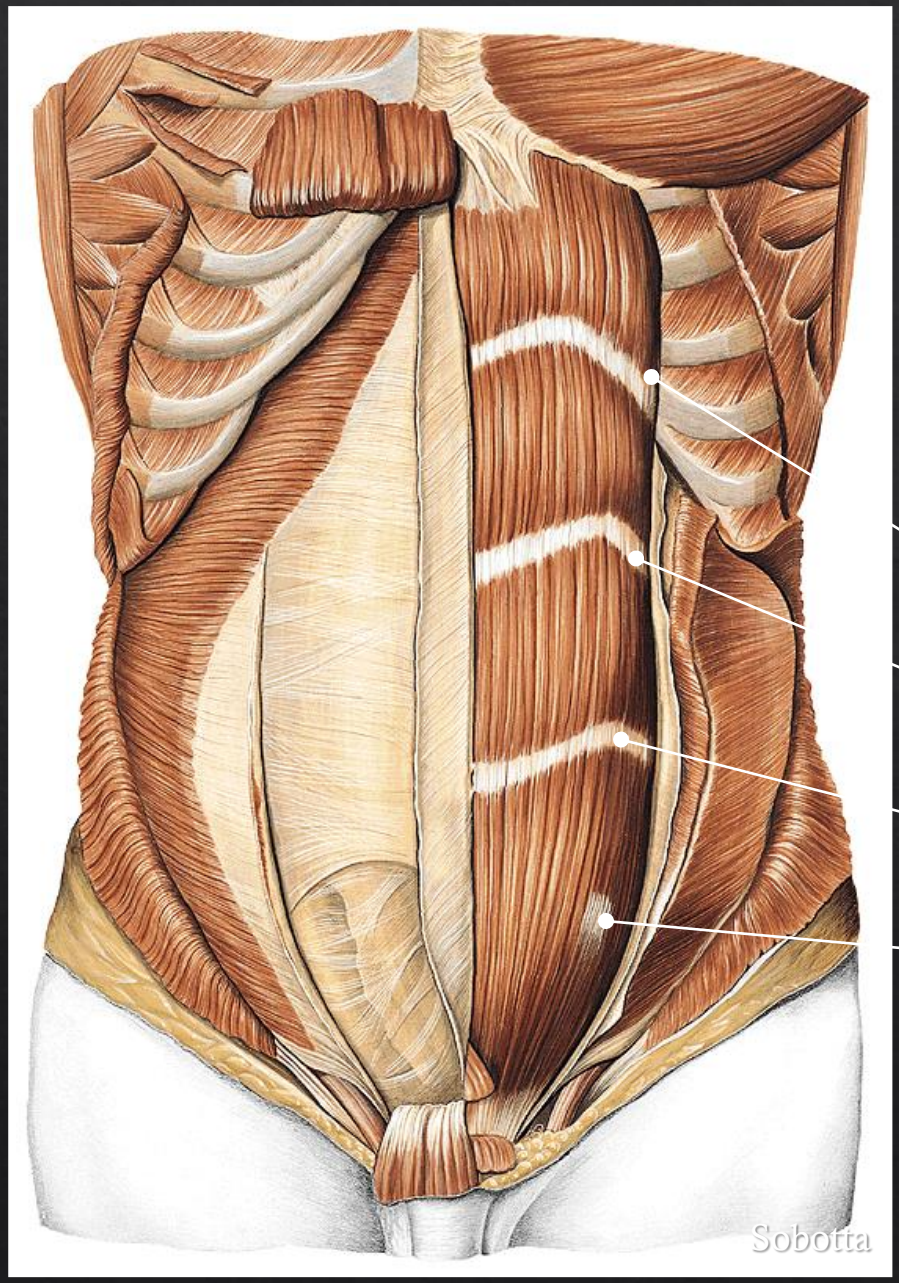
Sobotta

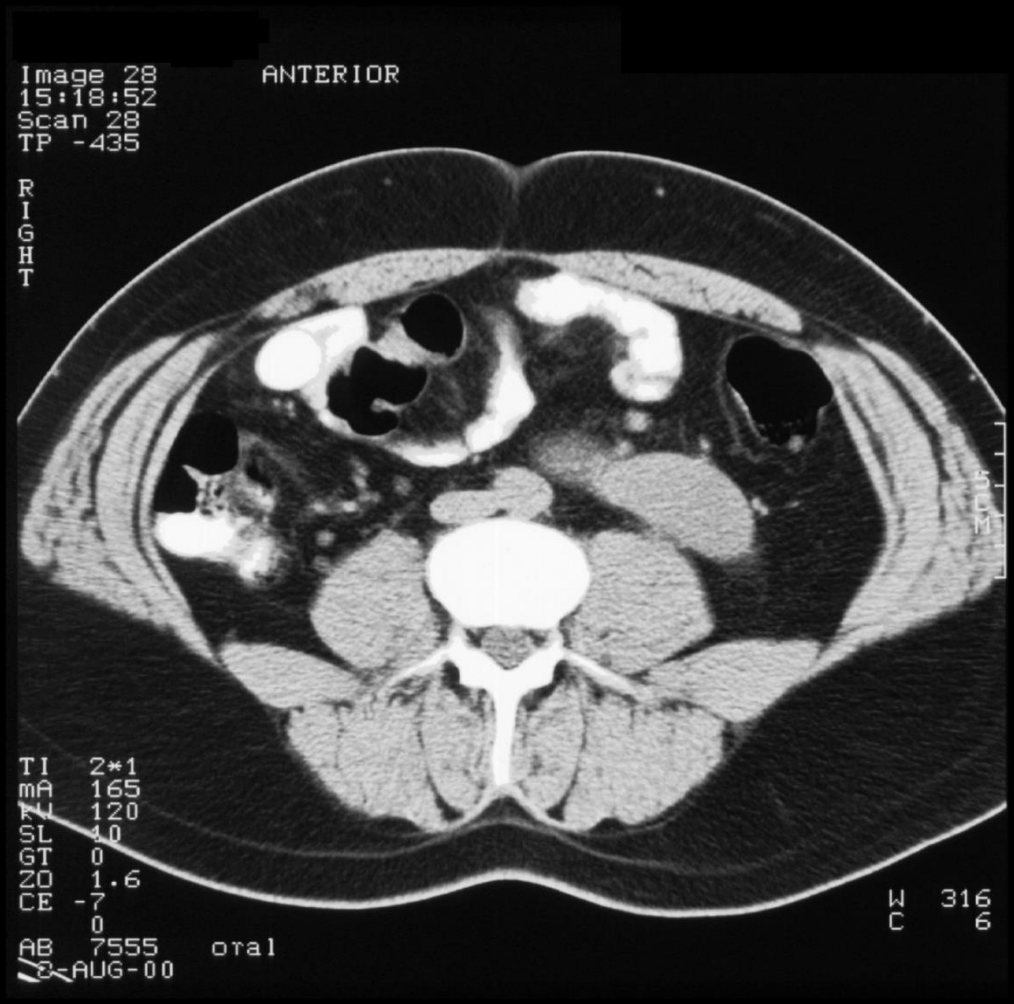
Image 28
15:18:52
Scan 28
TP -435
ANTERIOR
RIGHT
TI 2*1
mA 165
KV 120
SL 10
GT 0
ZO 1.6
CE -7
0
AB 7555 oral
8-AUG-00
W 316
C 6

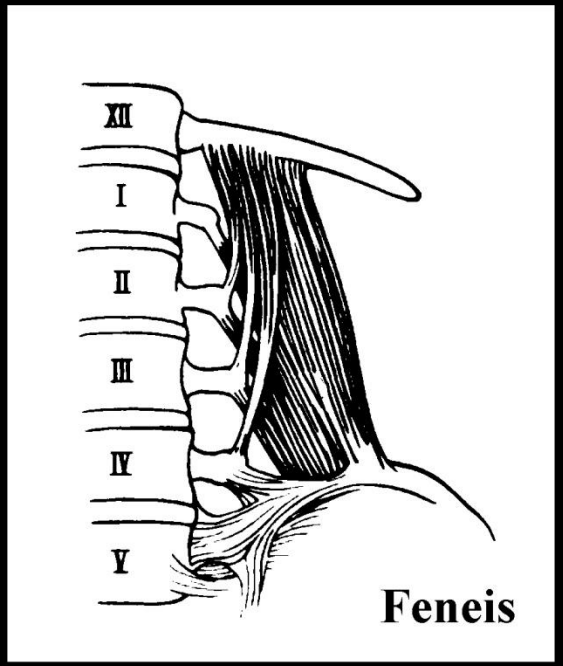
XII
I
II
III
IV
V
Feneis

CT

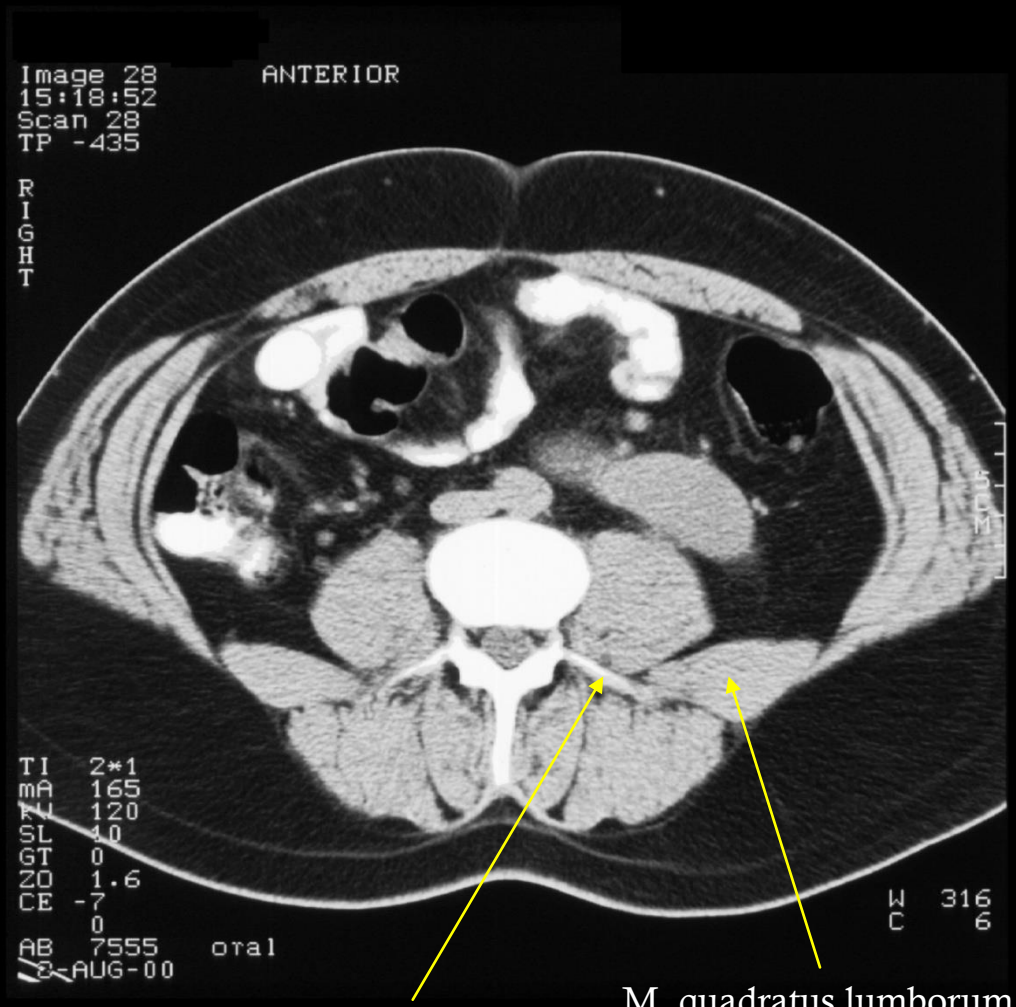

Processus transversus

M. quadratus lumborum

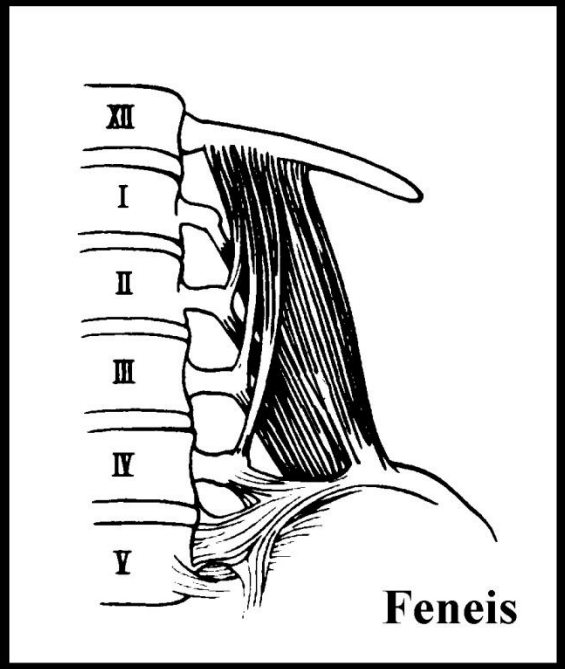

CT

Diaphragma

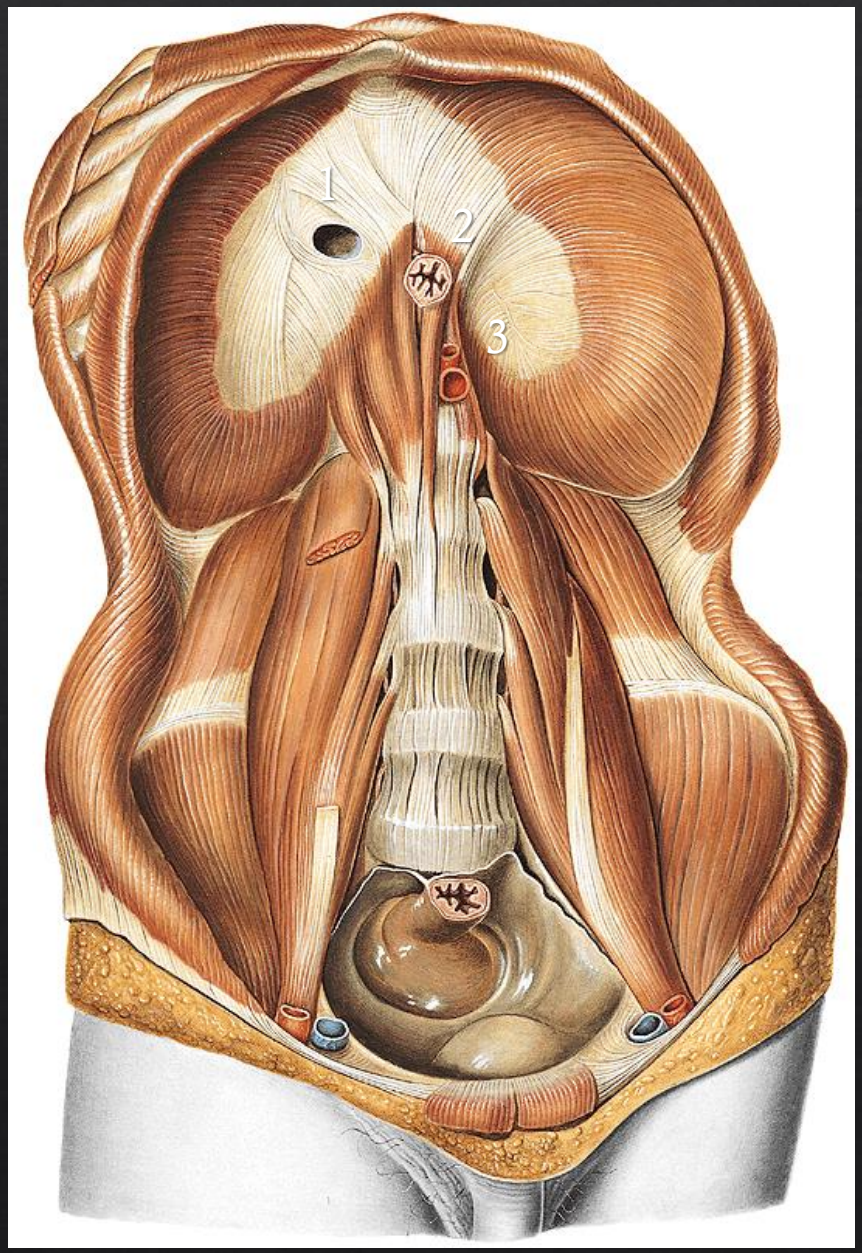

1) Foramen venae cavae
2) Hiatus esophageus
3) Hiatus aorticus

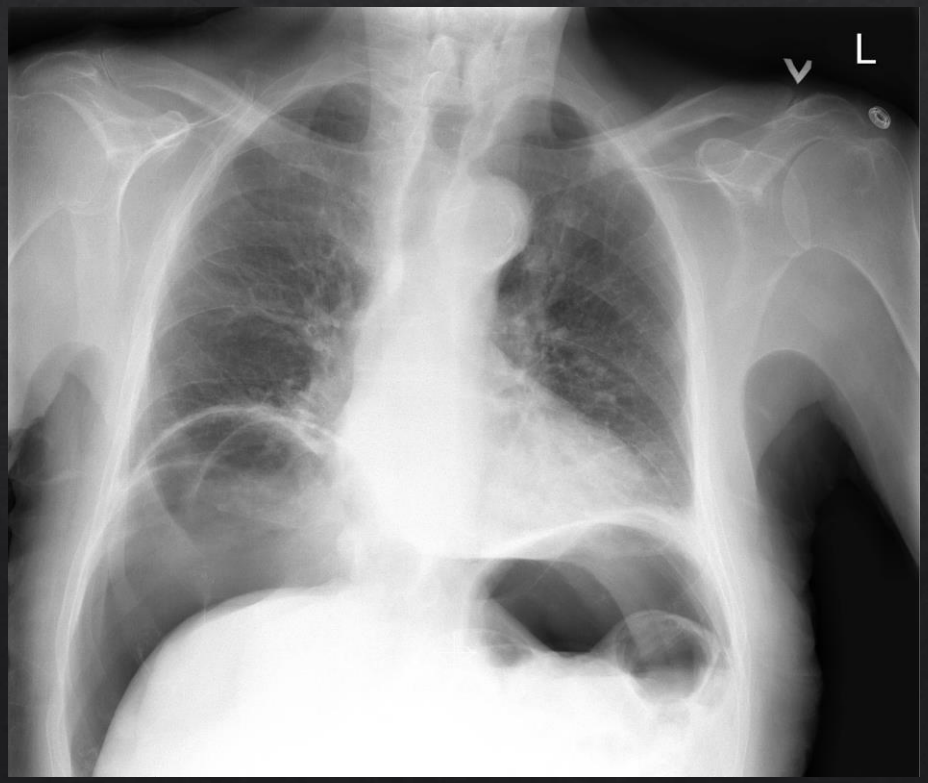

Pneumoperitoneum efter ERCP

Diaphragma

Under normale omstændigheder, ses ikke pneumoperitoneum. Der skal således altid være en god forklaring på fundet, eksempelvis de første dage efter en abdominal operation. Ellers må man mistænke perforation af et hulorgan, (ventrikel, tynd- eller tyktarm). Luften i sig selv vil blive resorberet igen, men der kan også lække tarmindhold med bakterier ud i peritoneum, således der opstår betændelse i bughulen, kaldet peritonit.
På den foreliggende stående røntgenoptagelse af thorax, ses diaphragma kuplerne tydeligt, da der er de luftholdige lunger kranielt og luften i peritoneum kaudalt herfor.

Pneumoperitoneum, luft i bughinden, opstået efter en kikkertundersøgelse af galdevejene og pancreas (Endoskopisk retrograd cholangio-pancreaticoskopi).

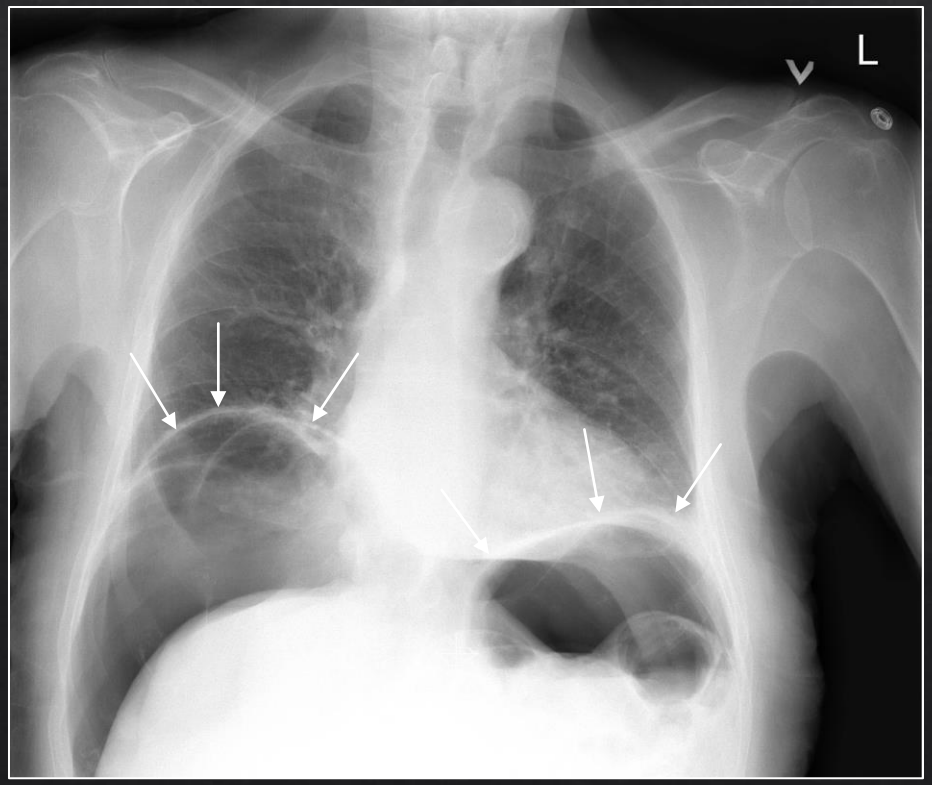

Pneumoperitoneum efter ERCP

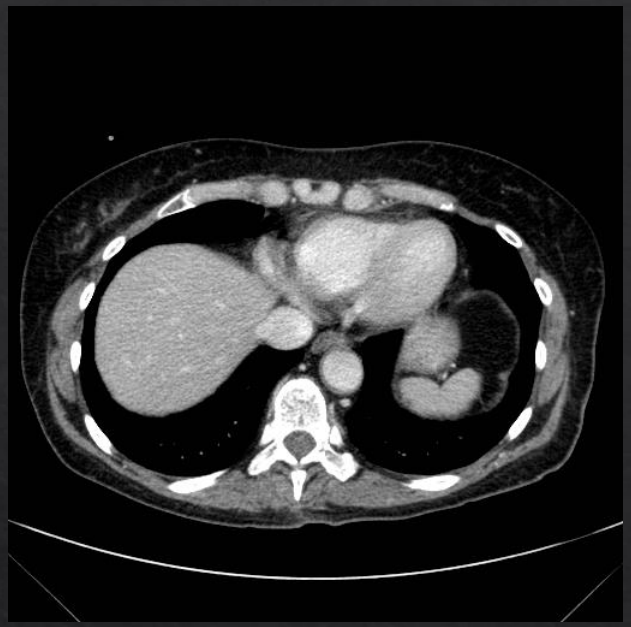

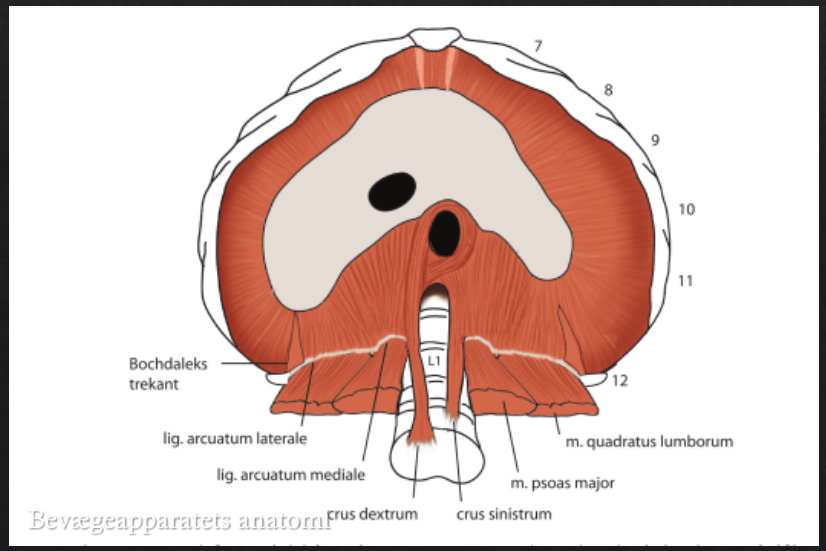
7
8
9
10
11
12
L1
Bochdaleks trekant
lig. arcuatum laterale
lig. arcuatum mediale
crus dextrum
crus sinistrum
m. psoas major
m. quadratus lumborum
Bevægeapparatets anatomi

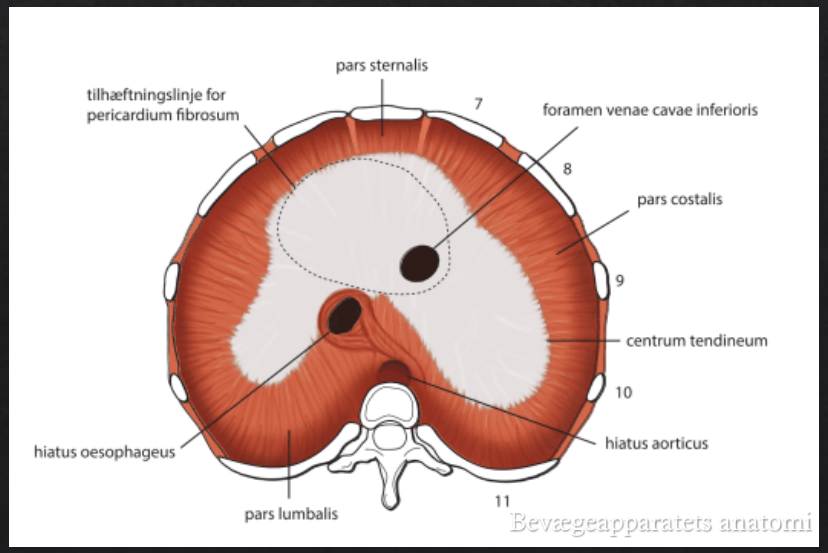
pars sternalis
tilhæftningslinje for pericardium fibrosum
7
foramen venae cavae inferioris
8
pars costalis
9
centrum tendineum
10
hiatus oesophageus
hiatus aorticus
pars lumbalis
11
Bevægeapparatets anatomi

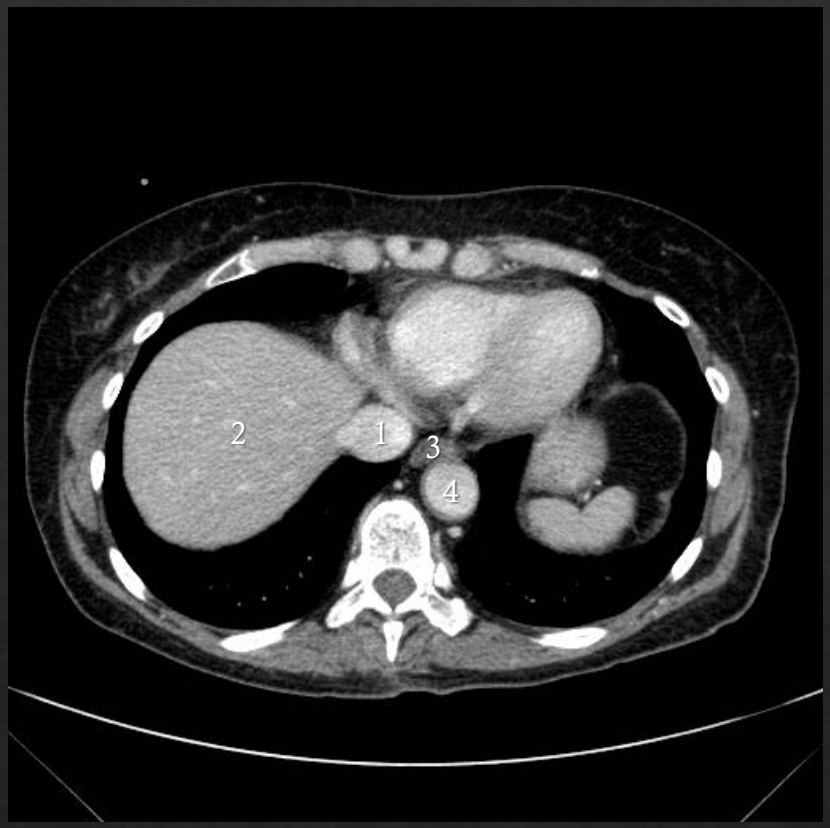

1) V. cava inf.
2) Hepar
3) Esophagus
4) Aorta
5) Crus dextrum
6) Crus sinistrum

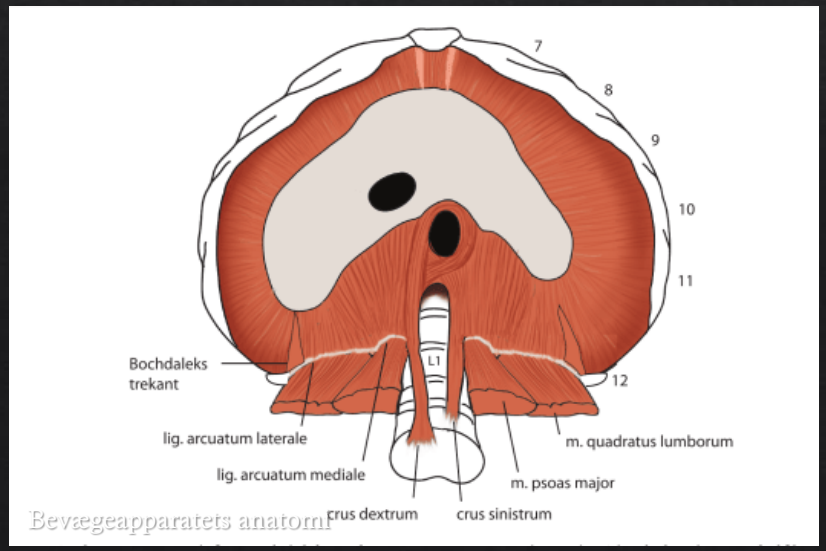

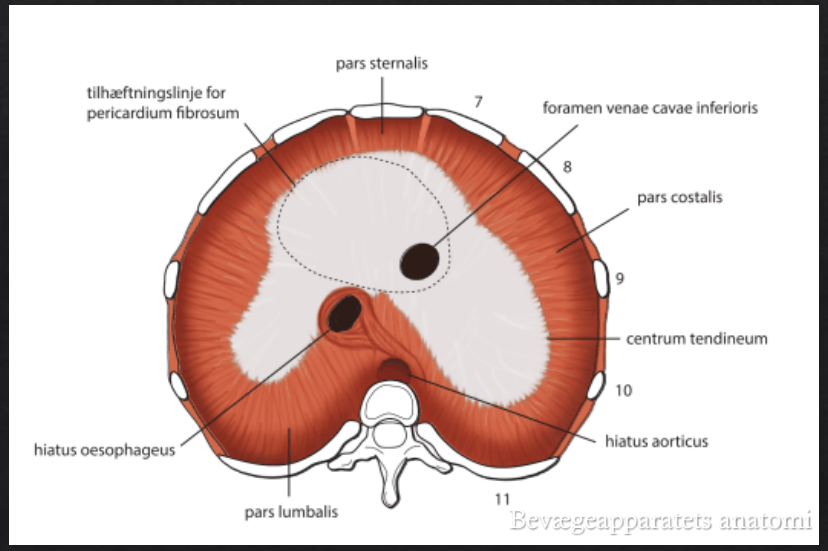

1) V. cava inf.
2) Hepar
3) Esophagus
4) Aorta
5) Crus dextrum
6) Crus sinistrum

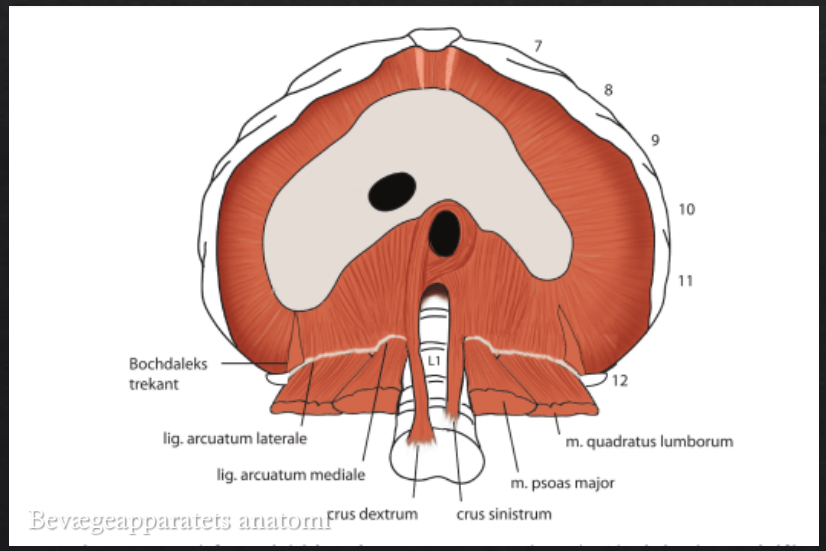

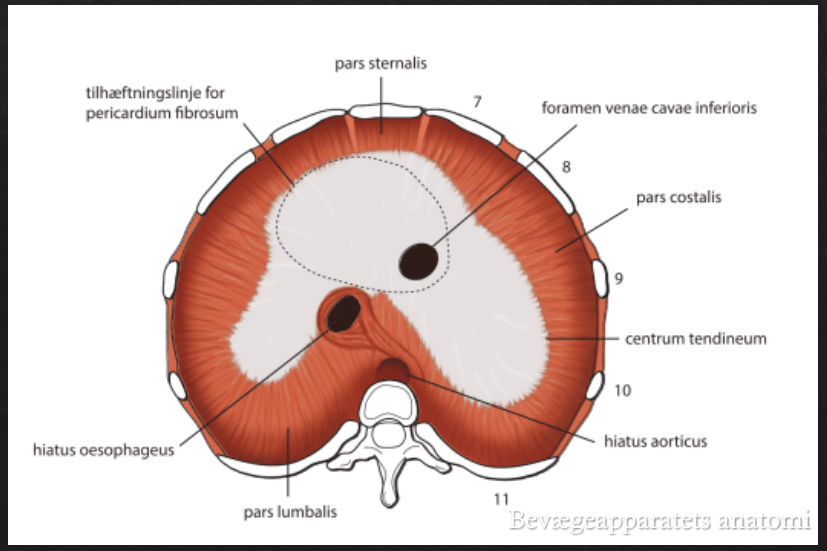

1) V. cava inf.
2) Hepar
3) Esophagus
4) Aorta
5) Crus dextrum
6) Crus sinistrum

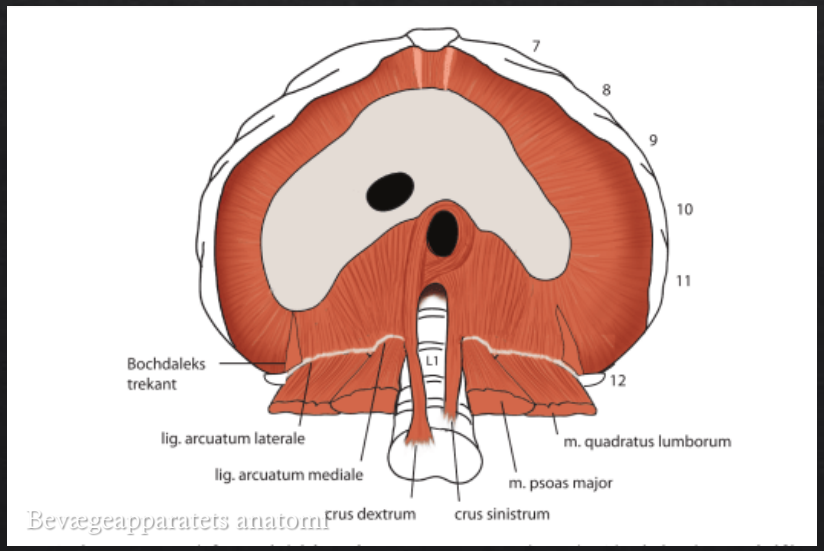

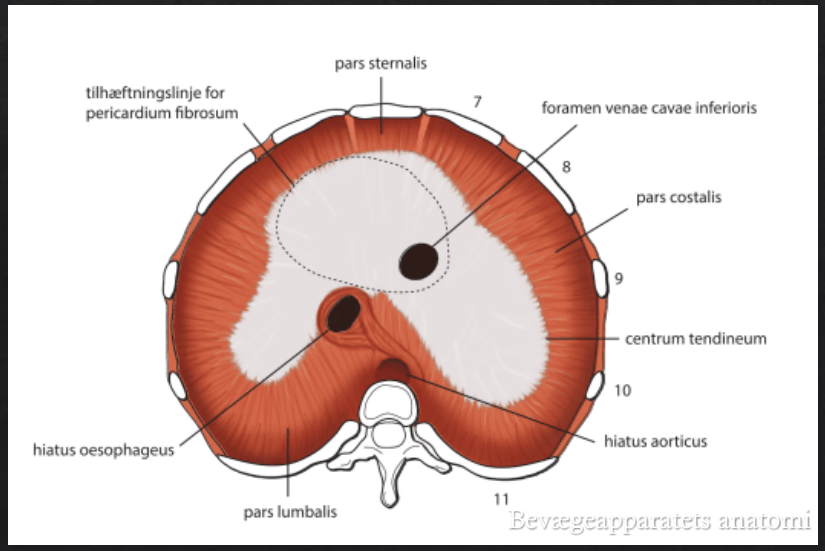

Hernia (Brok)

Abnorm fremtrængen af et organ (eller en del deraf) gennem væggen af en legemshule, almindeligvis peritonealhulen

Hernia (Brok)

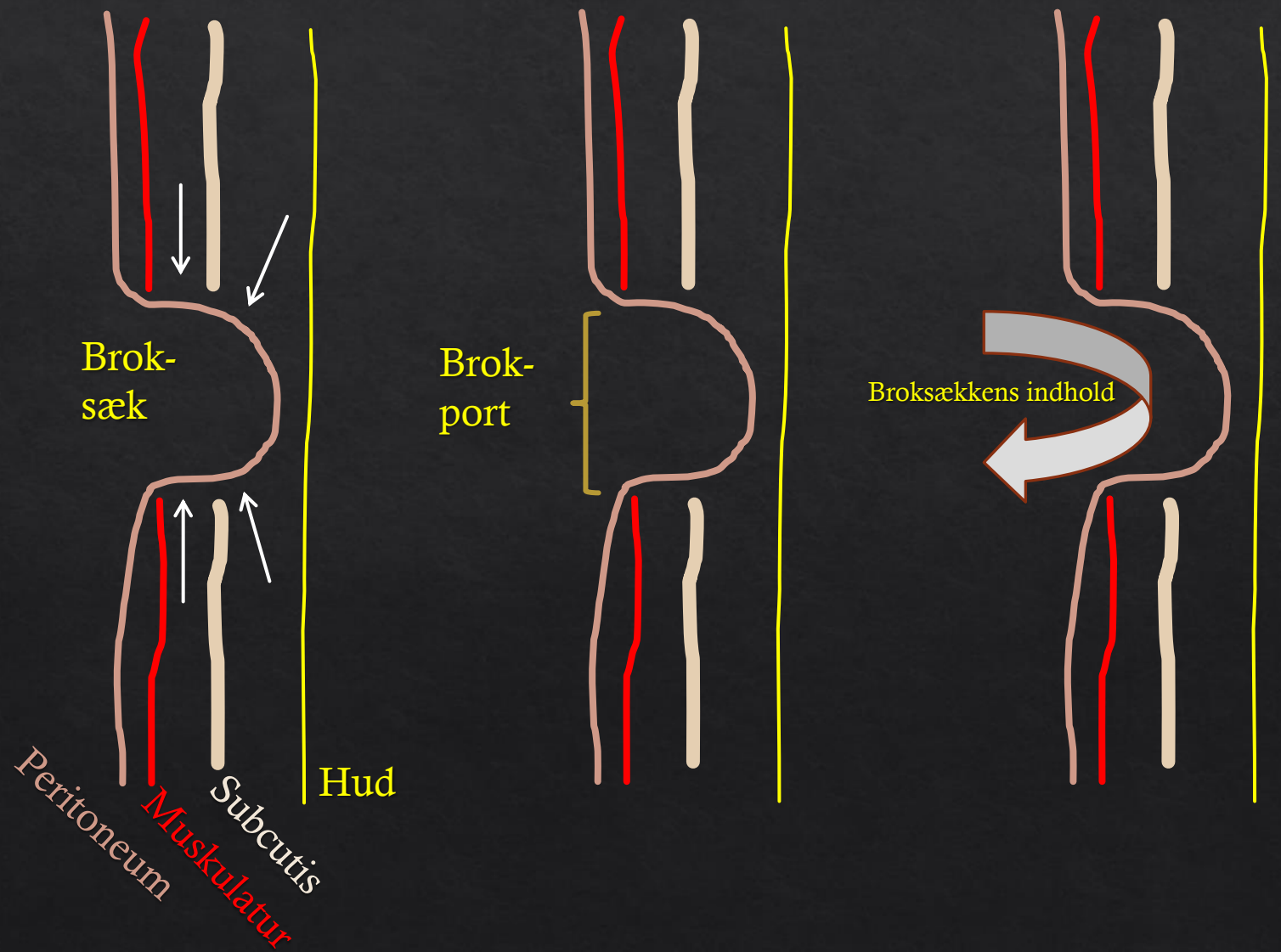
Brok-
sæk
Brok-
port
Broksækkens indhold
Hud
Subcutis
Muskulatur
Peritoneum

Umbilicalhernie

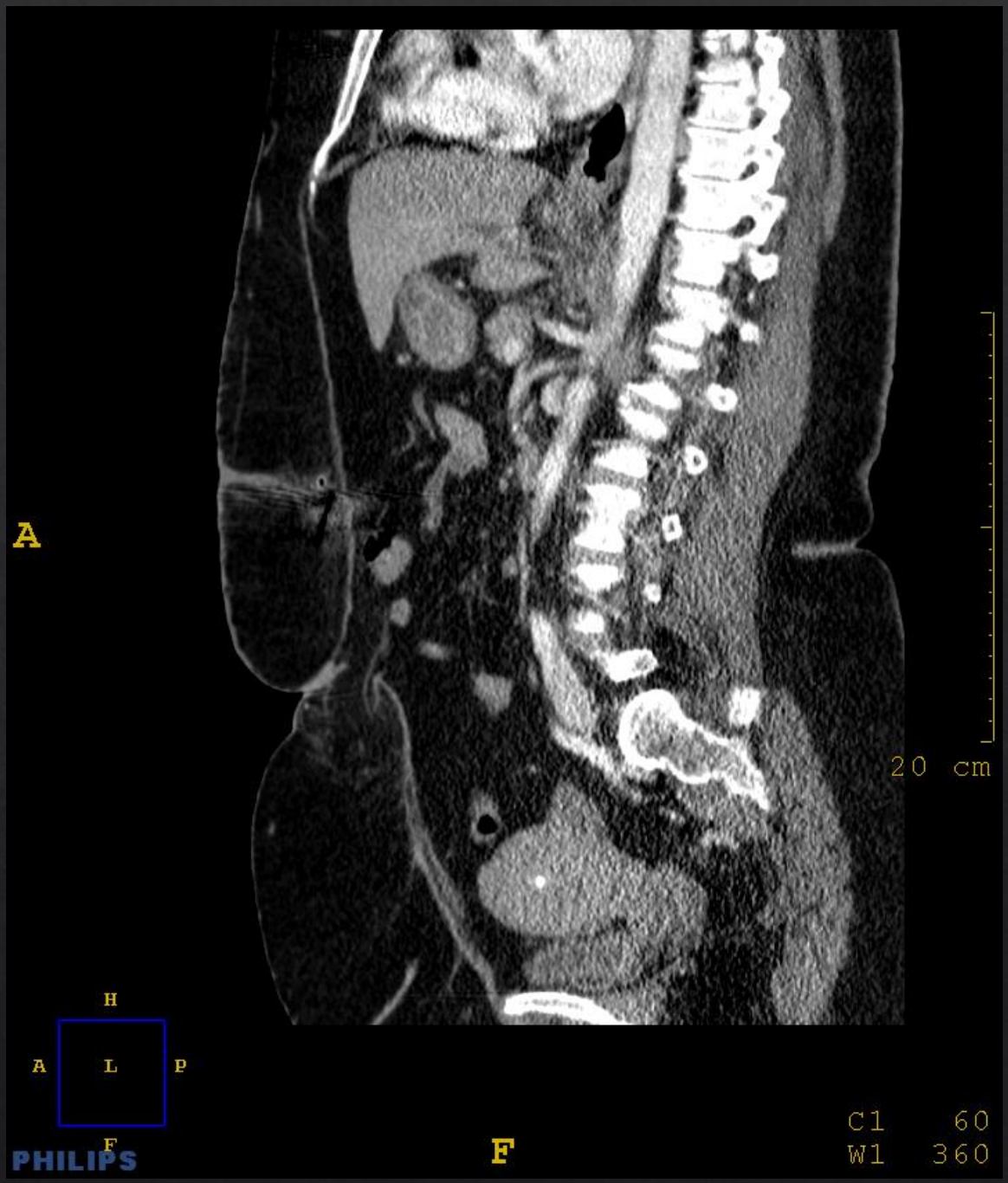
A
20 cm
H
A
L
P
F
PHILIPS
F
C1 60
W1 360

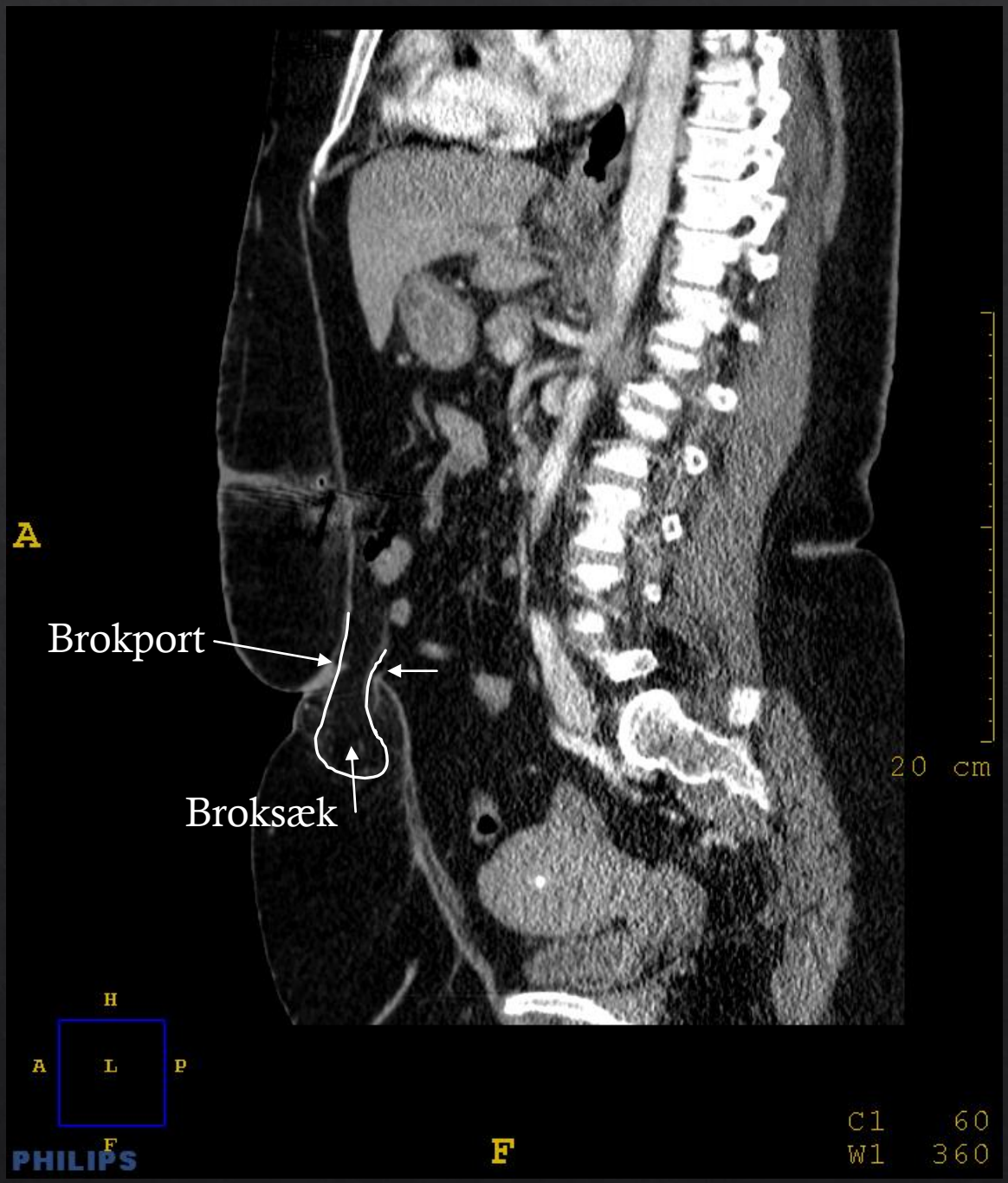
A
Brokport
Broksæk
20 cm
H
A
L
P
F
PHILIPS
F
C1 60
W1 360


R
20 cm
A
R
F
L
P
PHILIPS
P
C1 60
W1 360

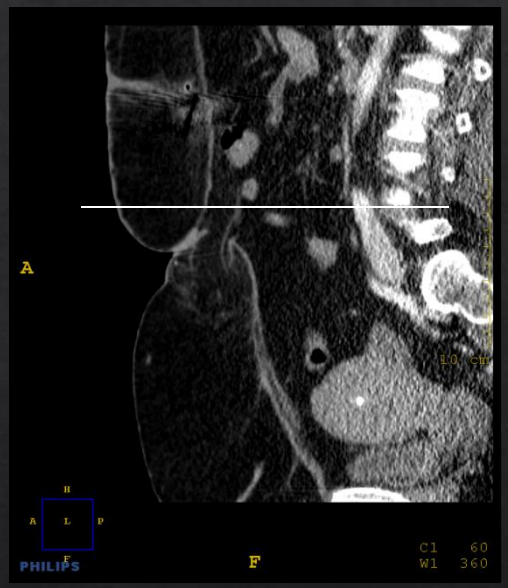
A
PHILIPS
F
C1 60
W1 360

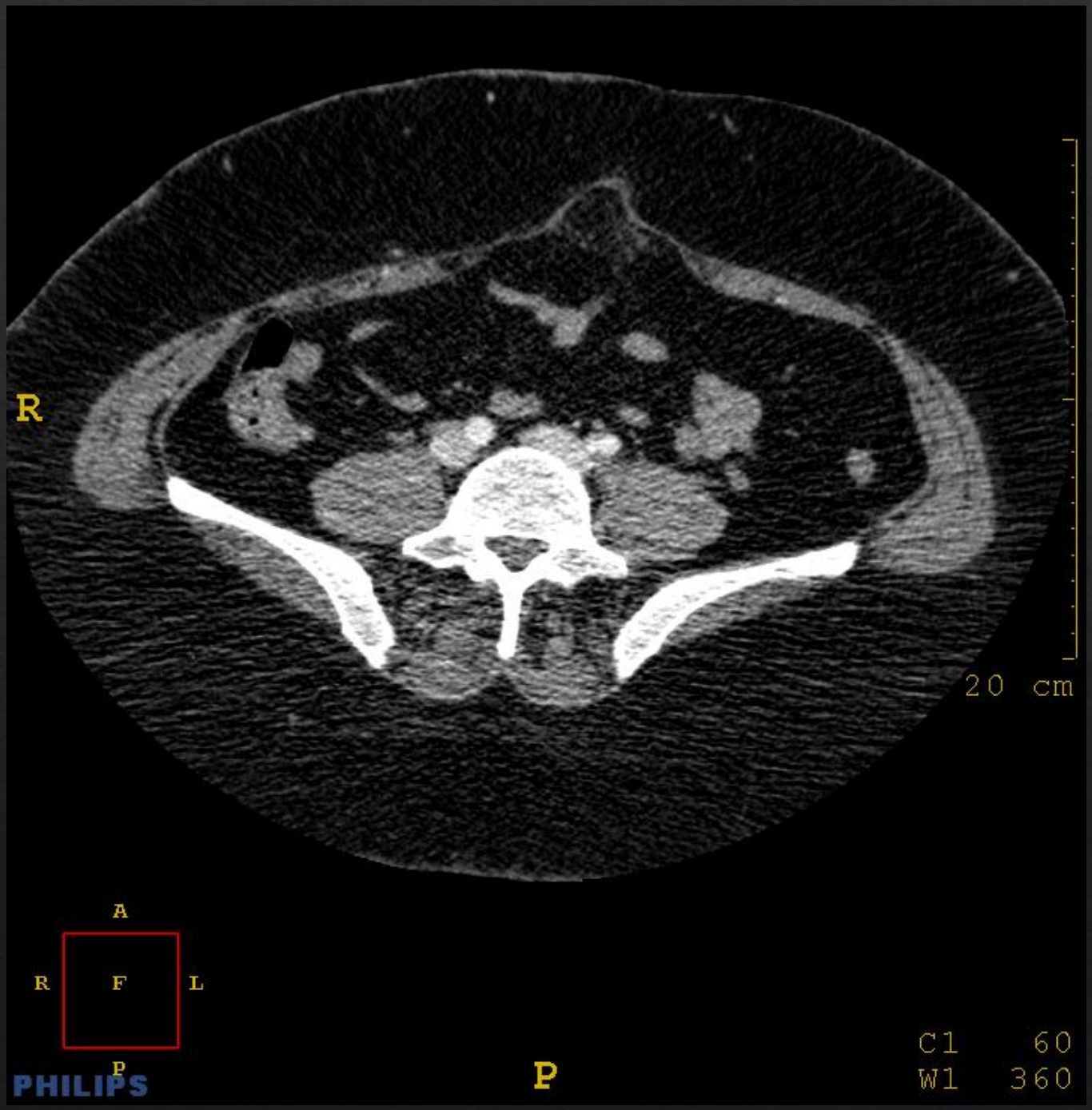
R
20 cm
A
R
F
L
P
PHILIPS
P
C1 60
W1 360

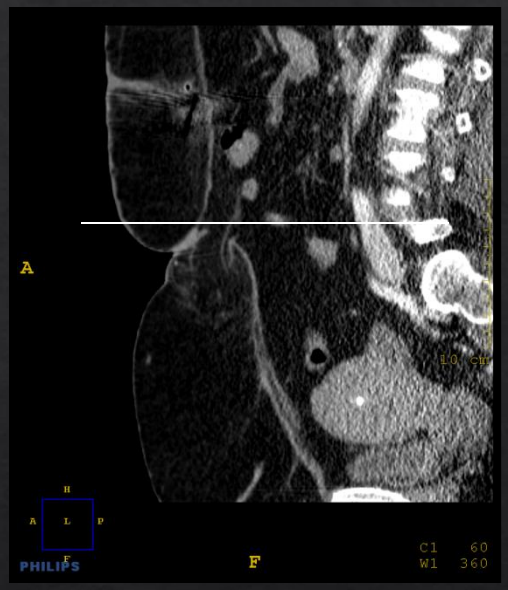
A
PHILIPS
F
C1 60
W1 360

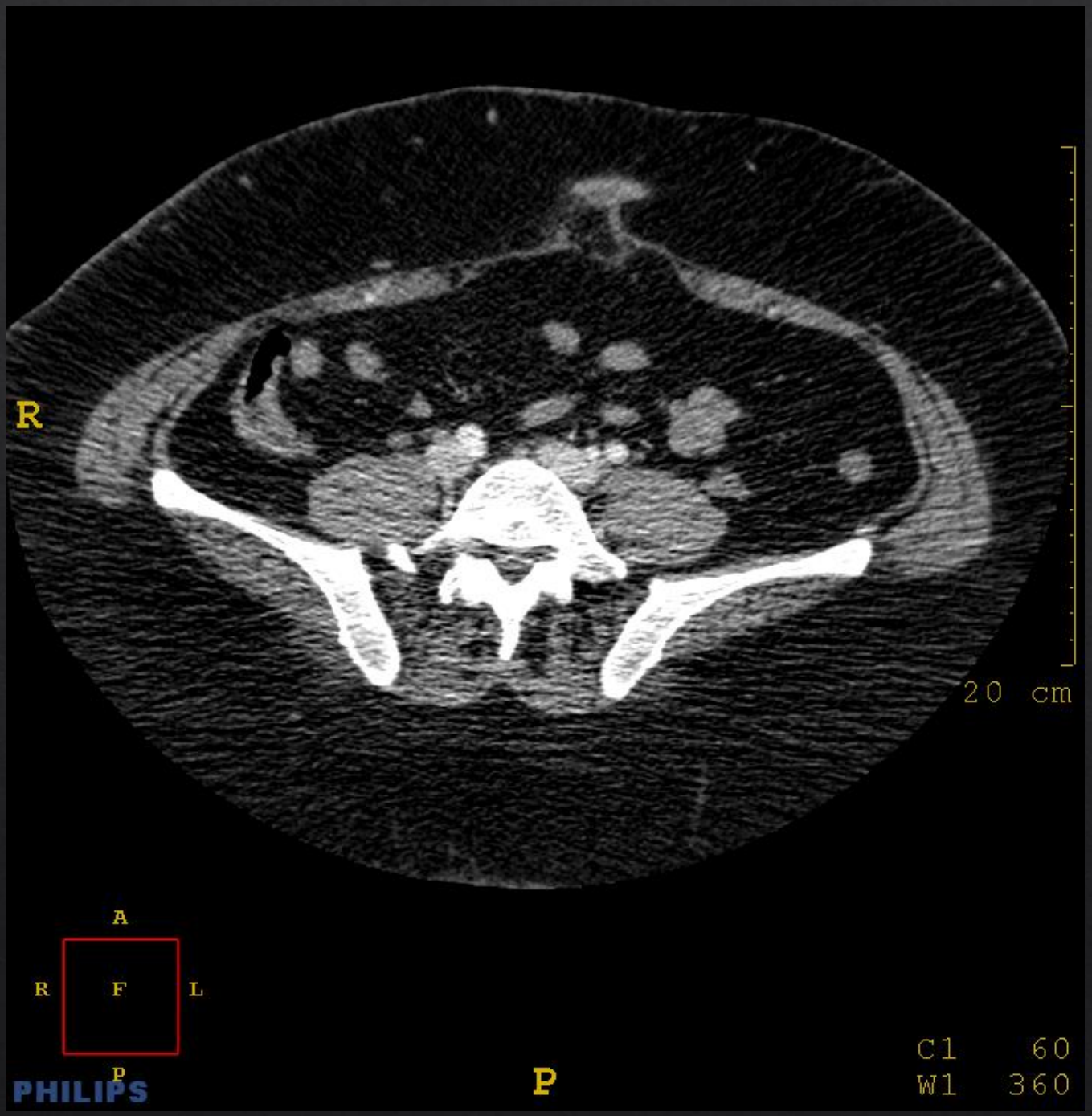
R
20 cm
A
R
F
L
P
PHILIPS
P
C1 60
W1 360

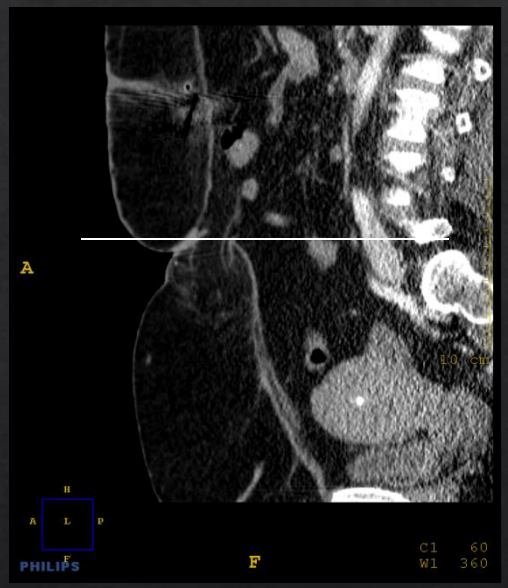
A
PHILIPS
F
C1 60
W1 360

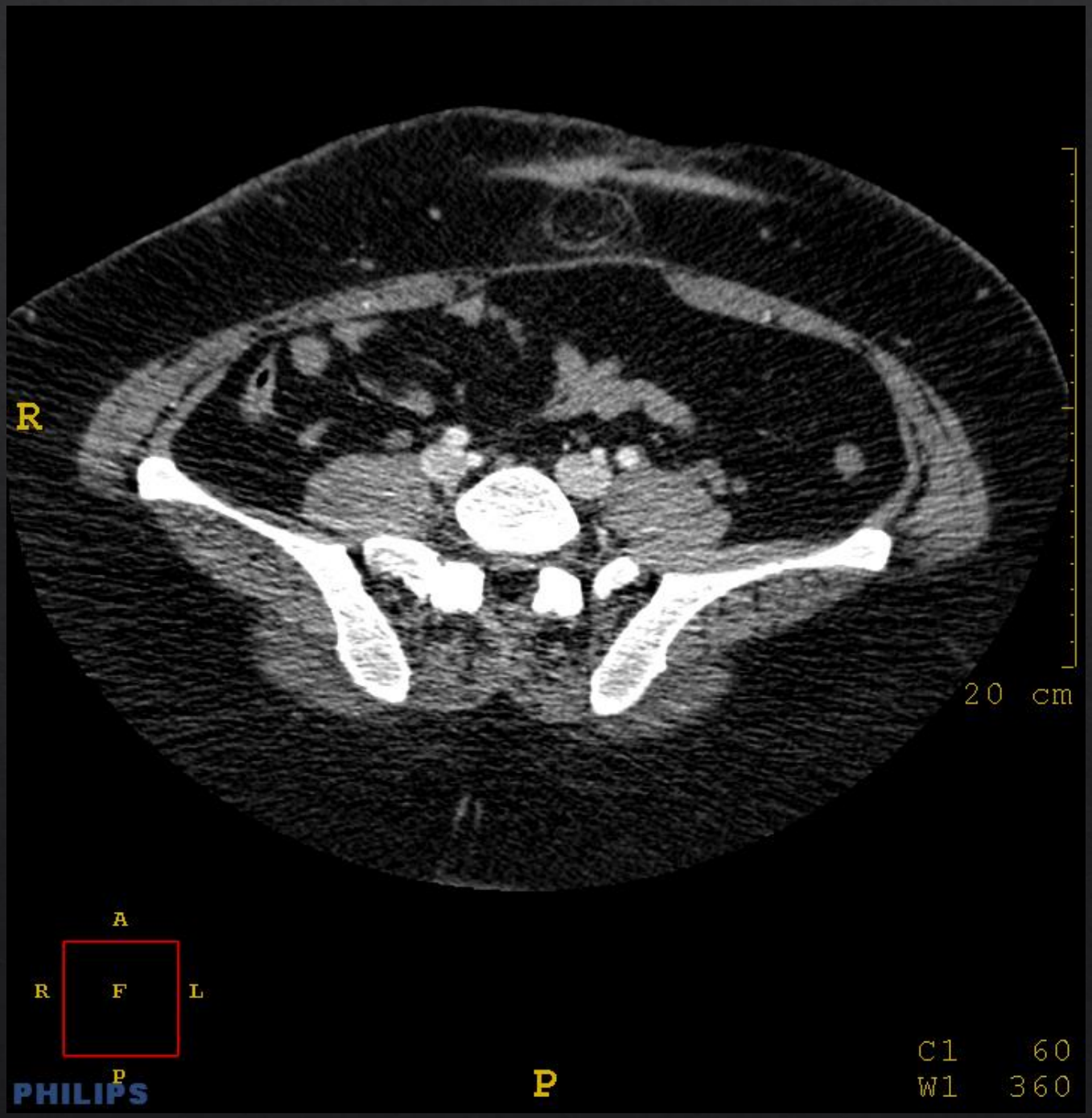
R
20 cm
A
R
F
L
P
PHILIPS
P
C1 60
W1 360

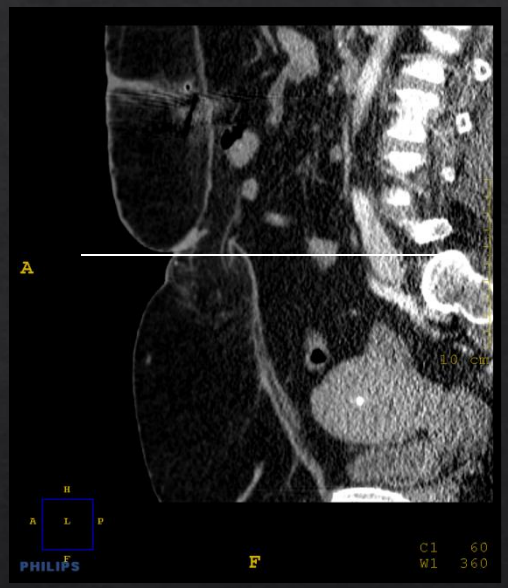
A
PHILIPS
F
C1 60
W1 360

Diaphragma hernie

Diaphragma

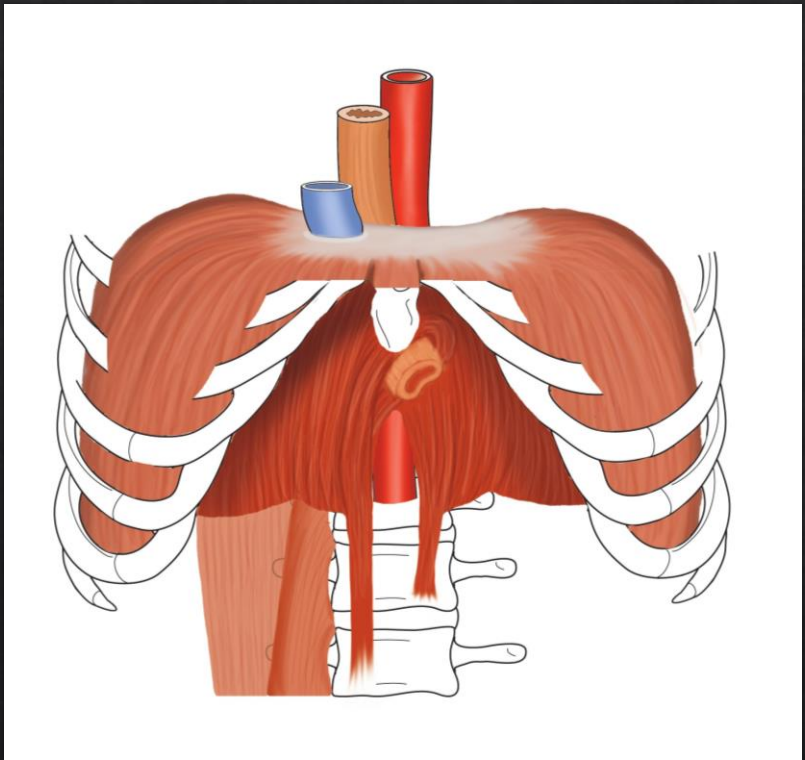

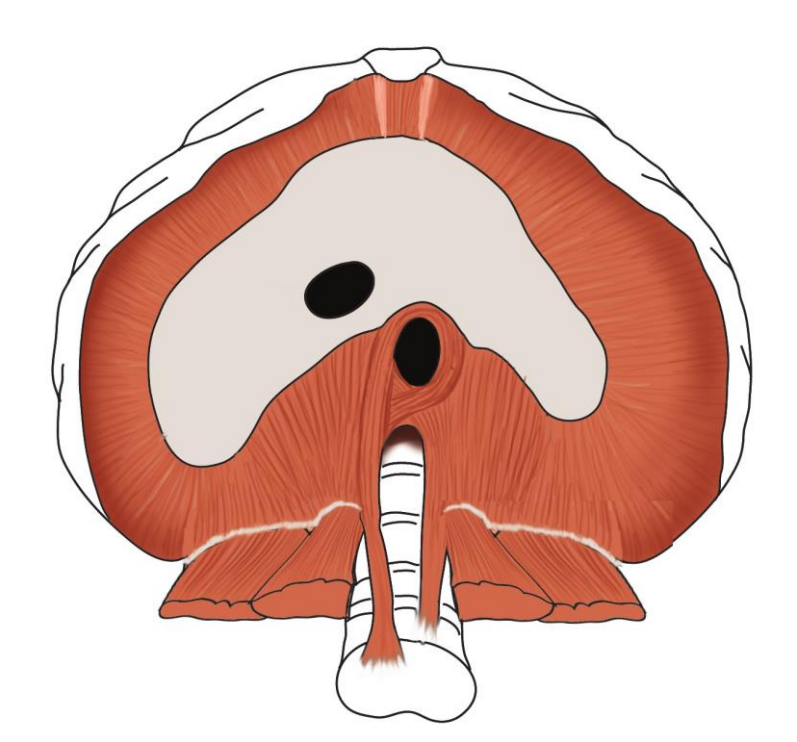

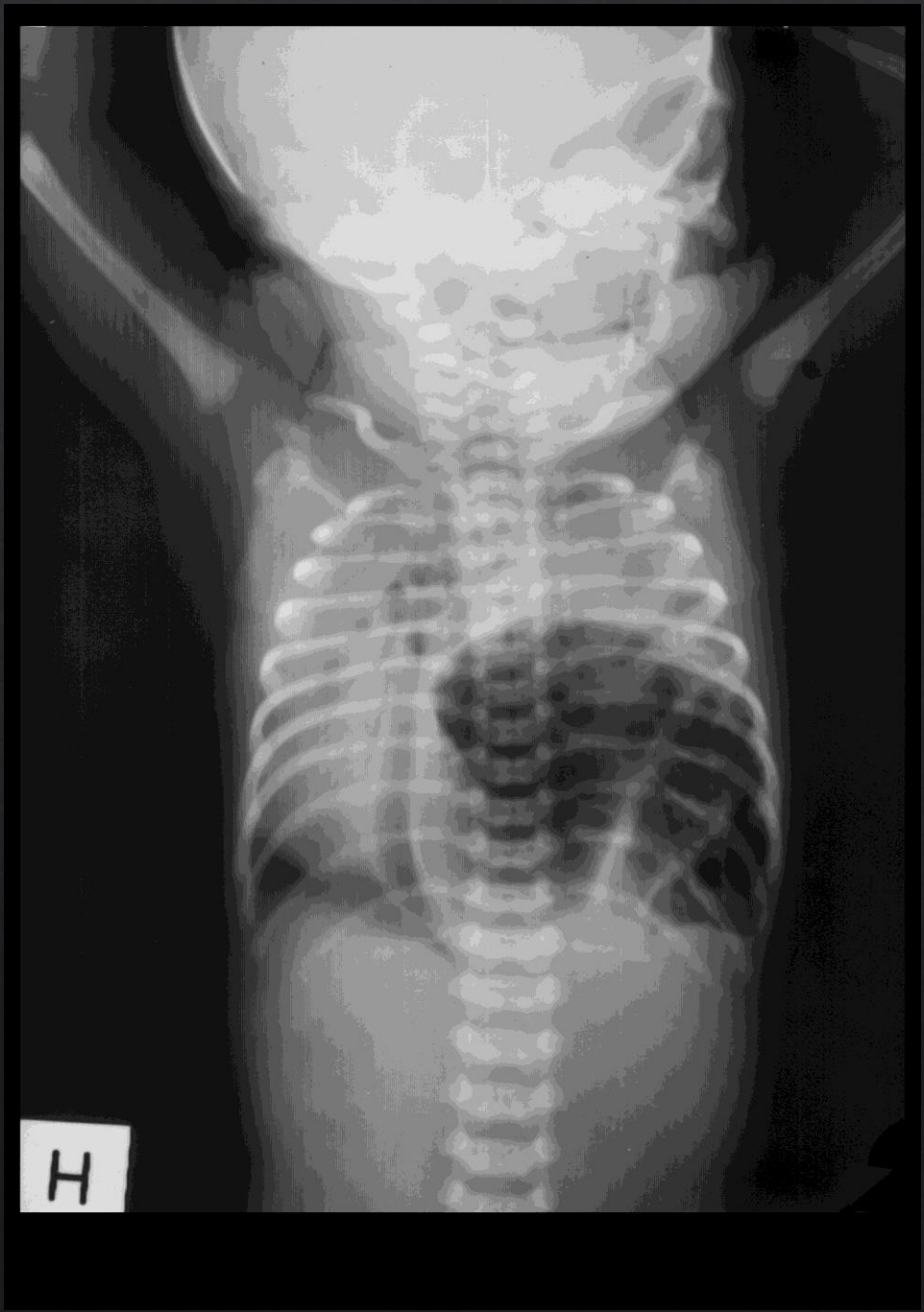

Nyfødt med respiratoriske problemer.
Røntgen af thorax kort tid efter fødslen.

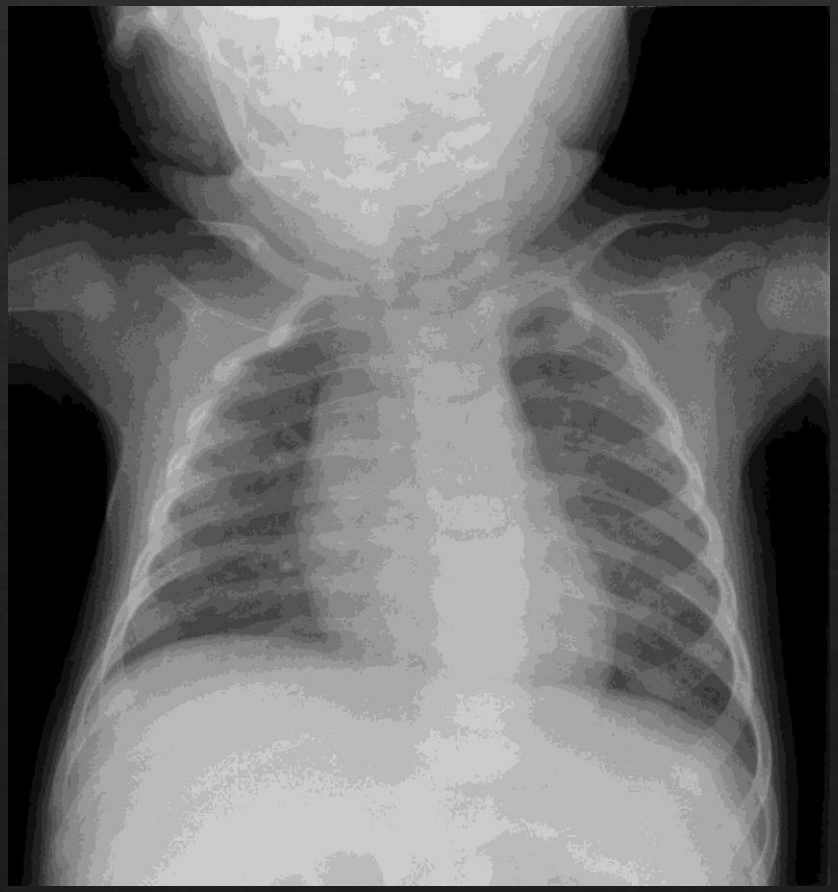

Til sammenligning: Rask, 5 måander gammel.

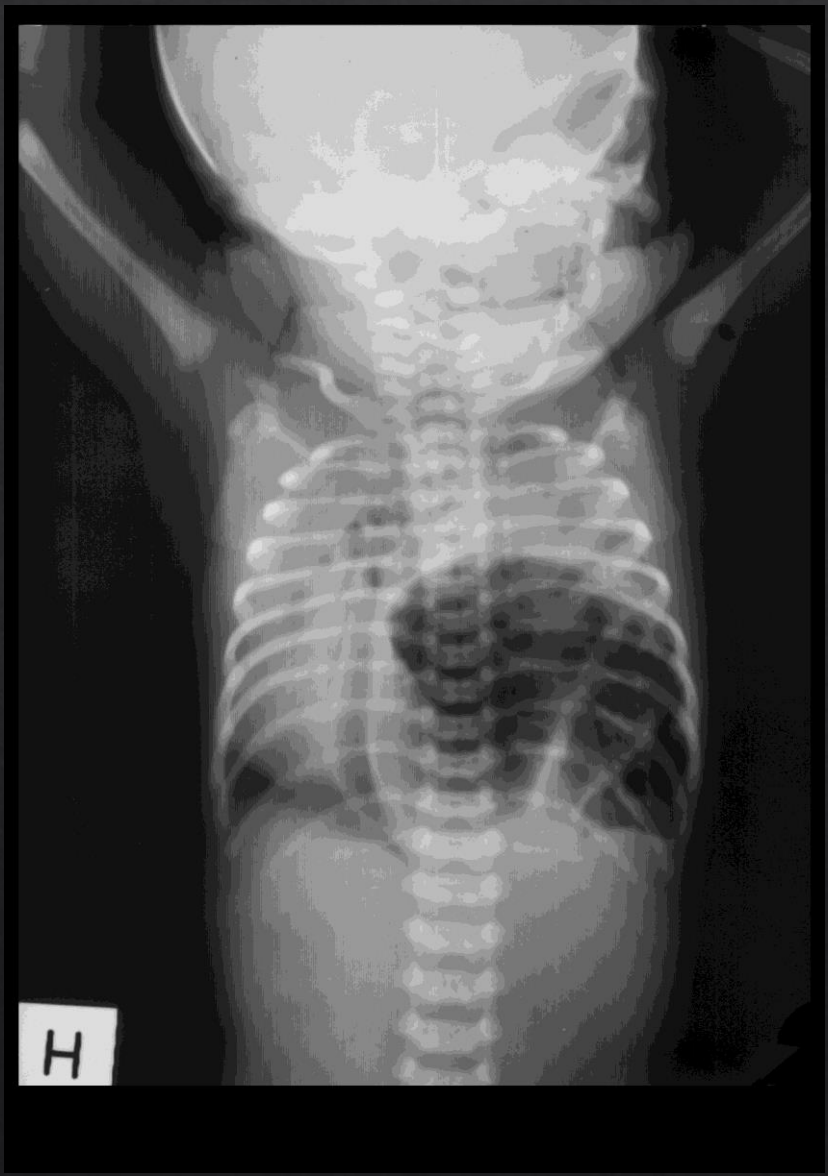

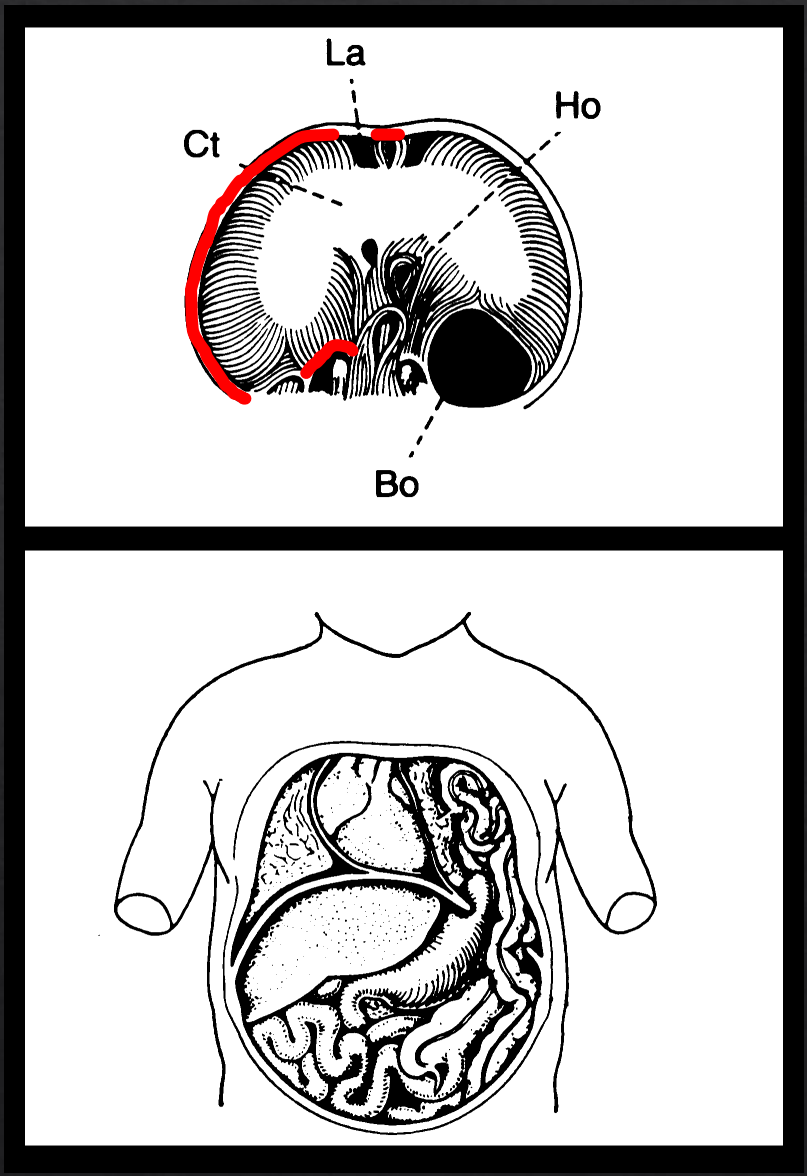

Kongenit diafragmahernie

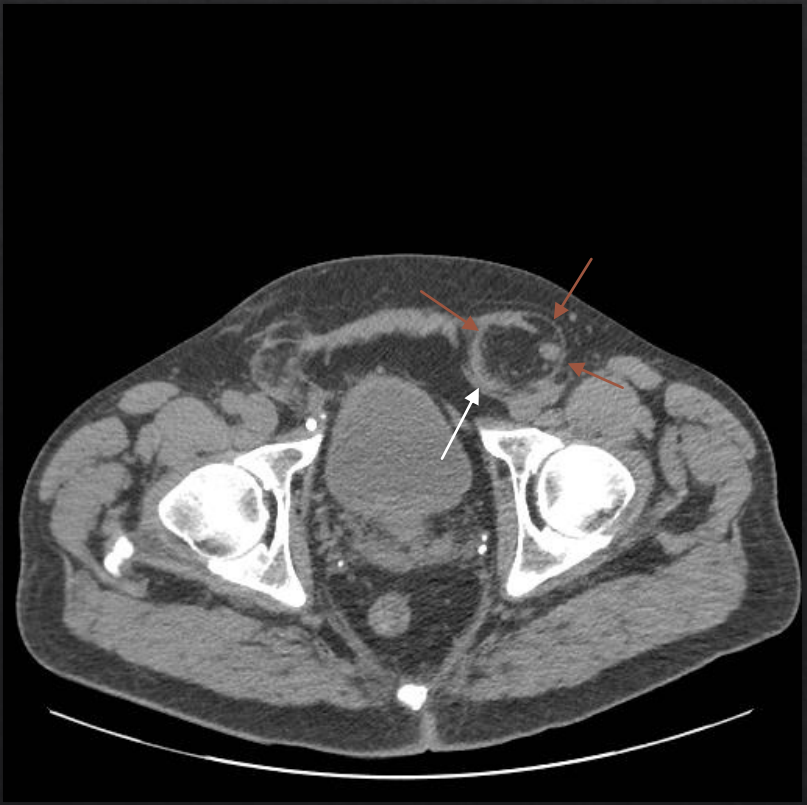

Intern hernie

Interne hernier:

Foramen epiploicum

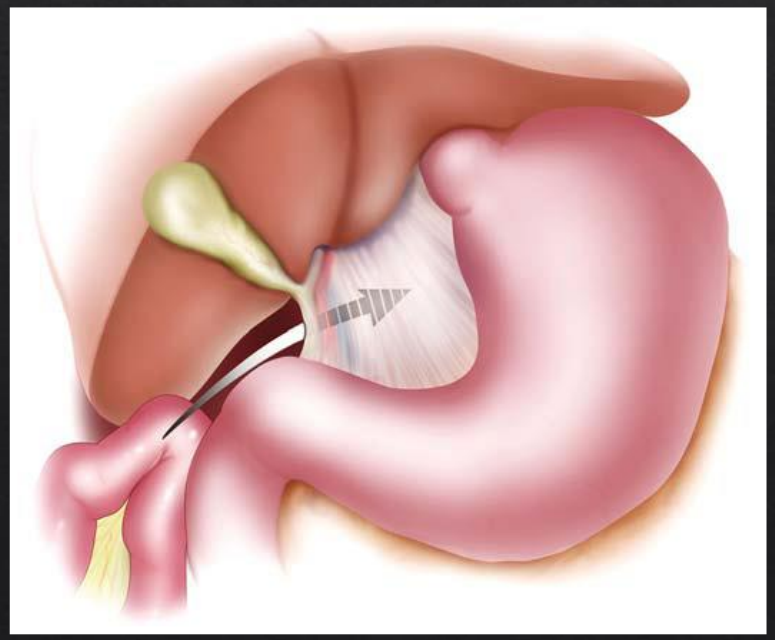

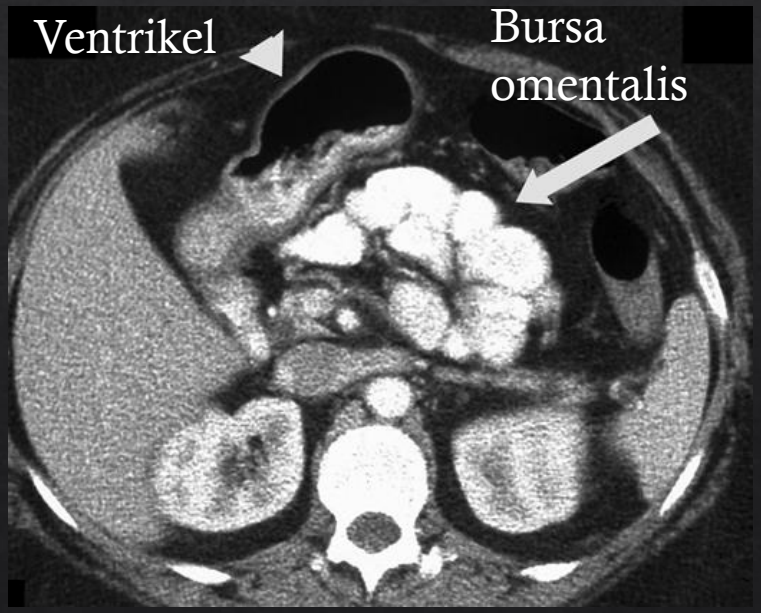

L. C. Martin et al. AJR:186, March 2006