Billedanatomi Underekstremiteten

Michel Bach Hellfritzsch

Overlæge

Røntgen og Skanning, Aarhus Universitetshospital

Bækkenet: Os coxae og os sacrum

Articulatio coxae

Femur

Articulatio genus

Crus

Articulatio talocruralis

Foden

HKA optagelse (Hip/knee/ankle eller hofte/knæ ankel optagelse), giver et godt overblik over underekstremiteterne. Vanligvis er dosis reduceret, således at knoglestrukturen ikke ses optimalt, da undersøgelsen bruges til at vurdere benlængdeforskel (anisomeli) samt akser (valgus/varus fejlstilling).

Bækkenet

Ossifikationens start angivet i føtaluge for hoftebenet: Os coxae

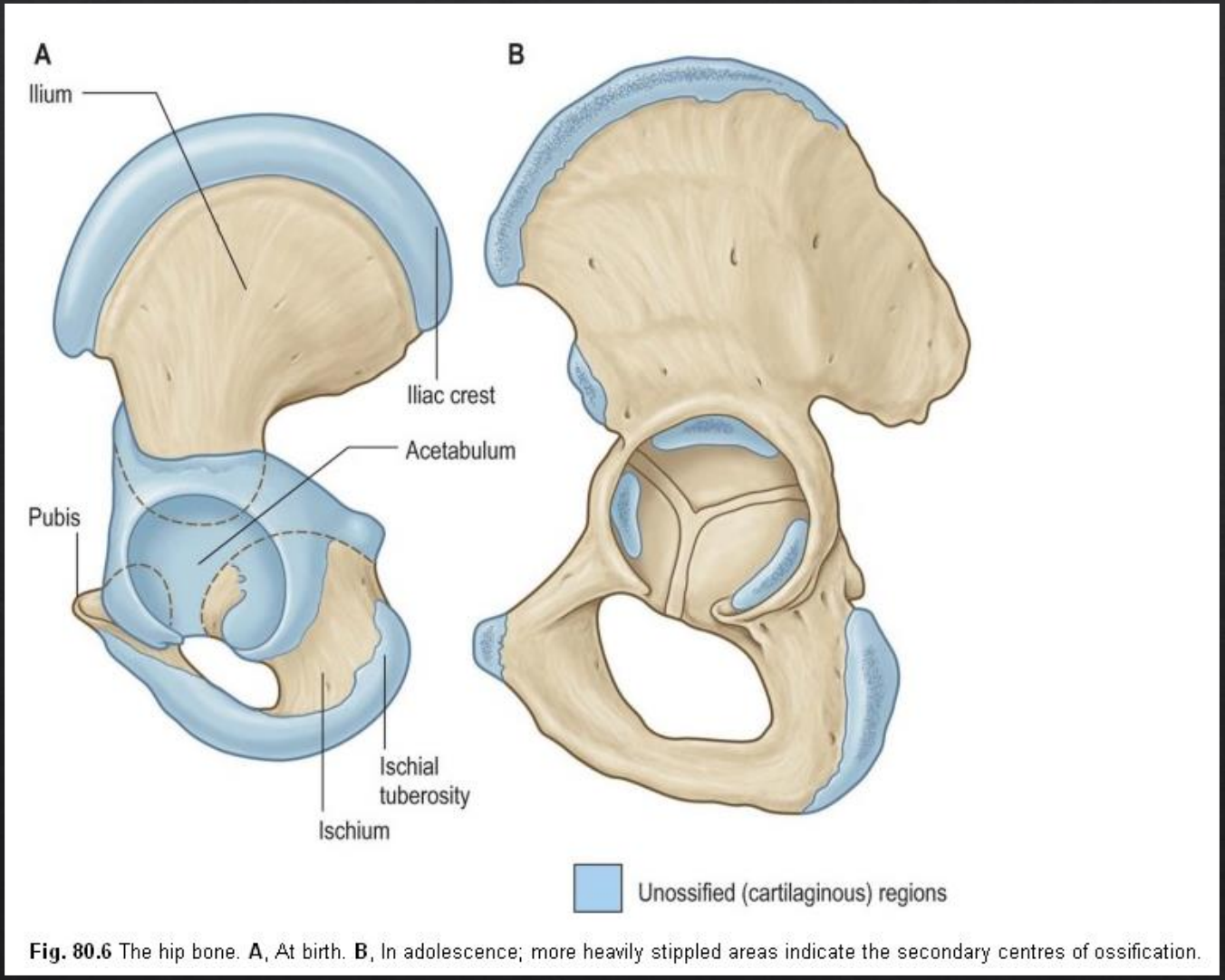

Fig. 80.6 The hip bone. **A**, At birth. **B**, In adolescence; more heavily stippled areas indicate the secondary centres of ossification.

Gray 40th ed.

Os ilium

9 uger

Os ischium

17-18 uger

Os pubis

21-28 uger

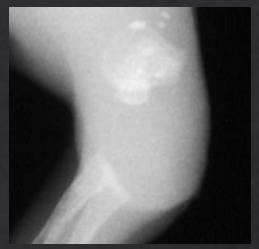

Gestationsalder 12-13 uger

Gestationsalder 26-28 uger

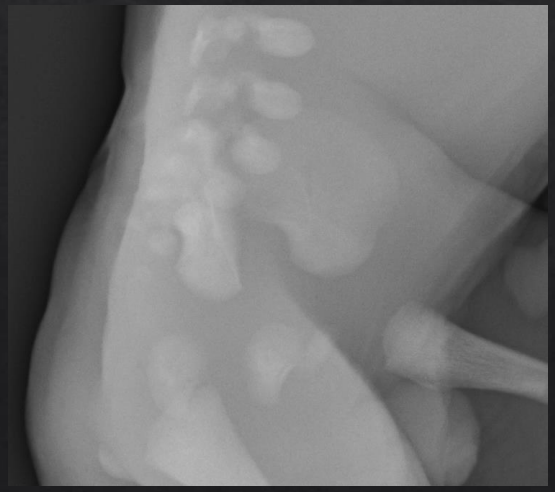

Gestationsalder 31 uger

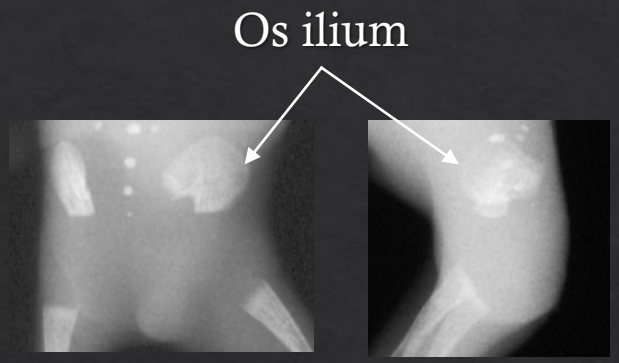

Gestationsalder 12-13 uger

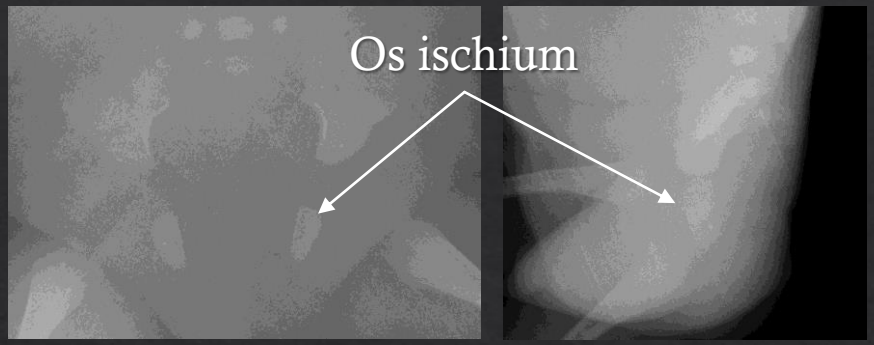

Gestationsalder 26-28 uger

De forskellige knogler i bækkenet forbener (ossificerer) i forskellig alder, hvilket kan benyttes til aldersbestemmelse af fostre. Fosterets knogler kan også vurderes med ultralyd, billederne her er røntgenbilleder.

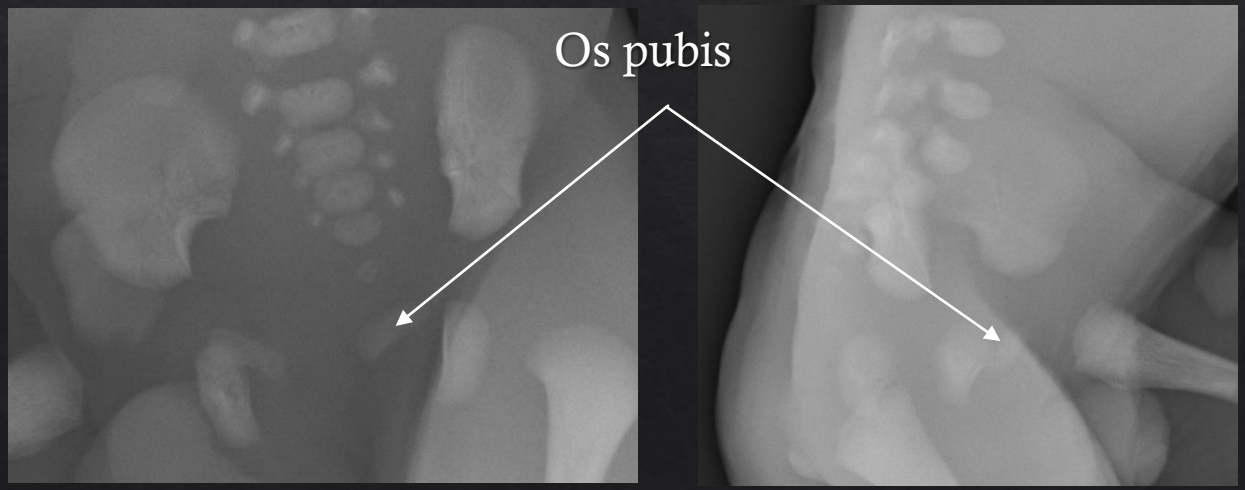

Gestationsalder 31 uger

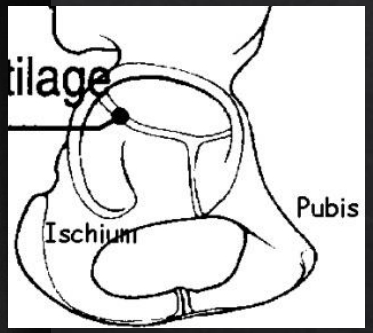

Dreng 7 år

I bunden af acetabulum ligger den triradiate brusk eller Y-brusken, hvor væskten i acetabulum foregår. Den svarer i princippet til epifyselinien i proximale femur. På røntgenoptagelsen ses kun den horisontelle del

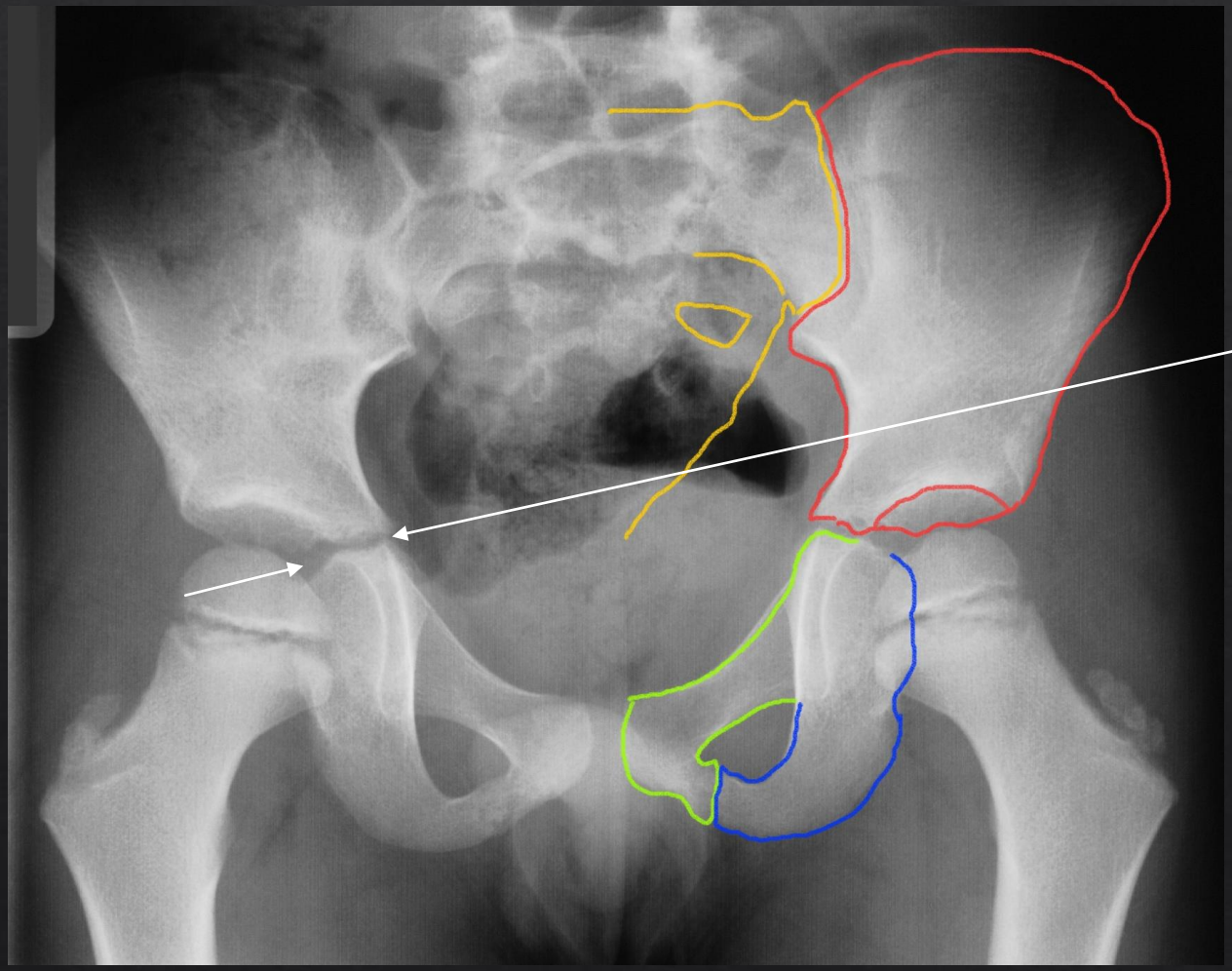

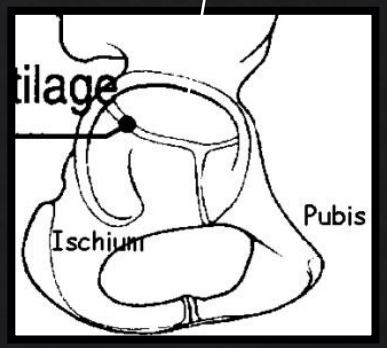

Synchondrosen mellem ramus inferior ossis pubis og ramus ossis ischii er hos dette barn fusioneret, der erkendes blot en mindre uregelmæssighed. Ofte er der tale om forskellig tidspunkt for fusionen på de to sider.

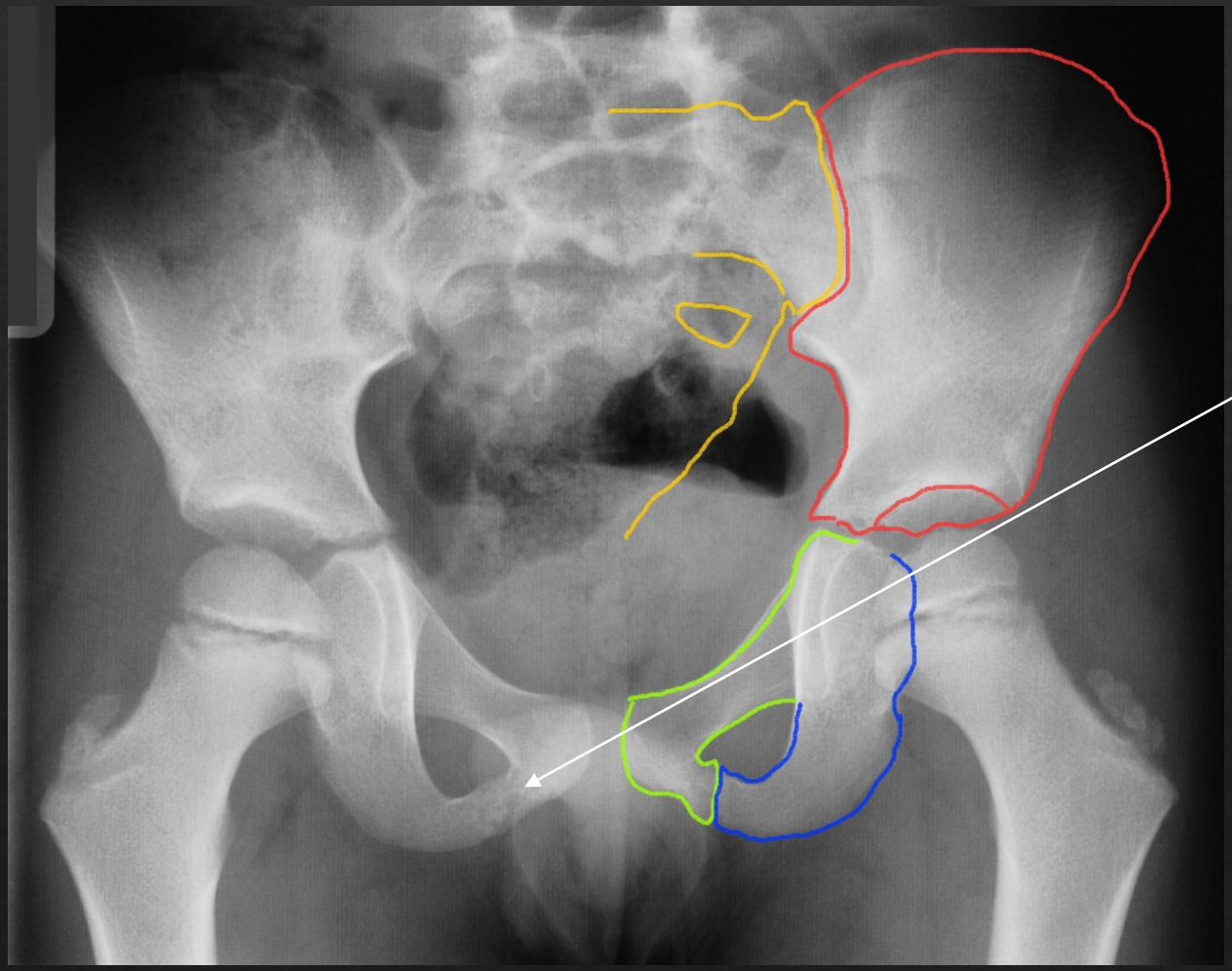

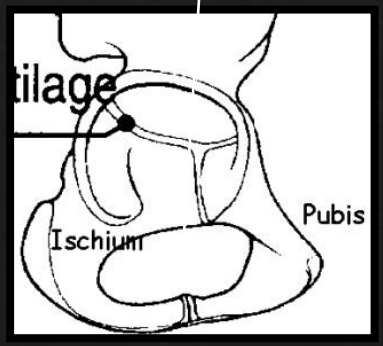

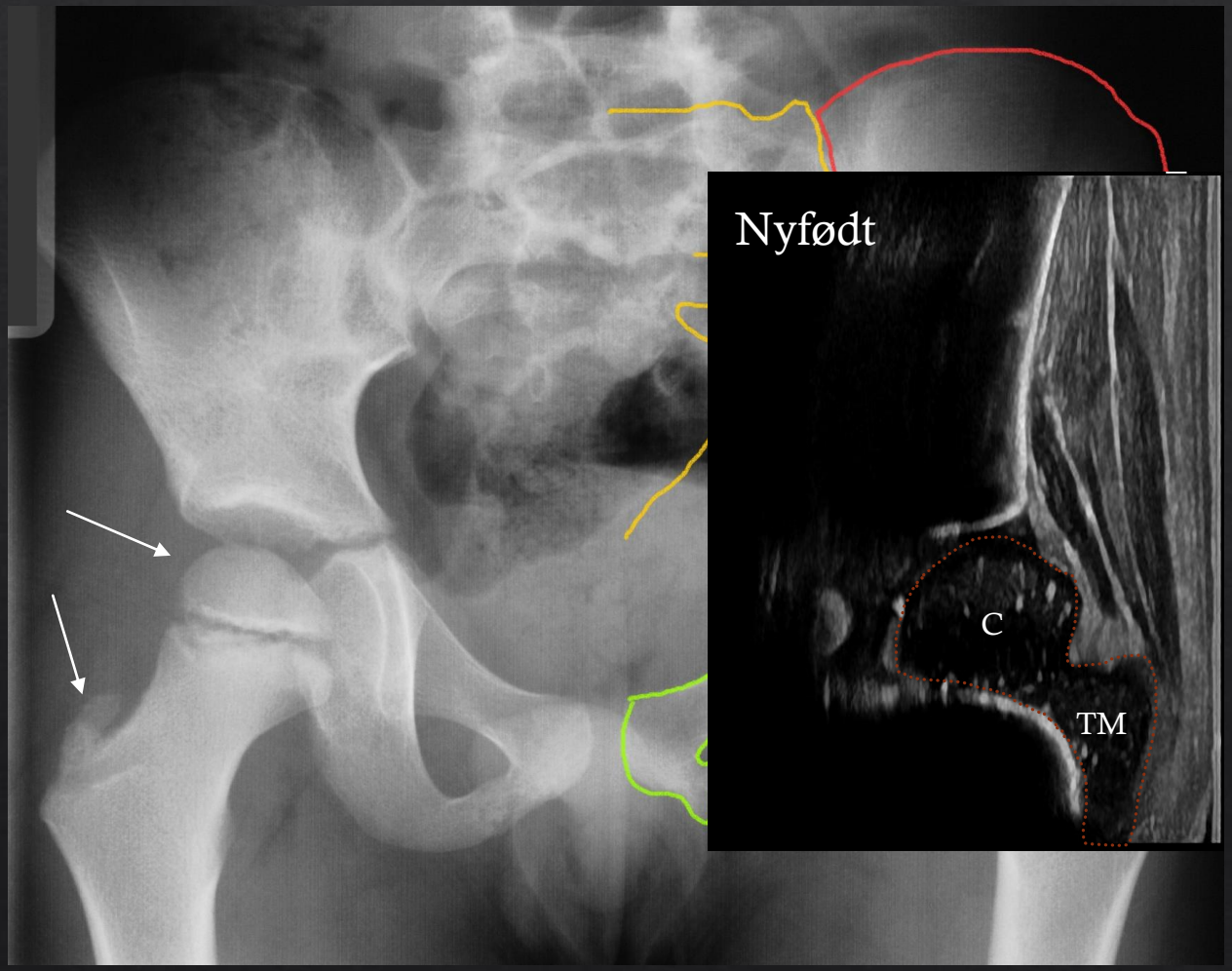

Svarende til trochanter major, ses apofysen anlagt. Bemærk på det indsatte UL billede (fra en nyfødt), at caput kernen og apofysen ossificerer i samme bruskmasse. Caputkernen i 3-6 månedersalderen, apofysen i 3-4 års alderen (disse tider angives dog meget forskelligt i forskellige lærebøger).
C: Caput femoris
TM: Trochanter major

Kvinde 38 år

Mand 17 år

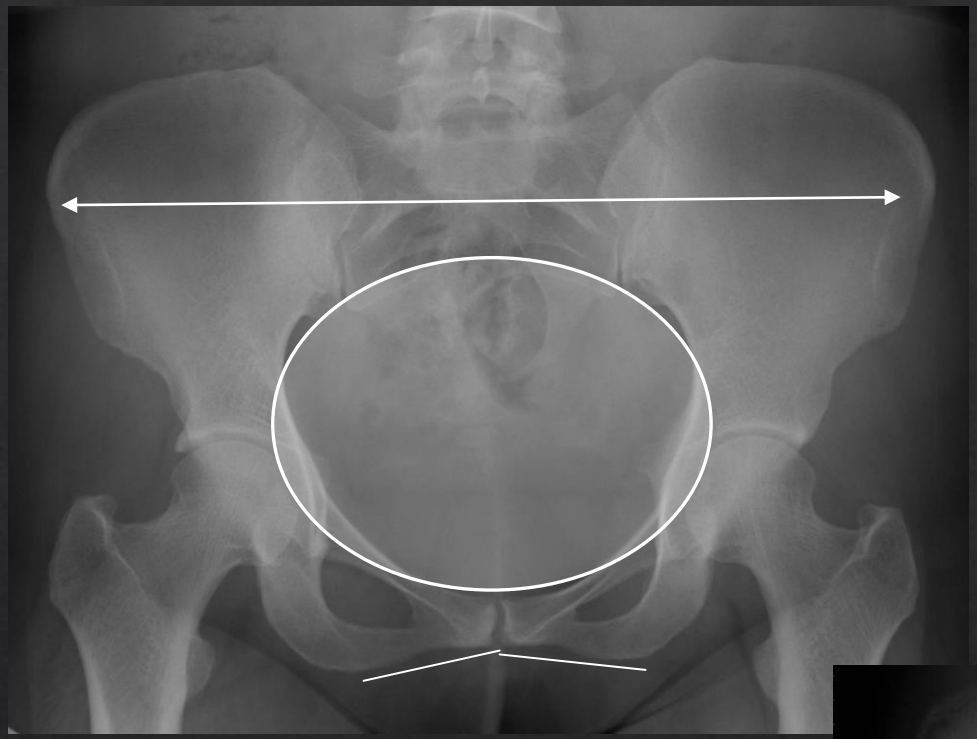

Kvinde 38 år

Kvindens bækken er generelt bredere og lavere. Der er mere plads i lille bækken, og større angulus subpubicus. Forskellene forklares ud fra det kvindelige bækkens funktion som fødselsvej.

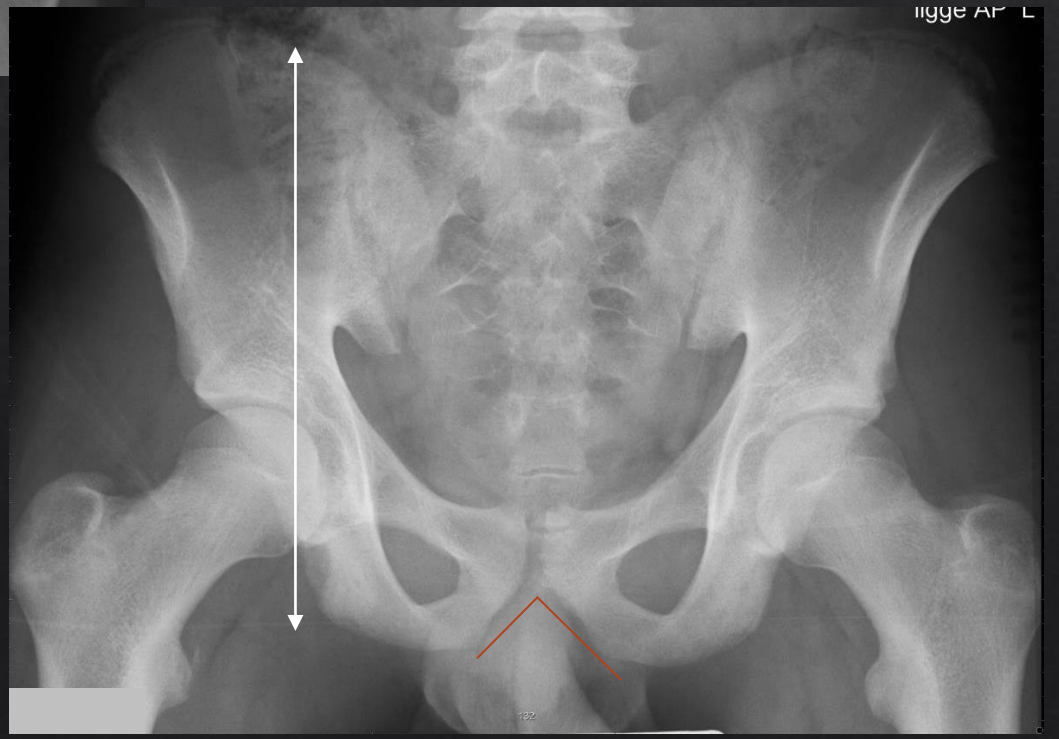

Mand 17 år

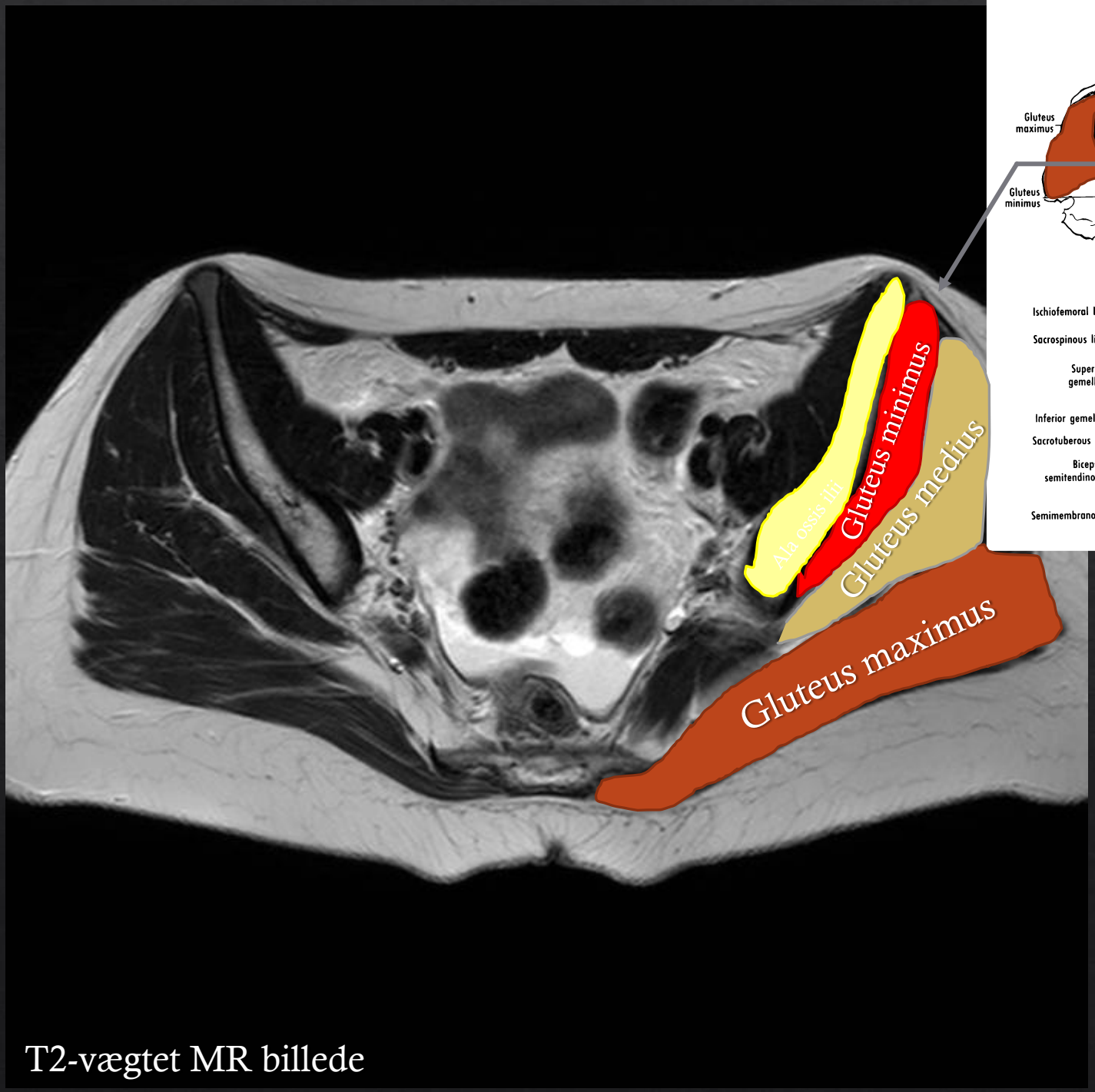

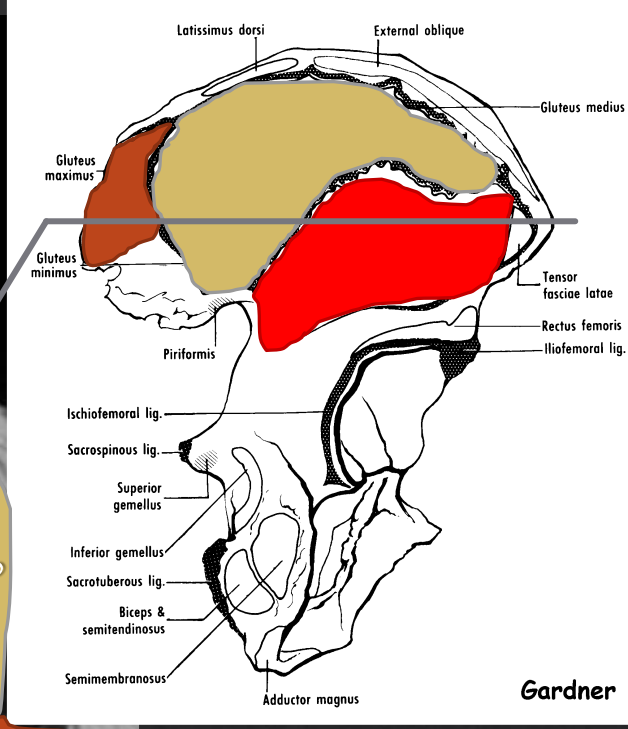

Gluteus maximus
Gluteus medius
Gluteus minimus

T2-vægtet MR billede

1
2
3
4
5
6
7
8
9
10

1) M. rectus abdominis
2) M. iliacus
3) M. psoas major
4) Vasa iliaca ext.
5) M. piriformis
6) Rectum
7) Ala ossis ilii
8) M. gluteus maximus
9) M. gluteus medius
10) M. gluteus minimus

M. piriformis

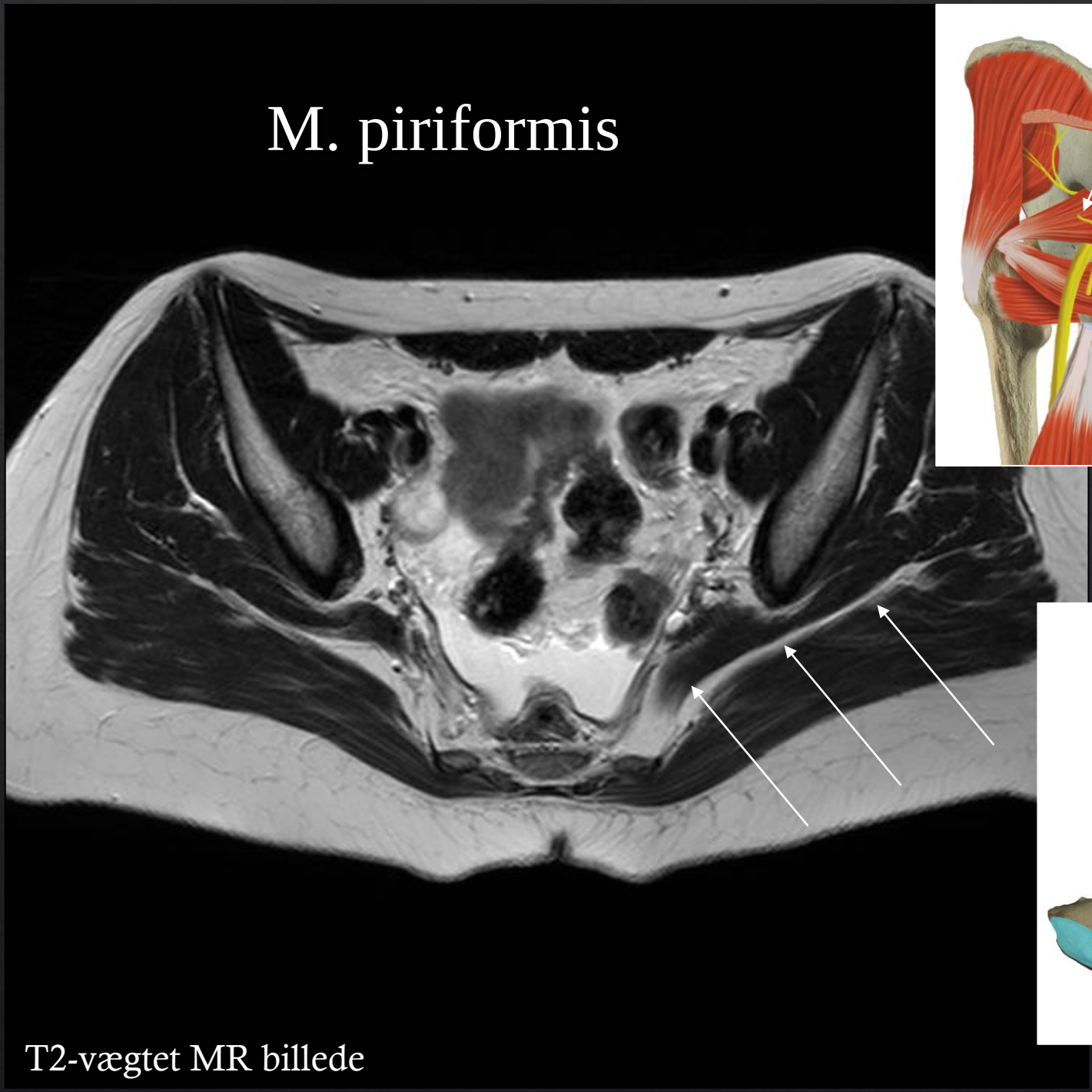

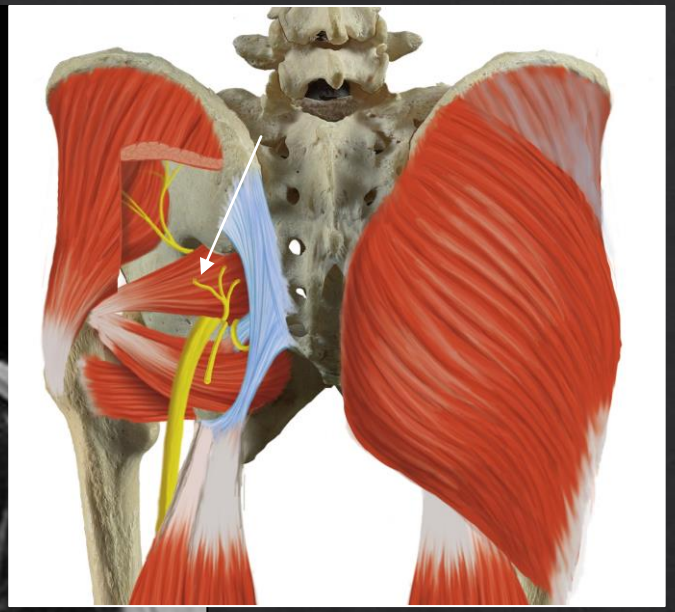

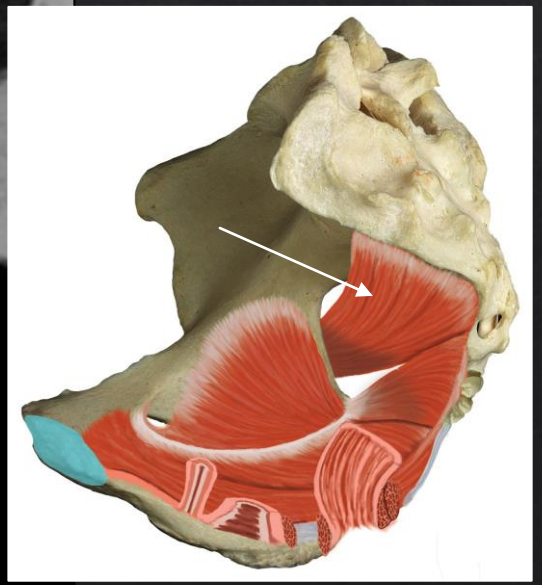

T2-vægtet MR billede

M. obturatorius externus et internus

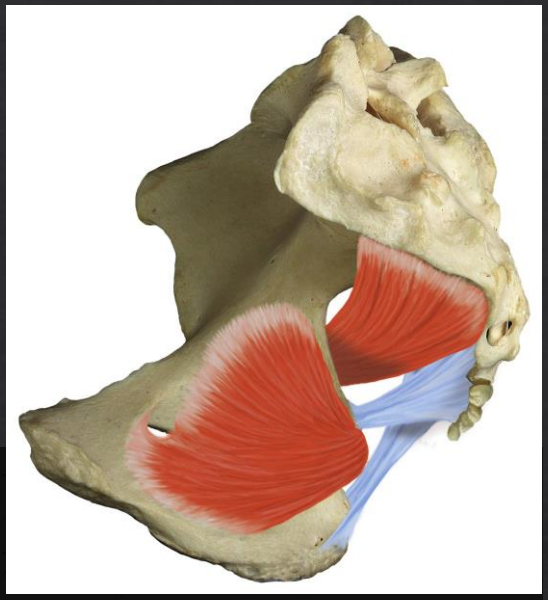

CT

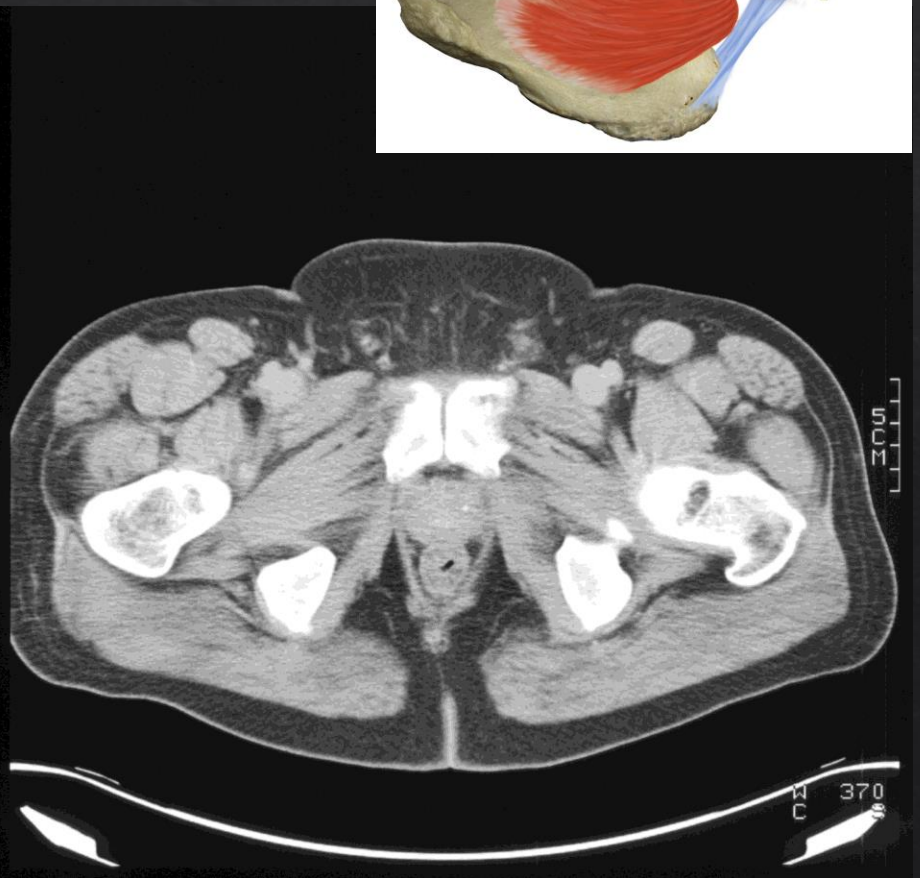

M. obturatorius externus

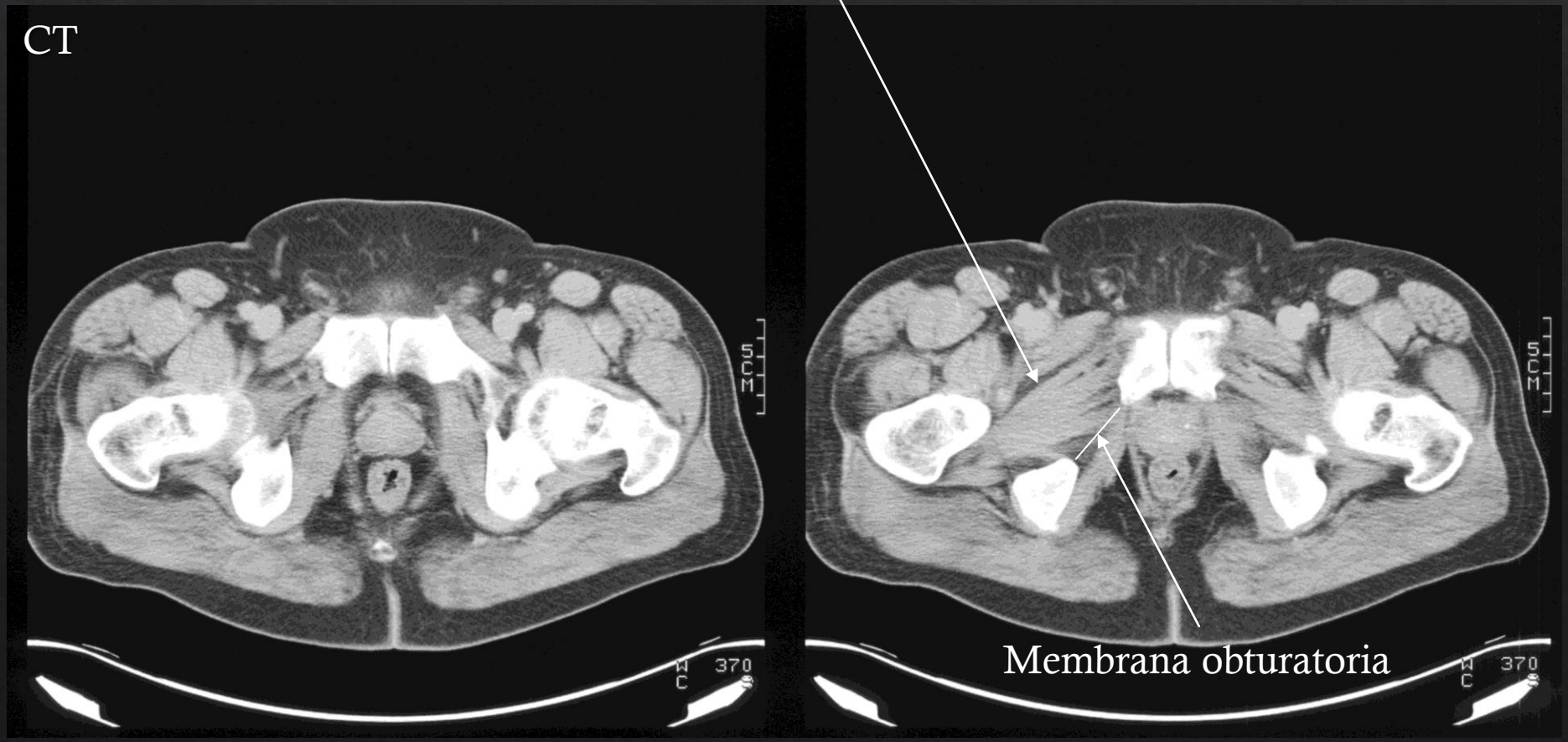

M. obturatorius internus

N. ischiadicus

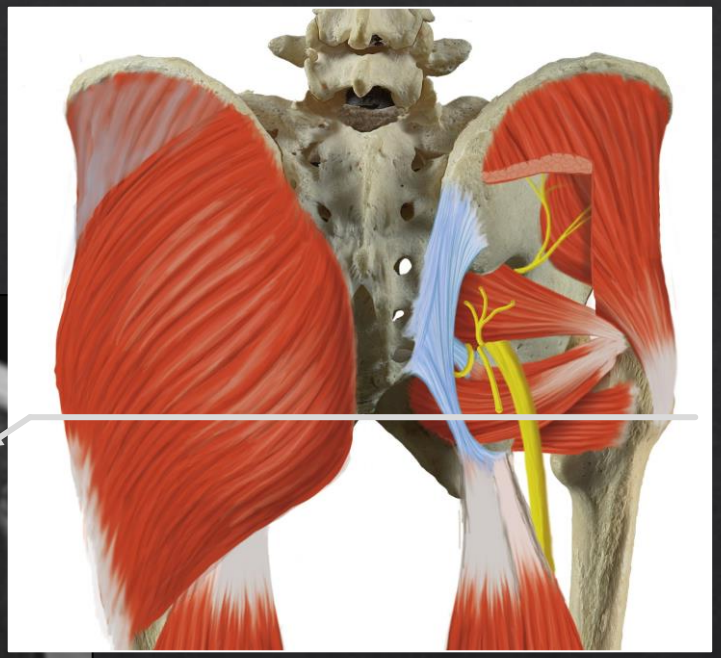

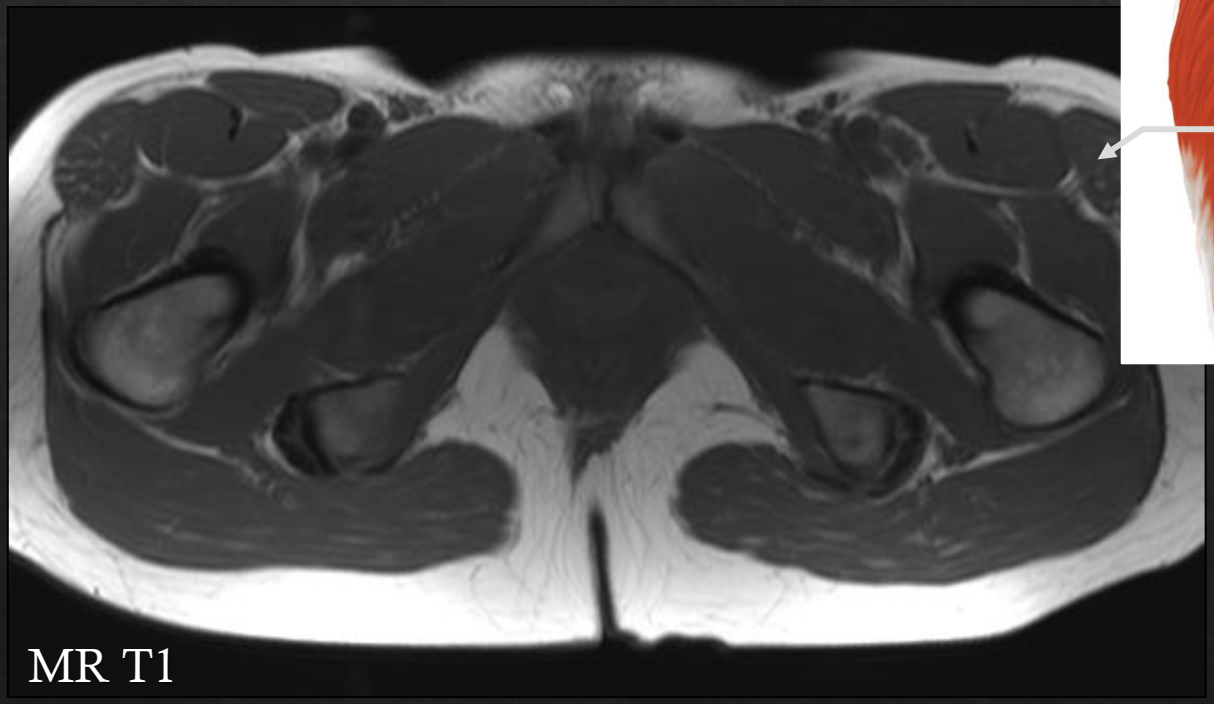

N. ischiadicus

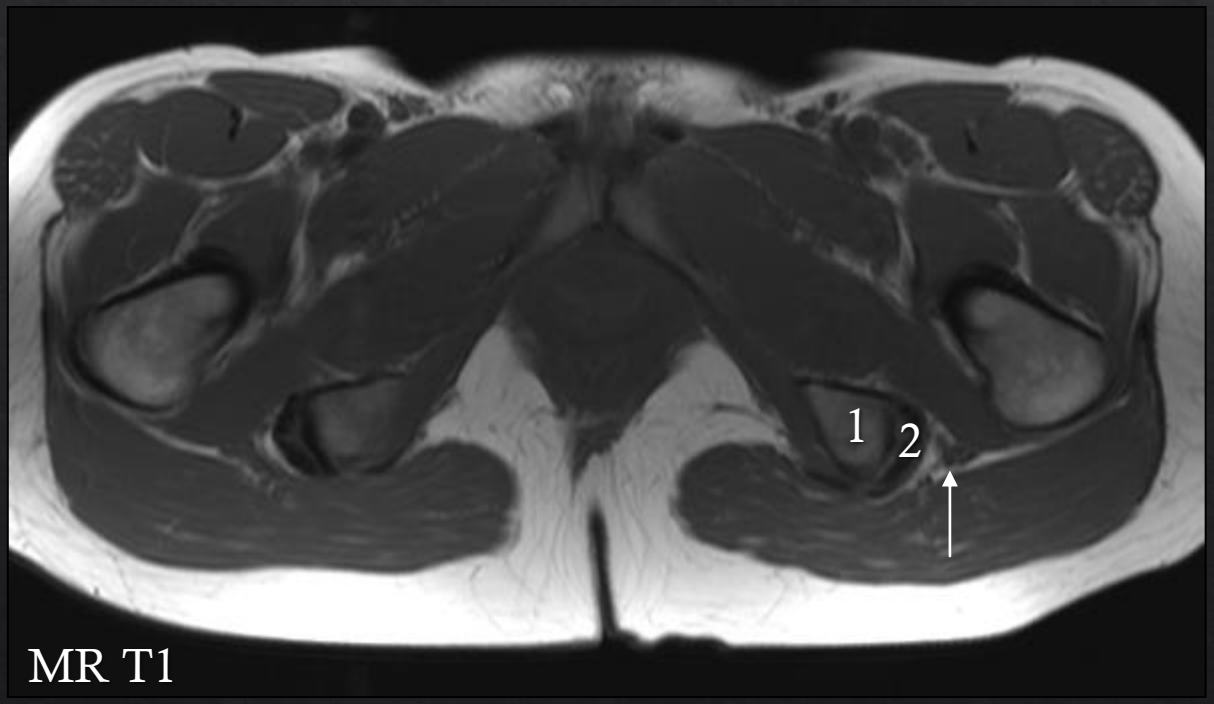

Nerven er beliggende i et lille spatium indeholdende fedtvæv (hvidt på en T1 vægtet sekvens) der kontraster godt mod nerven

1) Tuber ischiadicum
2) Udspringet af den ischiocrurale gruppe: M. semimembranosus, semitendinosus samt caput breve af biceps femoris (senevæv er sort).

Forløb af:

- M. gluteus maximus?
- M. gluteus medius?
- M. gluteus minimus?

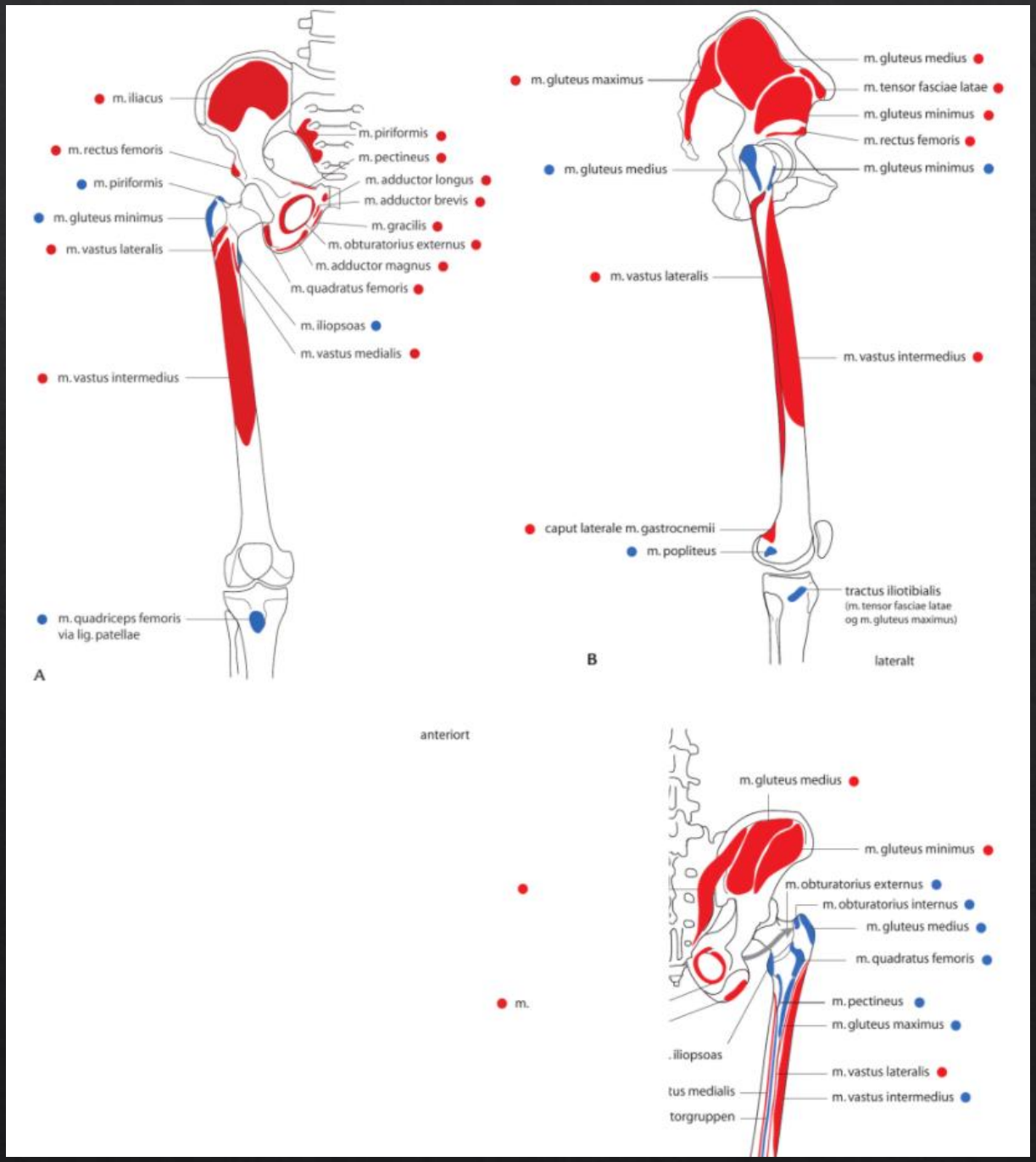
m. iliacus
m. rectus femoris
m. piriformis
m. gluteus minimus
m. vastus lateralis
m. vastus intermedius
m. quadriceps femoris via lig. patellae
m. piriformis
m. pectineus
m. adductor longus
m. adductor brevis
m. gracilis
m. obturatorius externus
m. adductor magnus
m. quadratus femoris
m. iliopsoas
m. vastus medialis
A
m. gluteus maximus
m. gluteus medius
m. vastus lateralis
caput laterale m. gastrocnemii
m. popliteus
m. gluteus medius
m. tensor fasciae latae
m. gluteus minimus
m. rectus femoris
m. gluteus minimus
m. vastus intermedius
tractus iliotibialis
(m. tensor fasciae latae
og m. gluteus maximus)
B
lateralt
anteriort
m.
m. gluteus medius
m. gluteus minimus
m. obturatorius externus
m. obturatorius internus
m. gluteus medius
m. quadratus femoris
m. pectineus
m. gluteus maximus
. iliopsoas
m. vastus lateralis
tus medialis
m. vastus intermedius
torgruppen

MR: Transvers T1 vægtet sekvens af bækken og femora

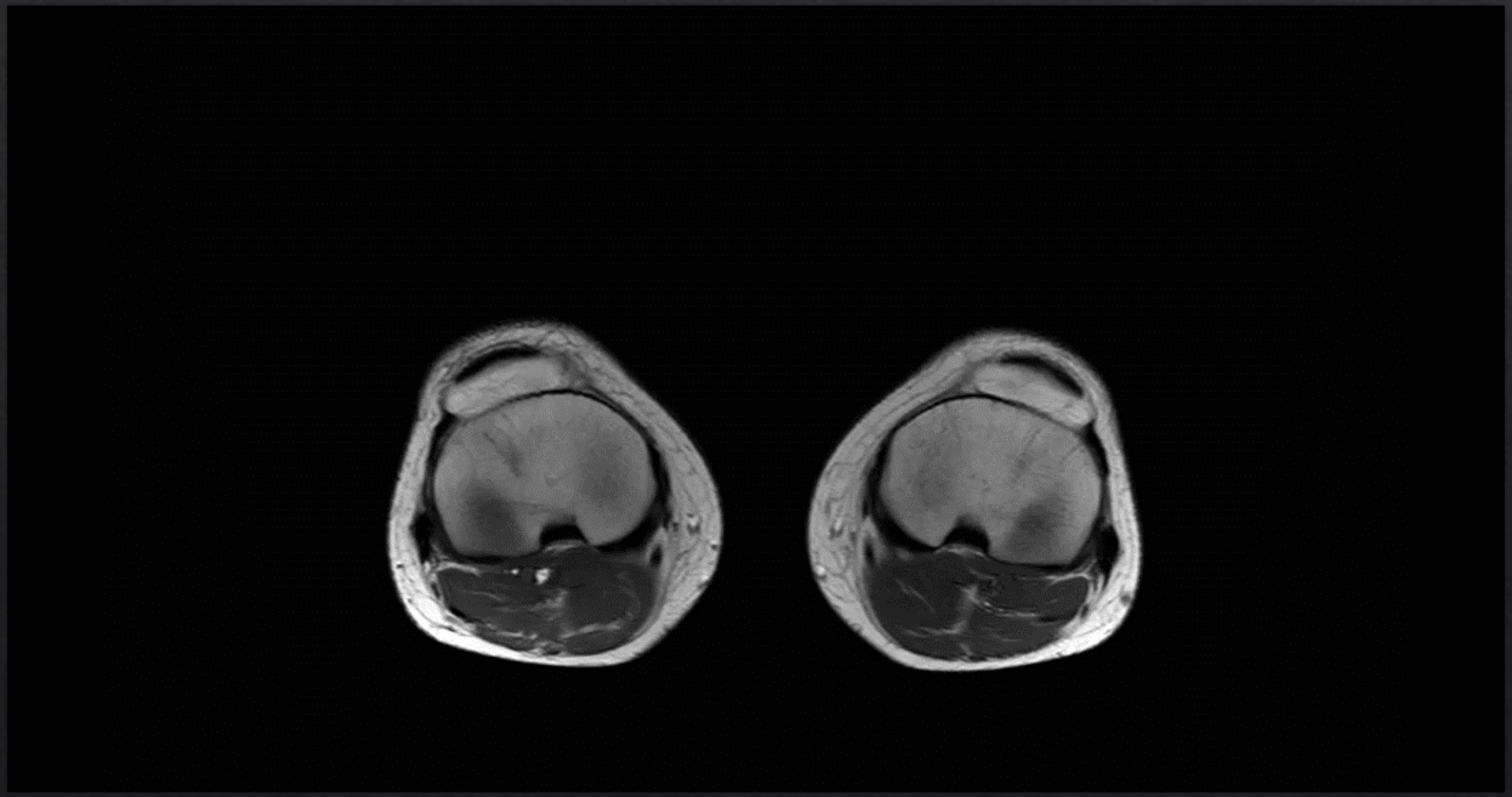

Hofteled

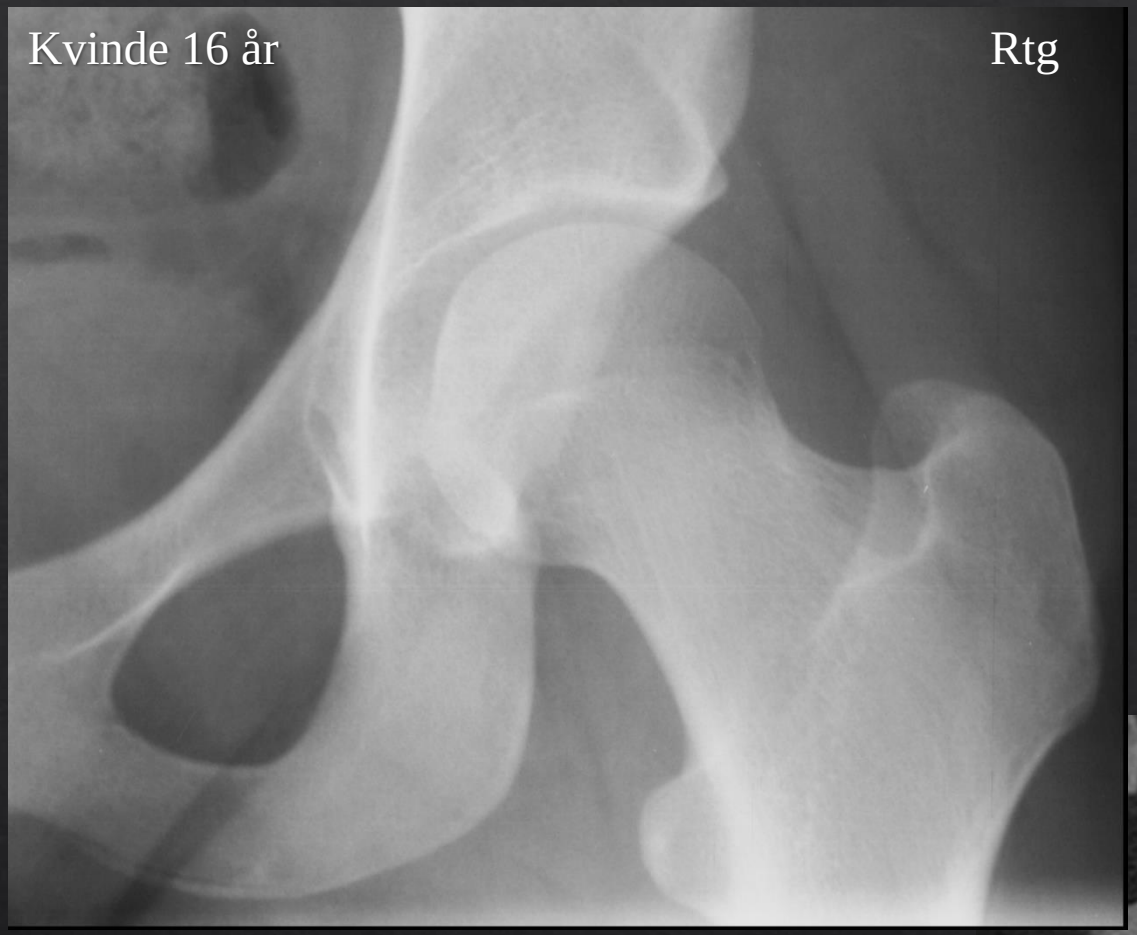
Kvinde 16 år
Rtg

Kvinde 14 år
MR, T1

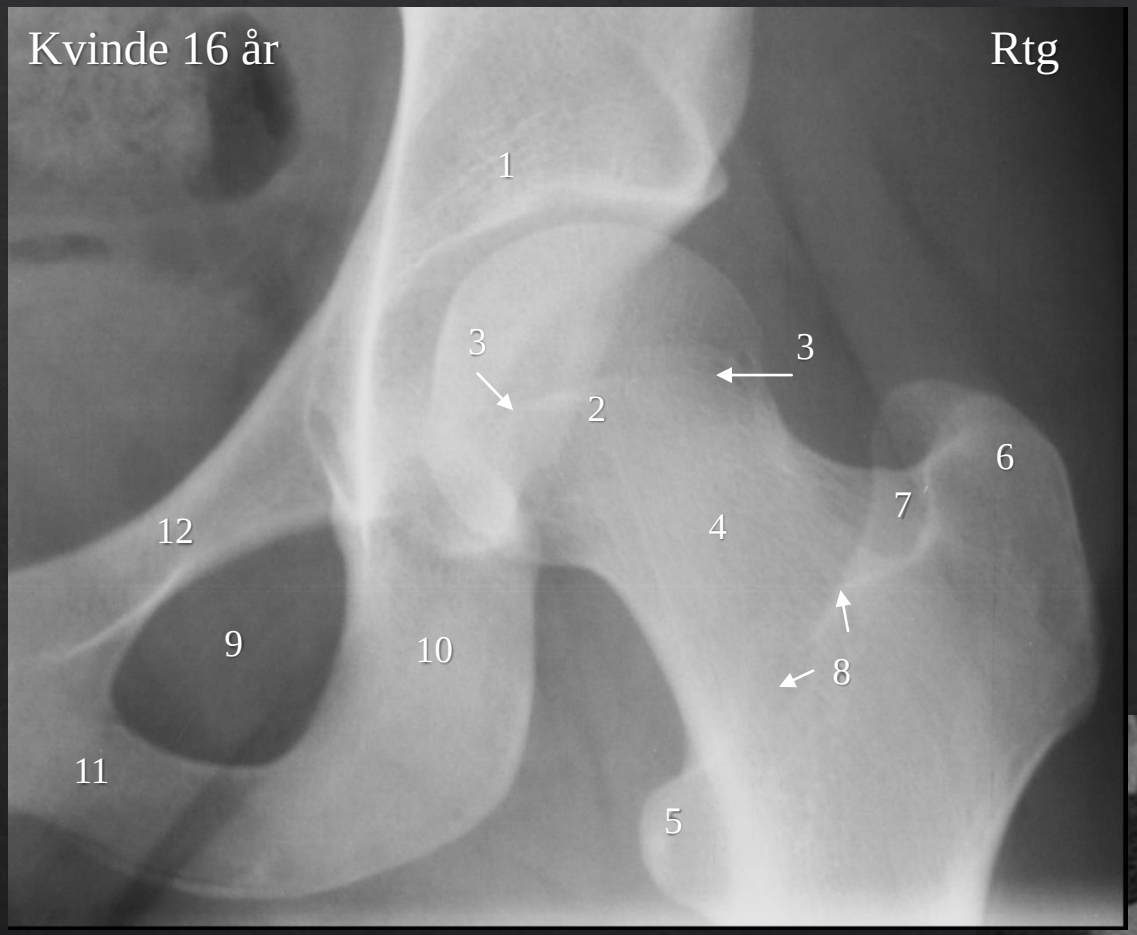
Kvinde 16 år
Rtg
1
3
3
2
6
7
12
4
9
10
8
11
5

Kvinde 14 år
MR, T1

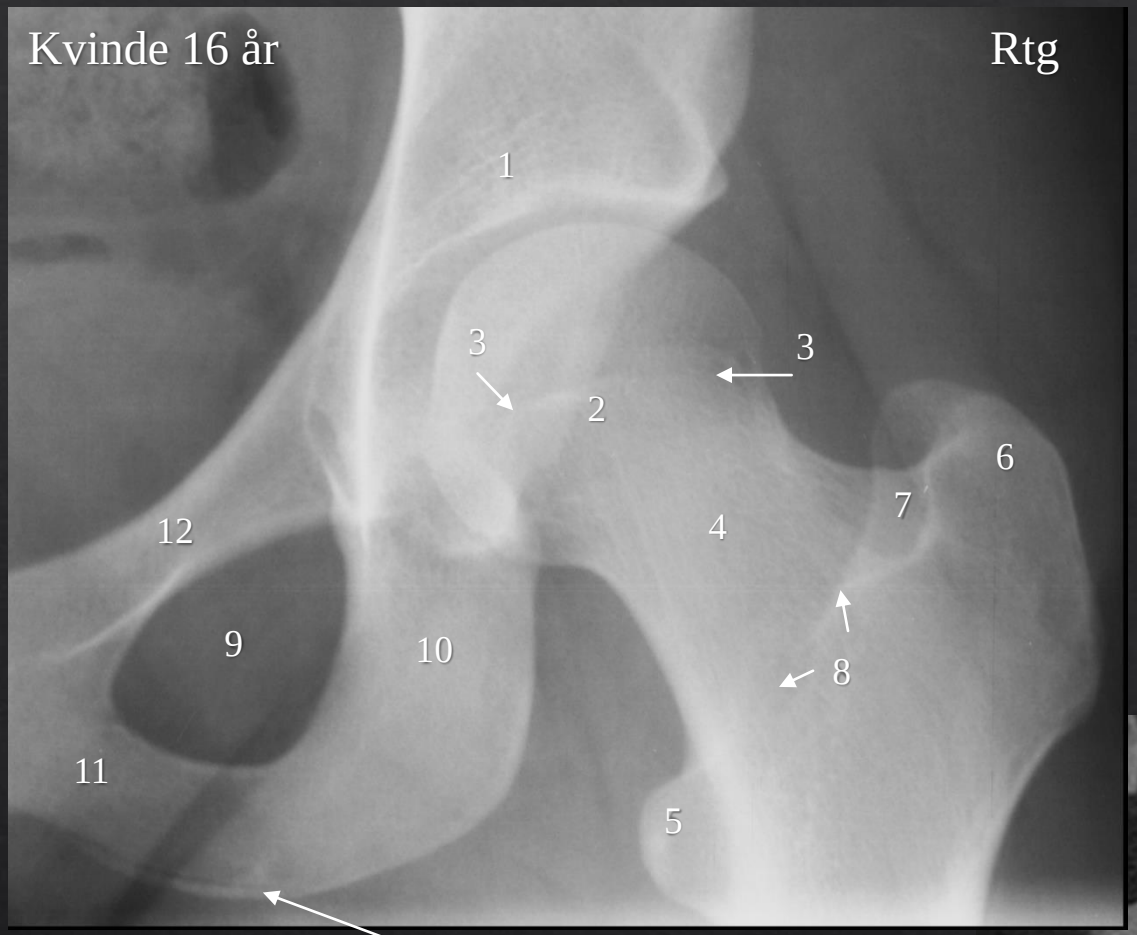

Acetabulum (1)
Caput femoris (2)
Epifyse arret (3)
Collum femoris (4)
Trochanter minor (5)
Trochanter major (6)
Fossa trochanterica (7)
Crista intertrochanterica (8)
Foramen obturatum (9)
Ramus ossis ischii (10)
Ramus inf. ossis pubis (11)
Ramus sup. Ossis pubis (12)

Tuber ischiadicum apofysen er ossificeret, men endnu ikke fusioneret fuldstændig med den øvrige del af knoglen.

Bemærk at knoglemarven i såvel caput kernen som trochanter major er med højere signal (mere hvid), og således med større fedtindhold (gul knoglemarv) end øvrige proximale femur.

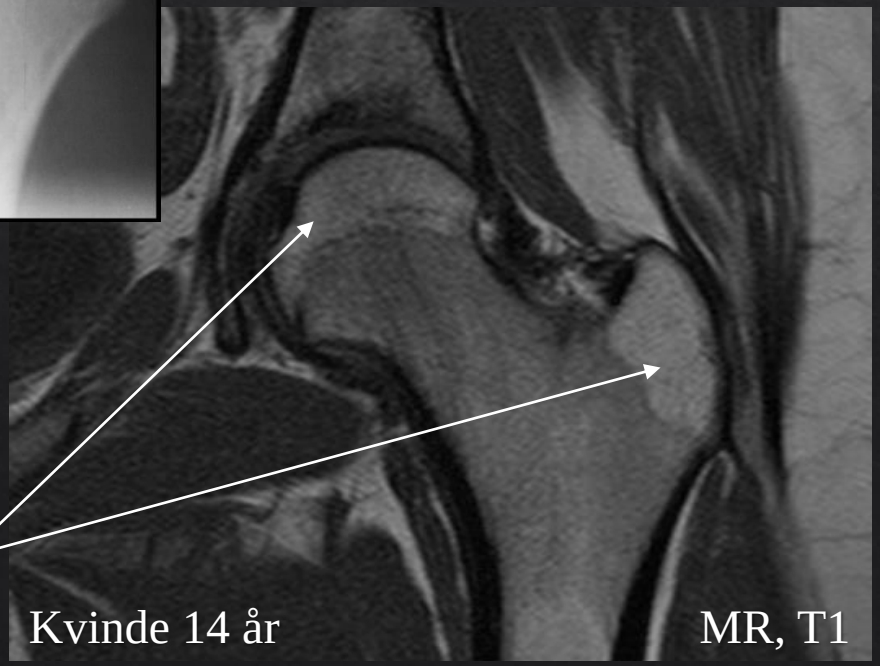

Medfødt hofteledskred (Medfødt hofteledsluksation)

Afvigelse fra normal anatomi?

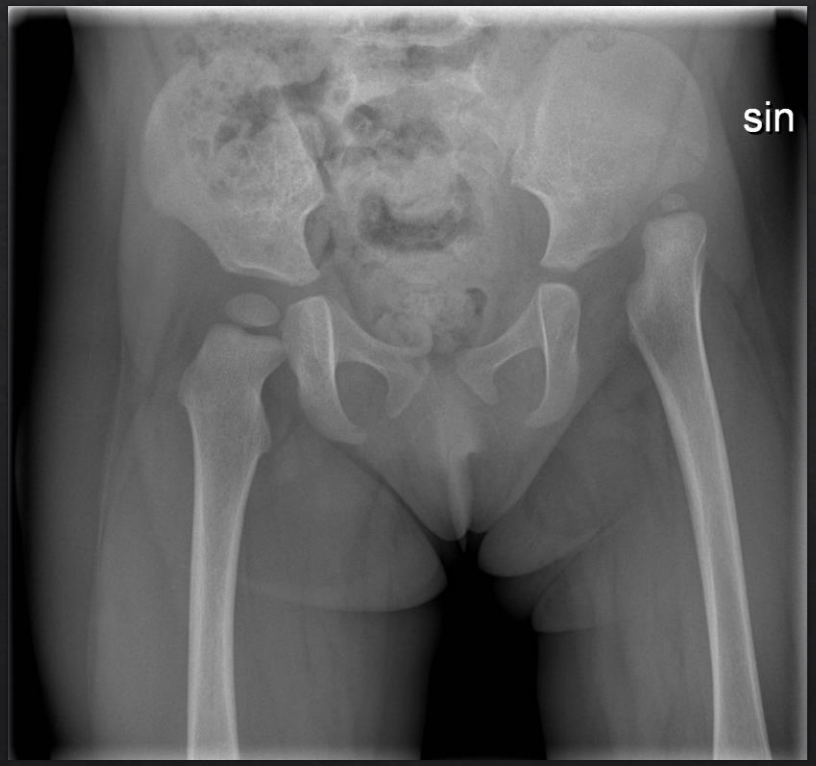

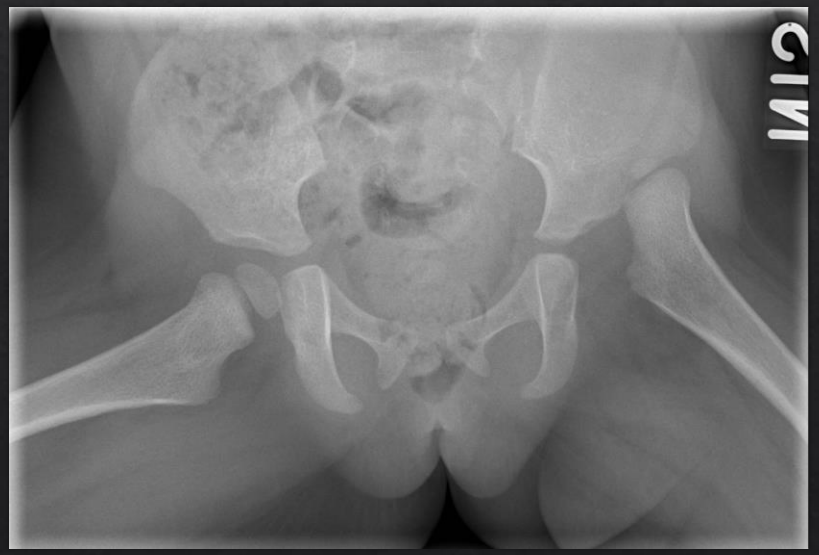

Medfødt hofteledskred

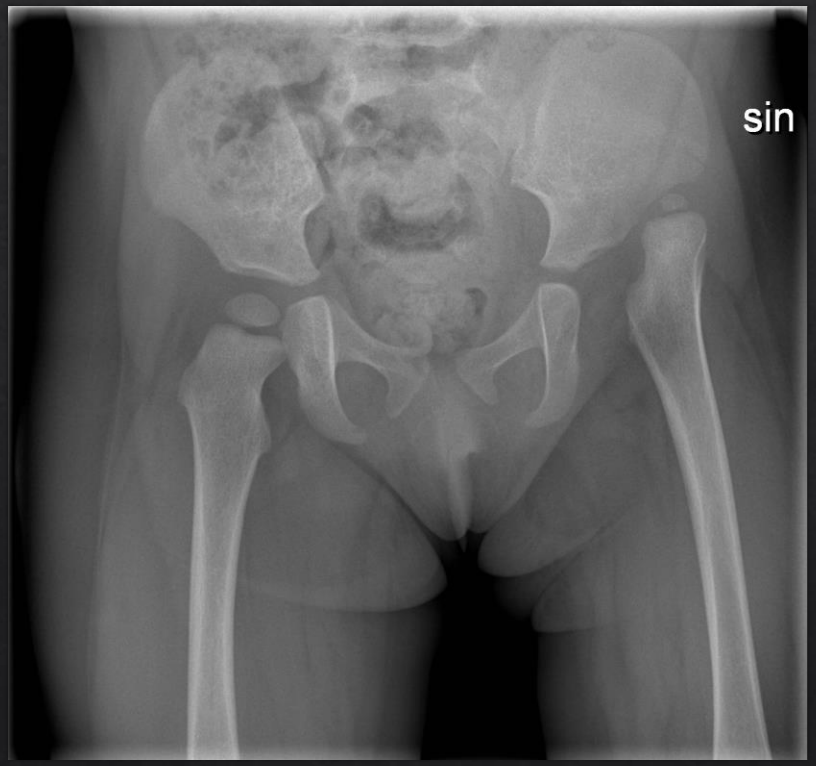

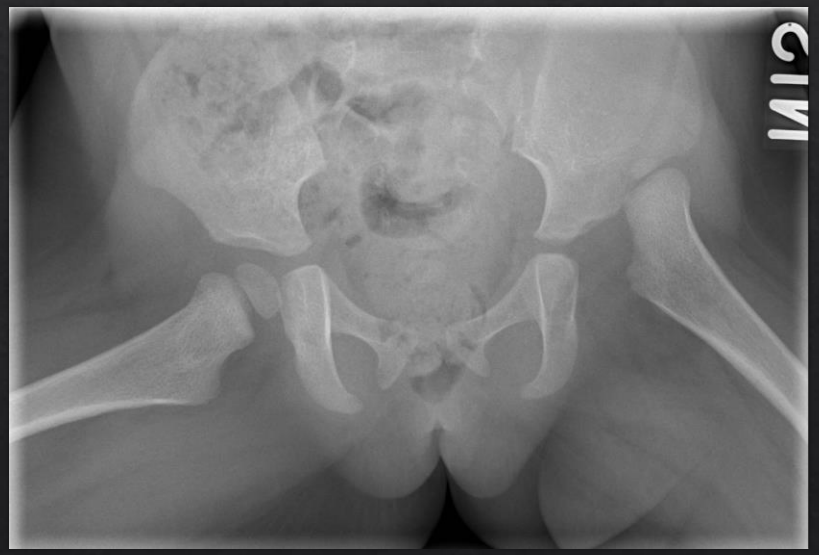

Medfødt hofteledskred

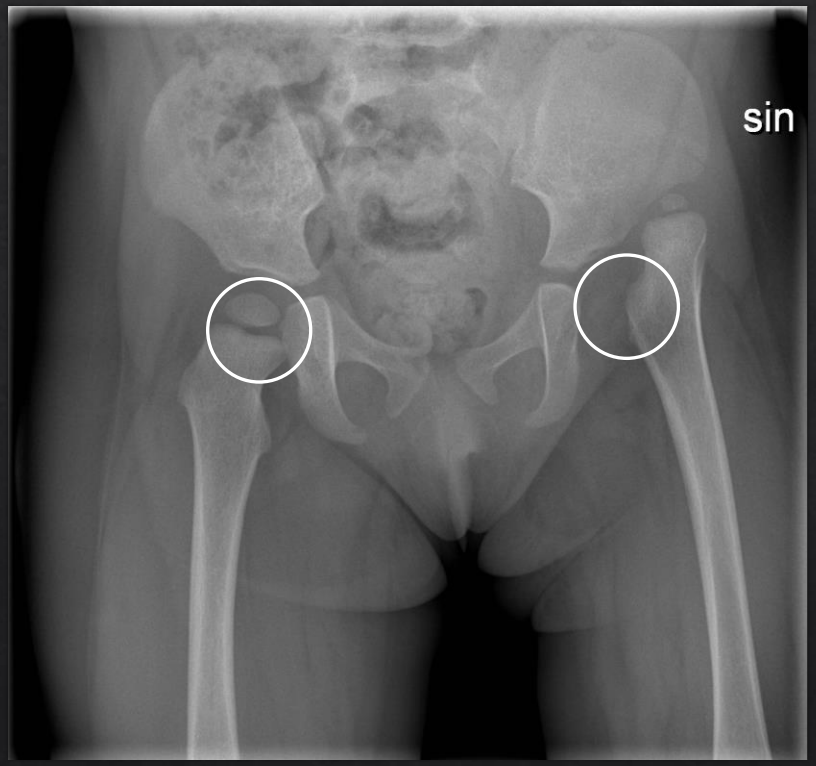

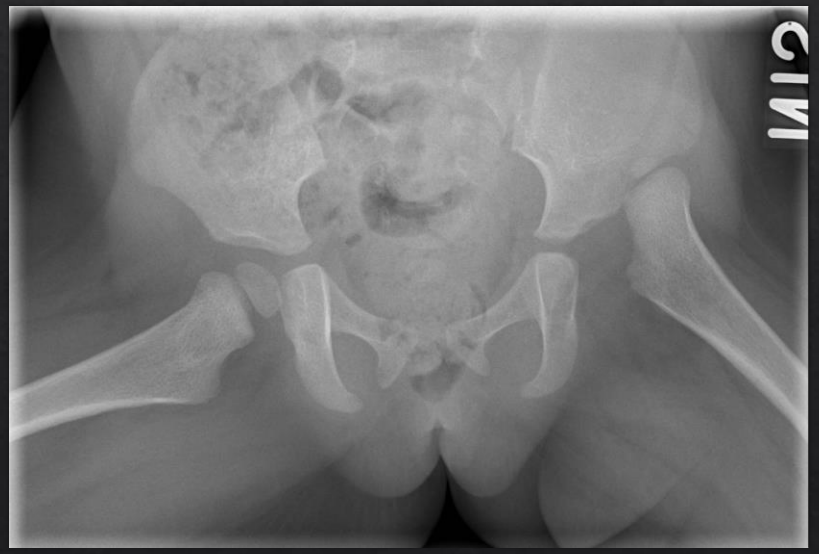

Normal højre hofte, ledskred på venstre side. Dette er ikke medfødt i alle tilfælde, og kaldes mere præcist DDH (developmental dysplasia of the hip), med egentlig ledskred som her i de sværeste tilfælde.

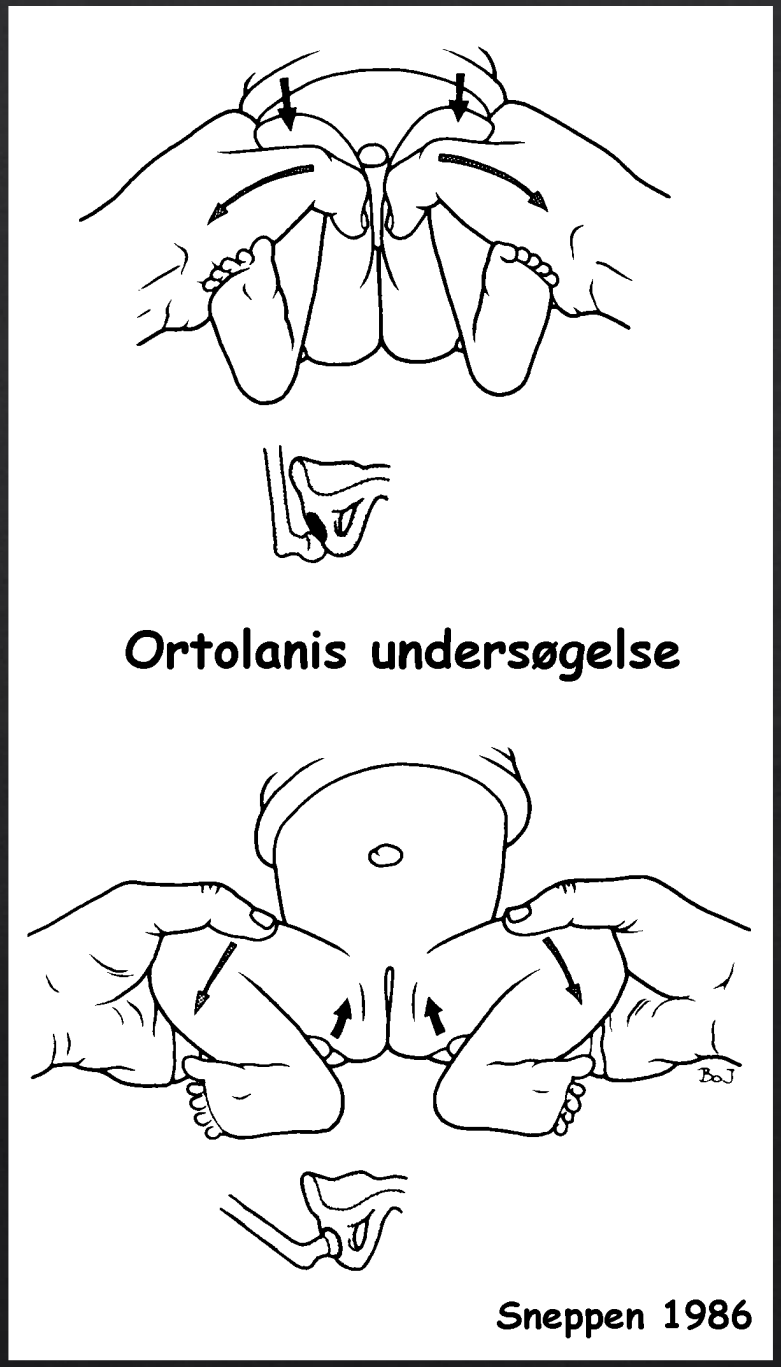

Klinisk undersøgelse for medfødt hofteledskred

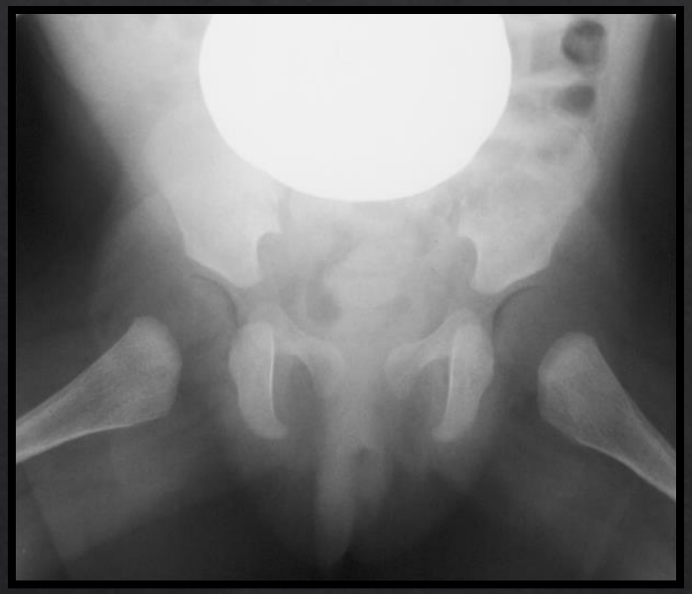

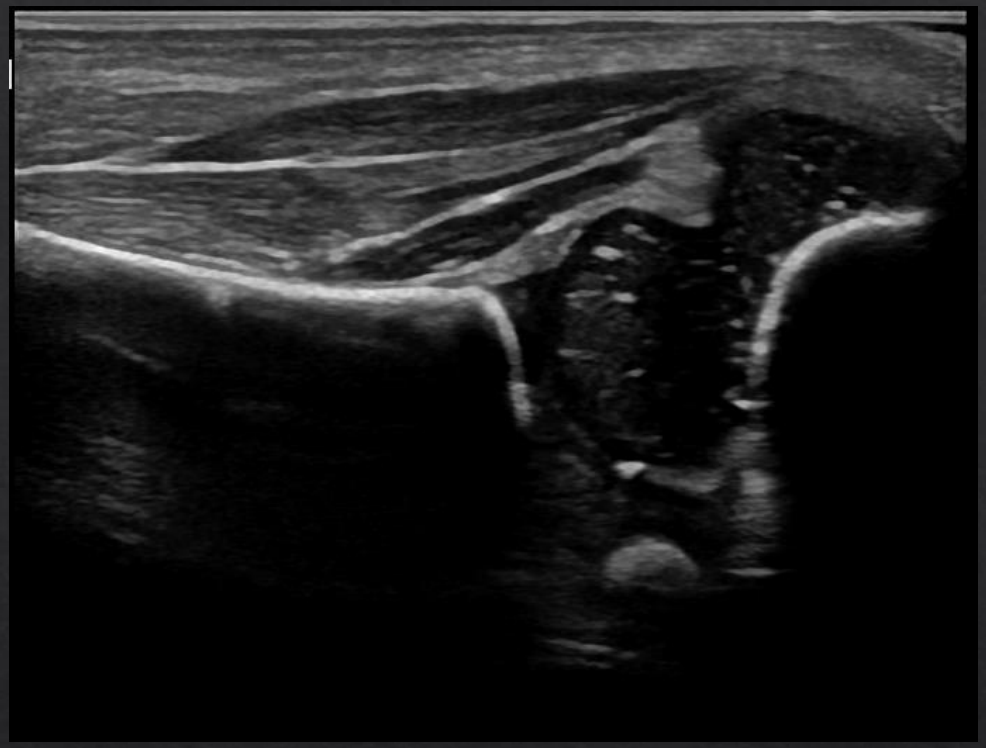

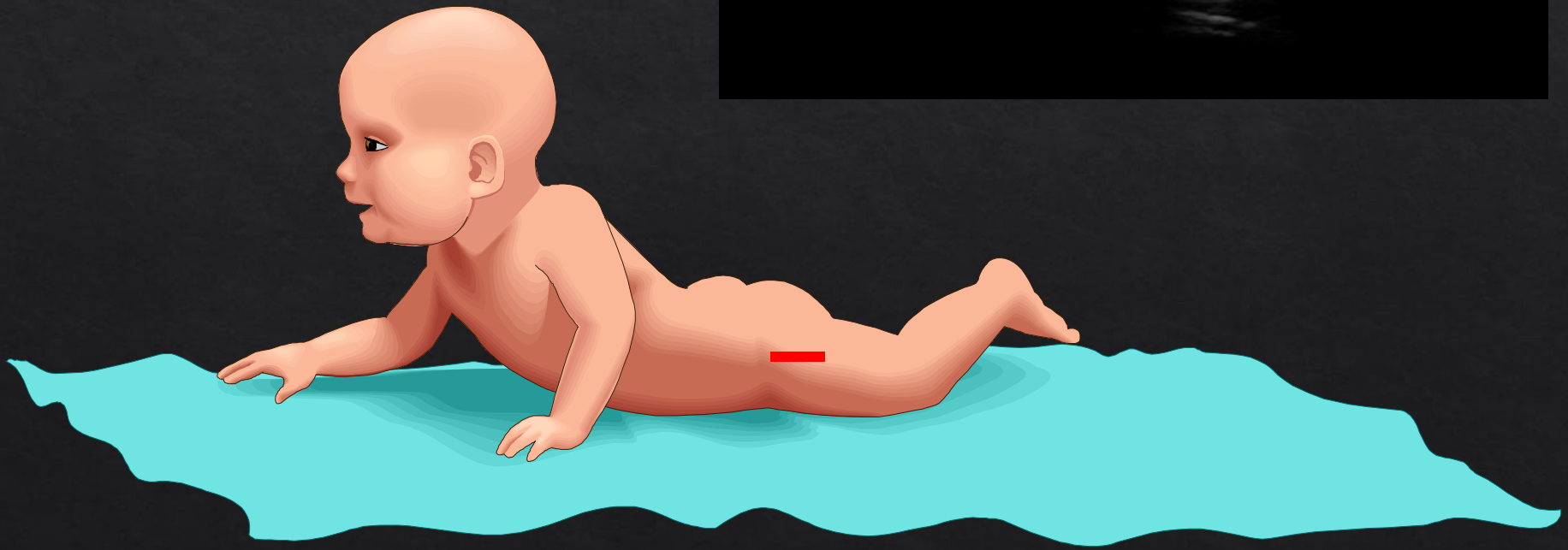

Vacuum fænomen i hoften. Der kan skabes undertryk i hoften, hvis benet holdes og barnet trækker imod, således at der kommer luft i leddet. Derved ses afgrænsningen af caput tydeligt, da luft er et godt kontraststof.

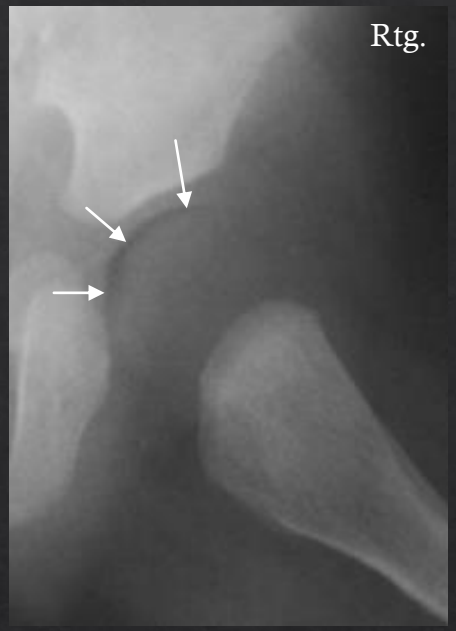

Røntgenoptagelsen er en Lauensteins projektion (flexion og udadroation i hoften) og således ikke helt sammenlignelig med billedt fra skanningen

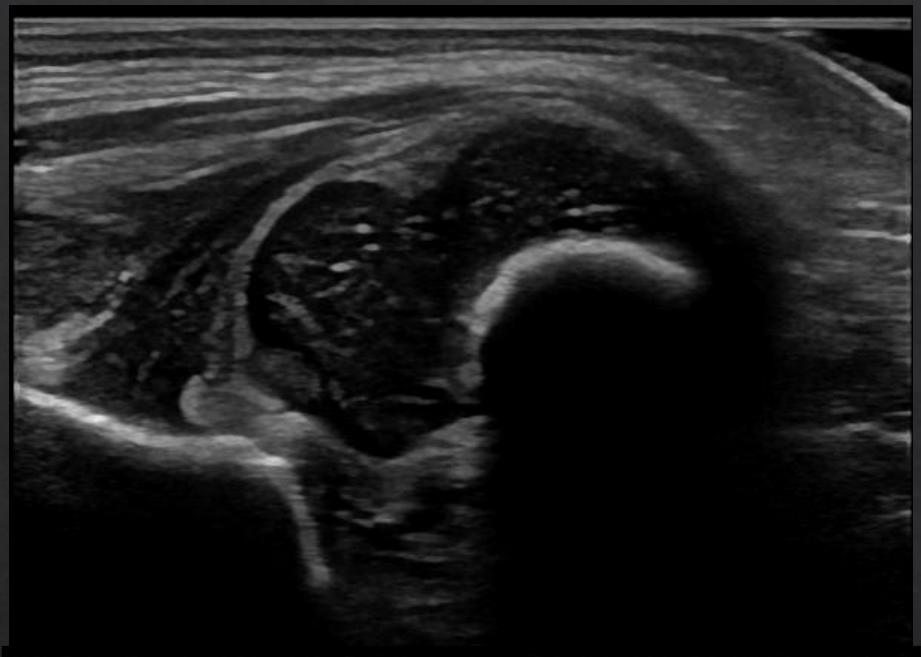

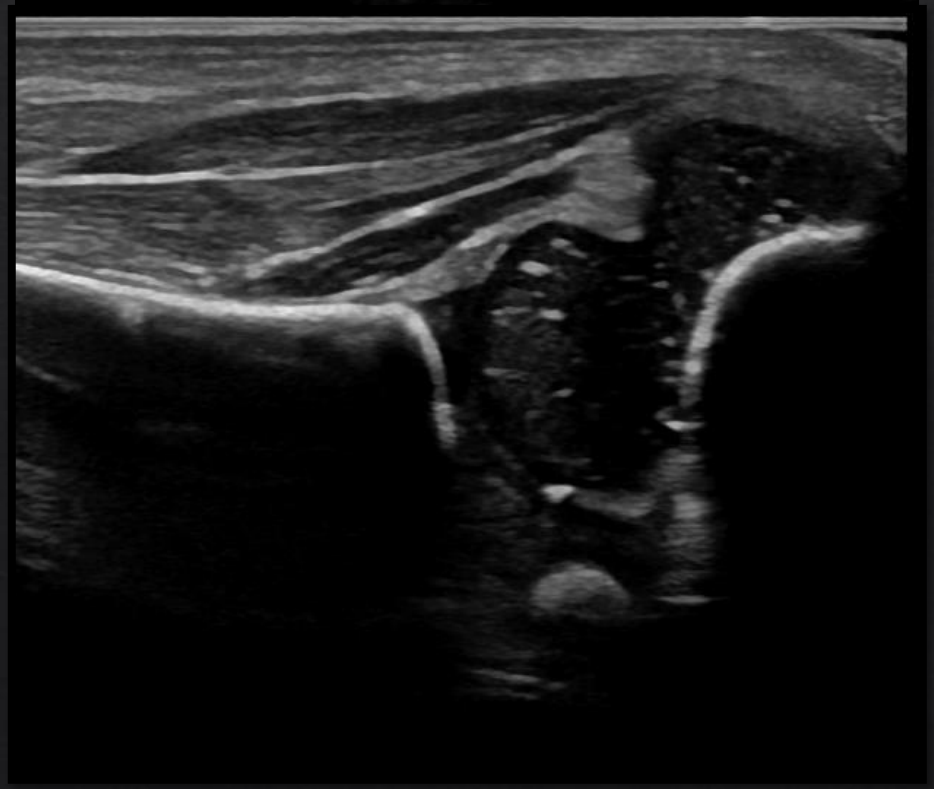

Lukseret hofte

Normal hofte

Eksempel på behandling

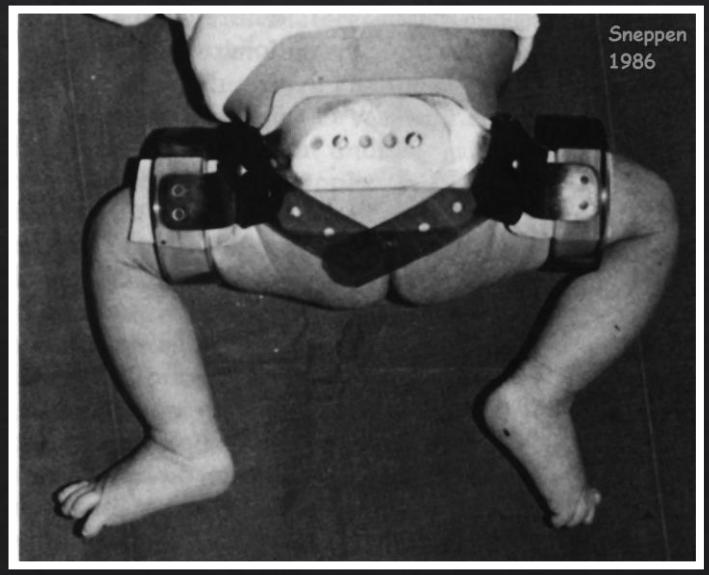

Ultralydskanning af en nyfødts hofte.

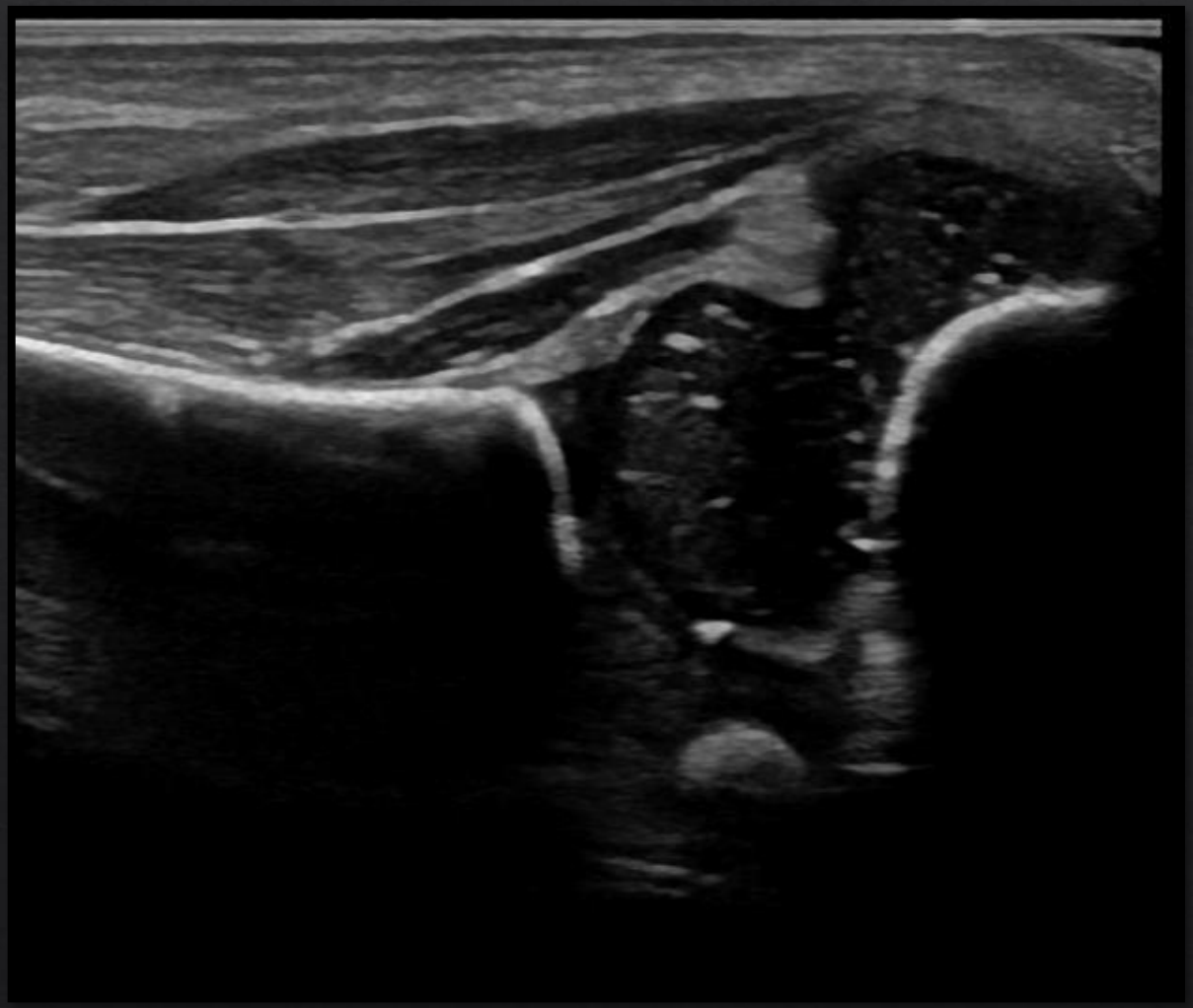

Ultralydskanning af en nyfødts hofte.

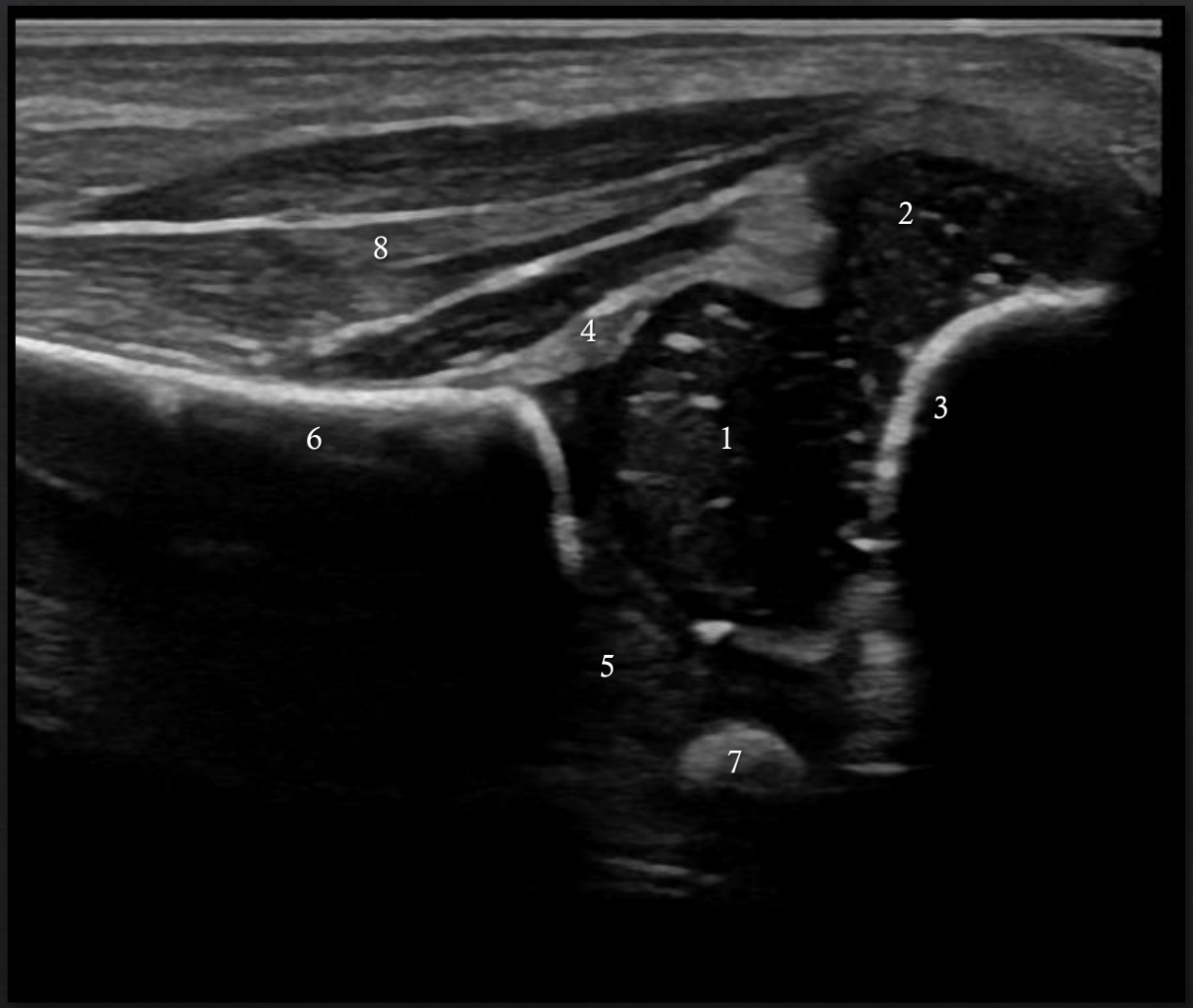

Ultralydskanning af en nyfødts hofte.

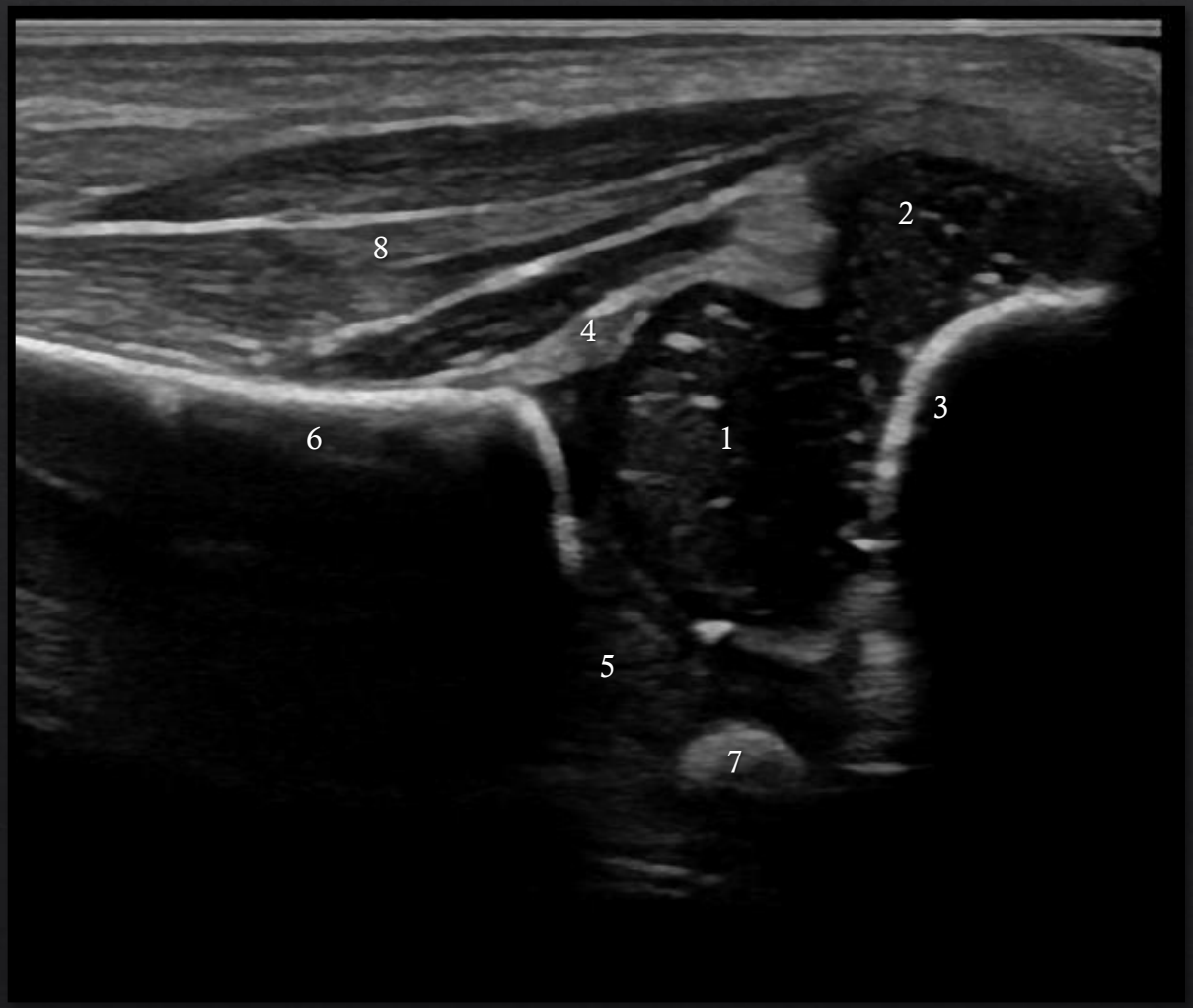

1) Caput femoris
2) Trochanter major
3) Femur metafysen

Acetabulum:

4) Labrum
5) Synchondrosen

6) Os ilium (corticalis lateralt)
7) Os pubis (ossifikationscenter)
8) Gluteal muskulaturen

Knogletrabekler

92-årig mand

34-årig kvinde

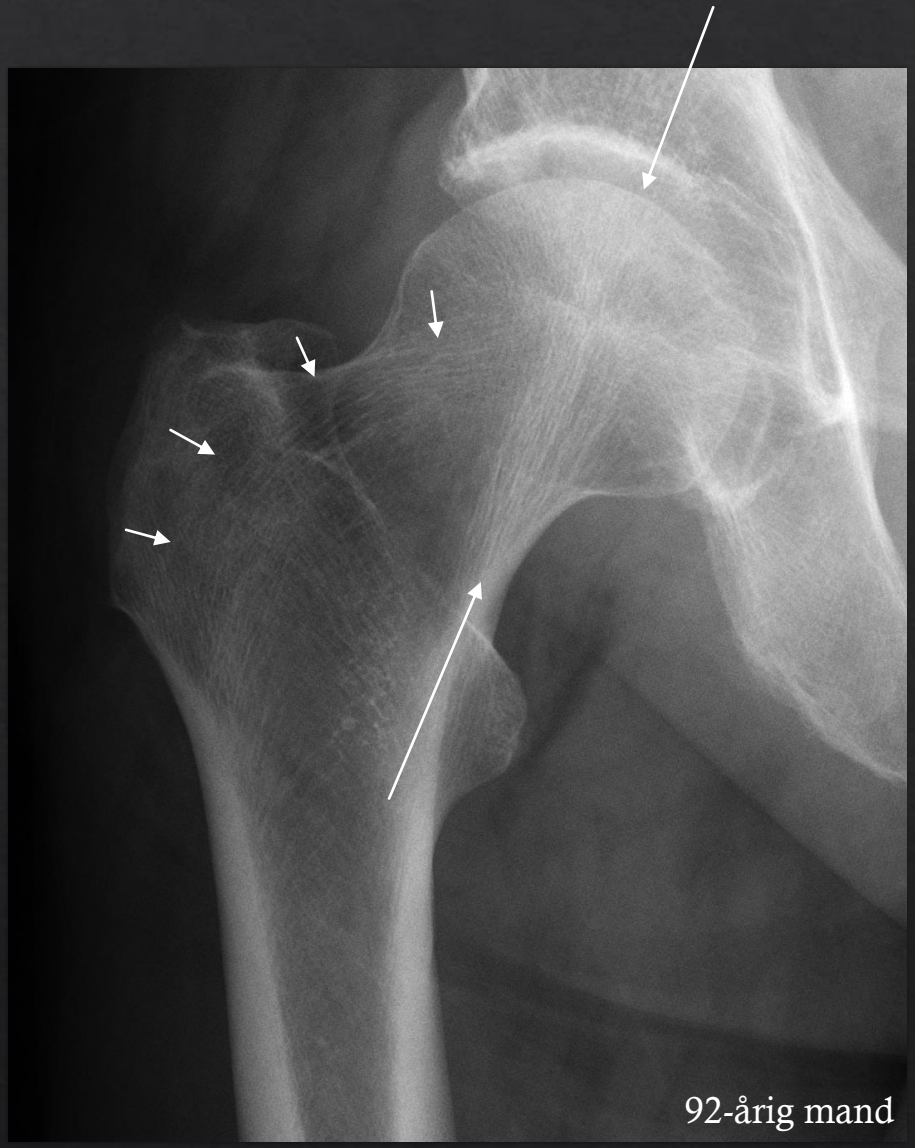

Pga. alderbetinget tab af knoglemasse og trabekler, er de tilbageværende tydeligere

Fractura collum femoris

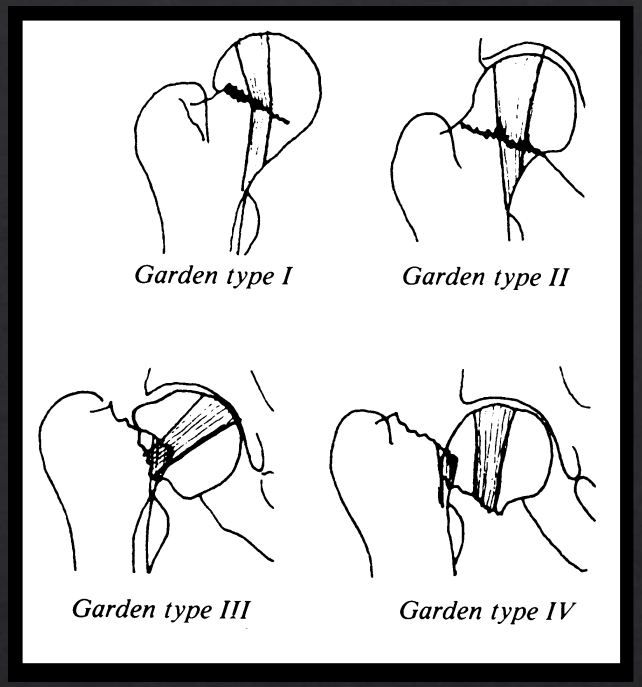
Garden type I
Garden type II
Garden type III
Garden type IV

Valgus vinkling

Collum femoris fraktur med caput femoris vinklet i valgus, og således et relativt stabilt brud der kan behandles med isættelse af skruer.

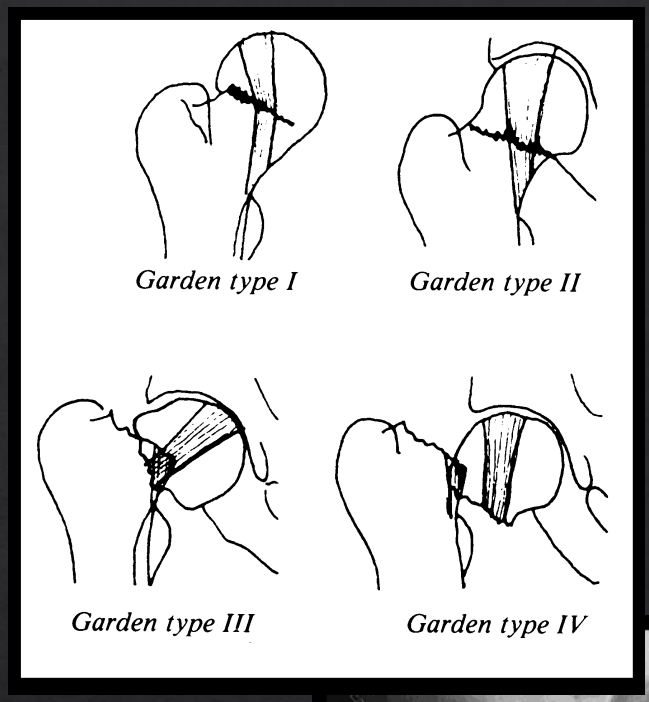
Garden type I
Garden type II
Garden type III
Garden type IV

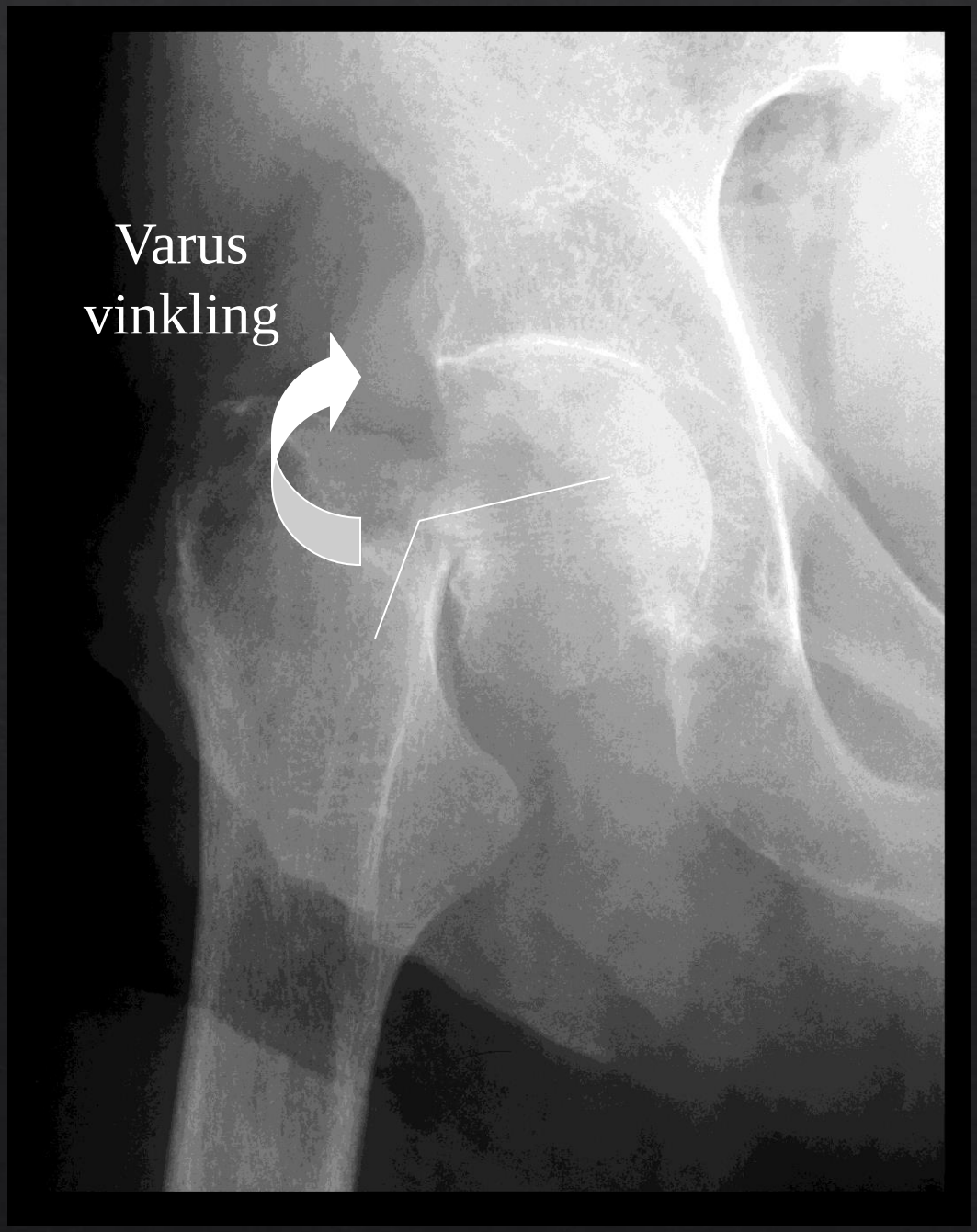

Collum femoris fraktur med caput vinklet i varus og her også afglidning af caput femoris. Karforsyningen til caput femoris er sandsynligvis gået tabt, så hvis man udfører indgrebet ved at rykke caput på plads og så indsætte skruer, vil man risikere se caput falde sammen. Derfor er der fra starten isat en halvprotese (hemialloplastik)



Nyfødt: 150 gr.
Voksen: 125 (120-130) gr.
Gammel: 120 gr.

Coxa vara (reduceret vinkel)
Coxa valga (øget vinkel)

Efter inspiration fra Alan E. Oestreichs
”Growth of th pediatric skeleton”

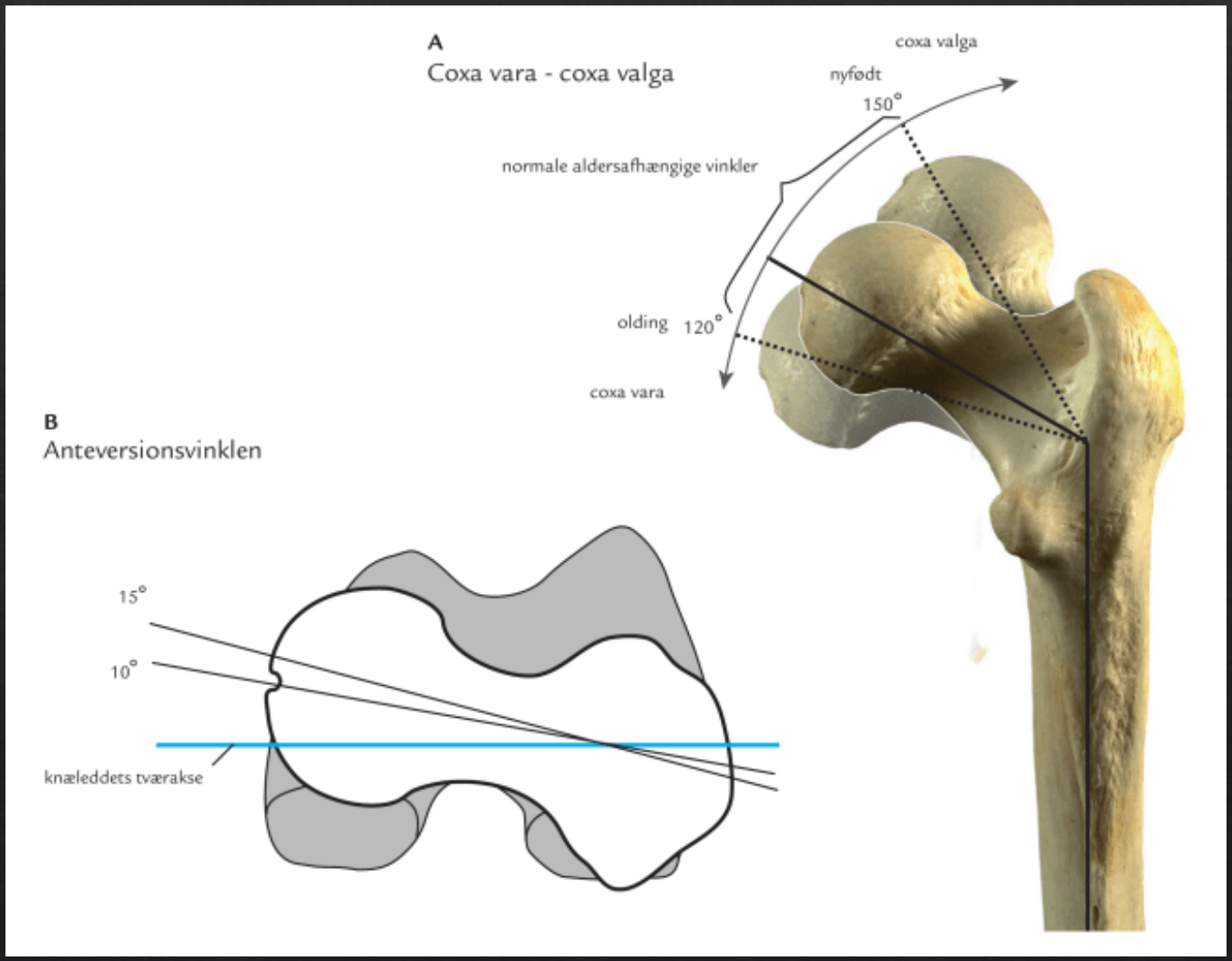
A
Coxa vara - coxa valga
coxa valga
nyfødt
150°
normale aldersafhængige vinkler
olding
120°
coxa vara
B
Anteversionsvinklen
15°
10°
knæleddets tværakse

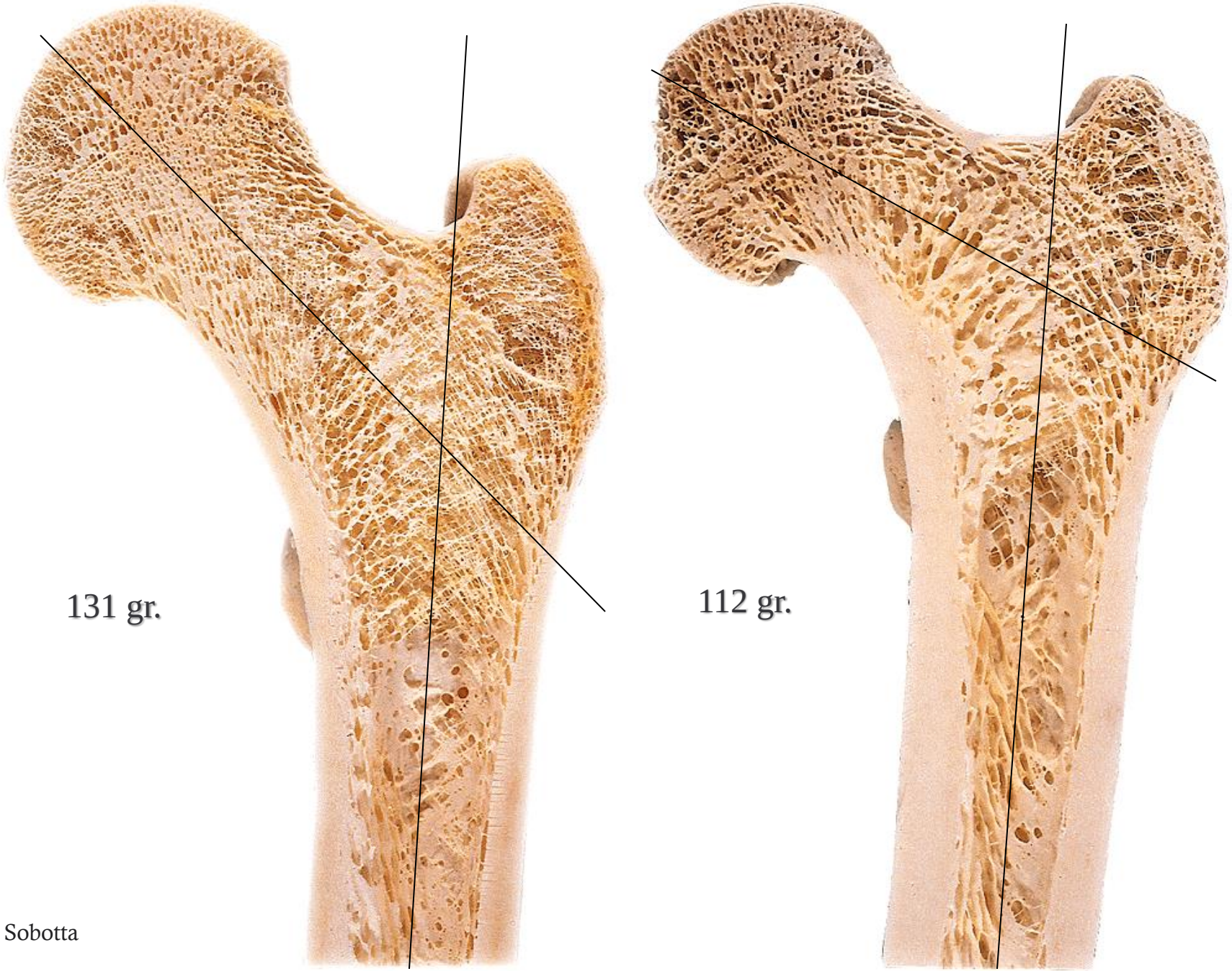

Sobotta

Femoral anteversion: Intoeing

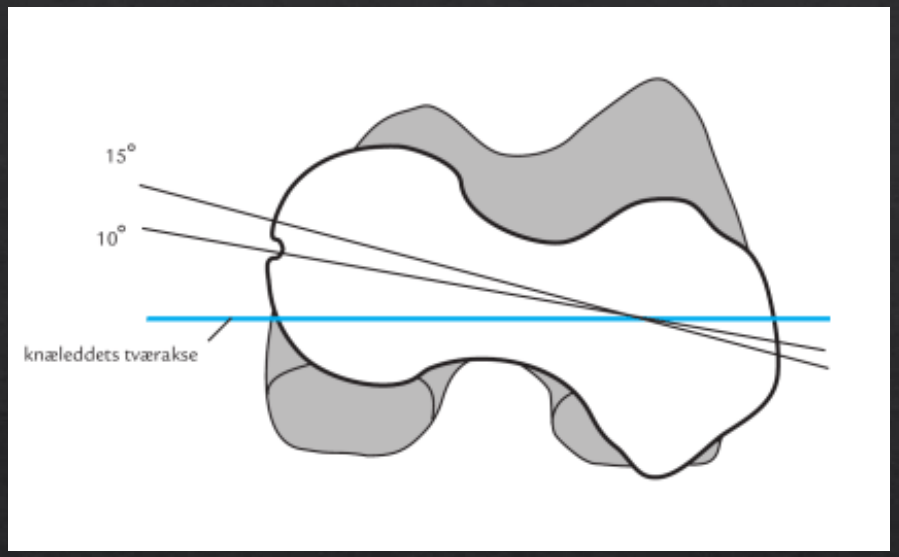

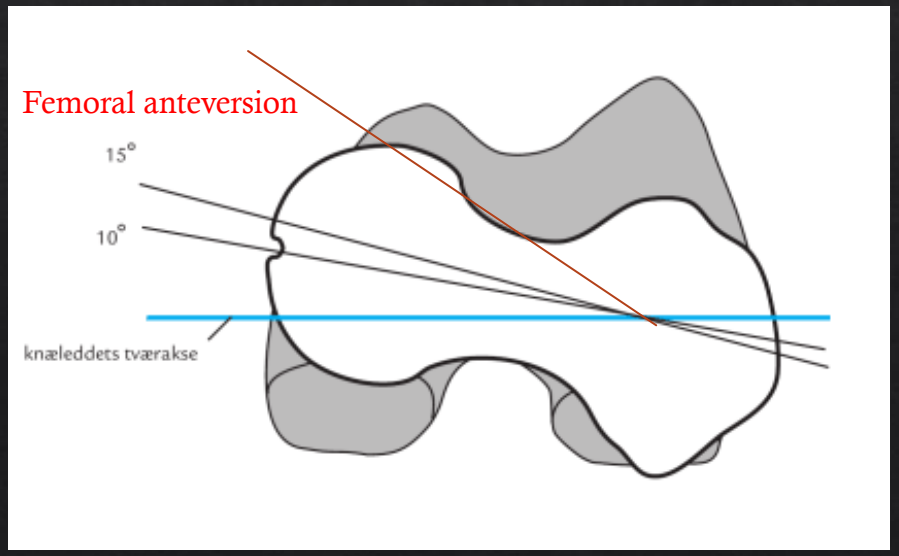

Hofteleds MR-artrografi

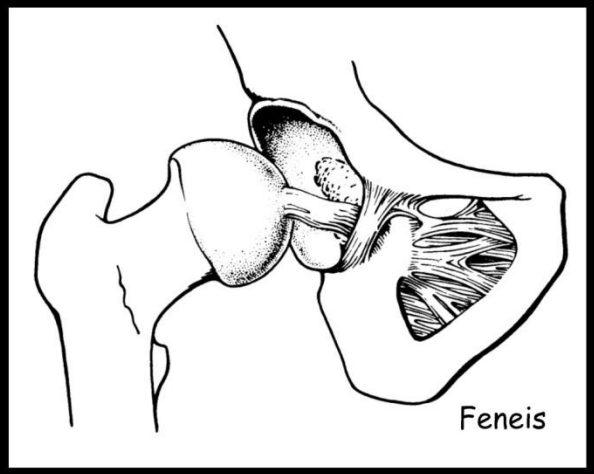
Feneis

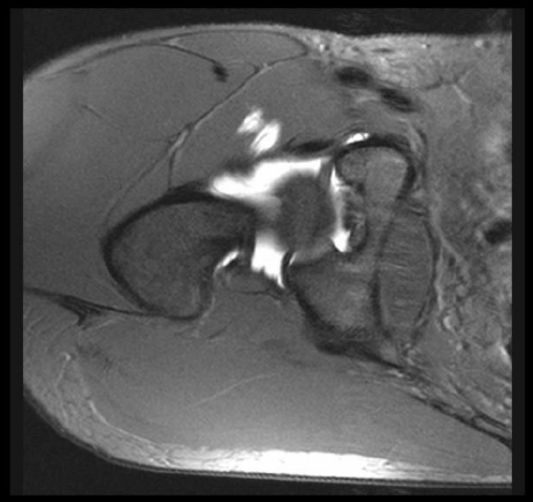

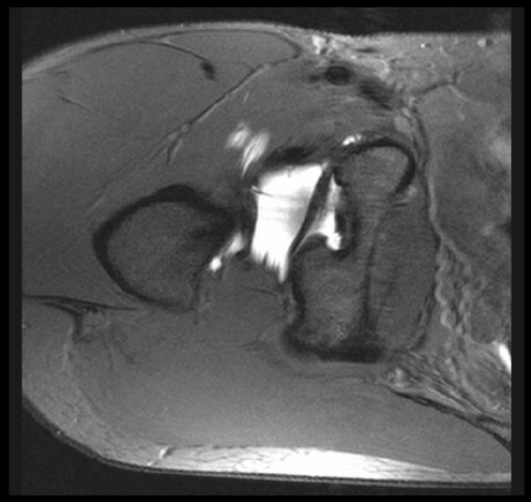

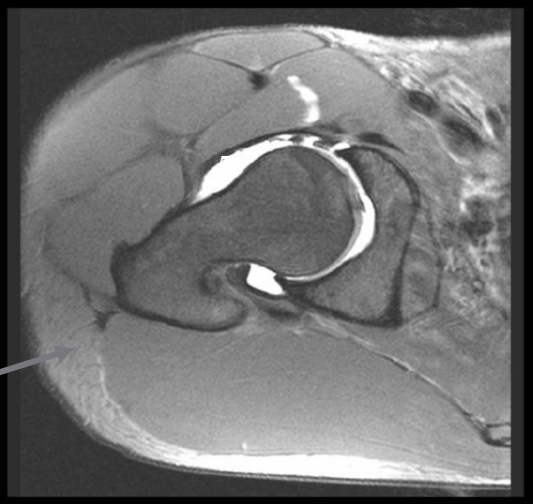

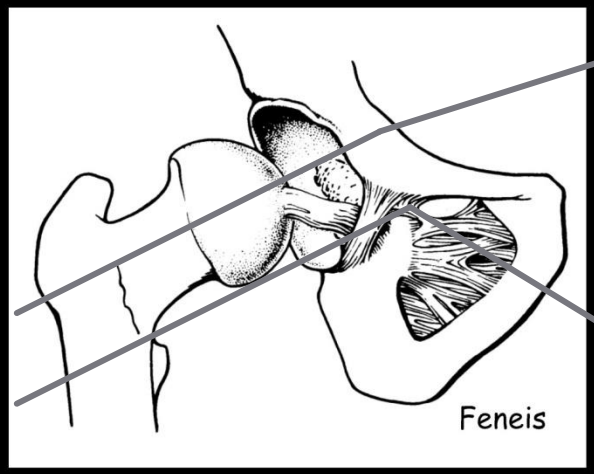

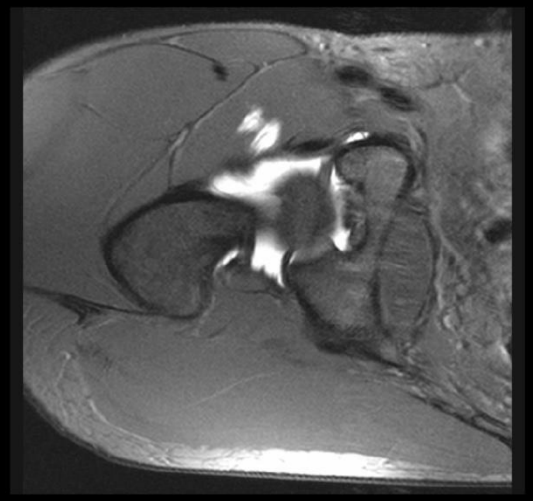

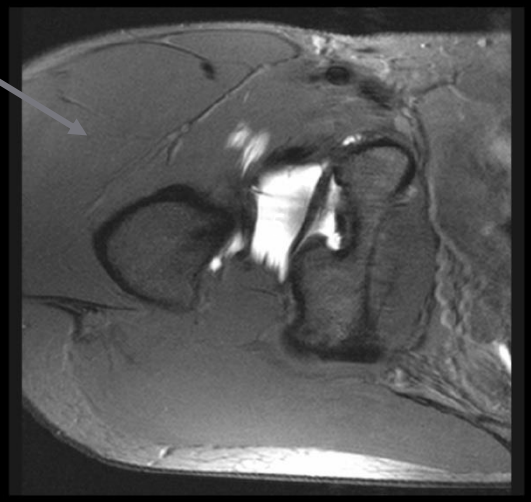

Skrå transvers T1 vægtede fedtsaturerede sekvenser med gadolinium holdig kontrast i hofteleddet

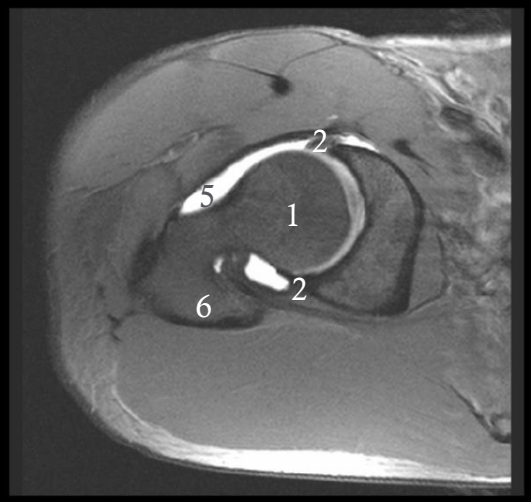
2
5
1
6
2

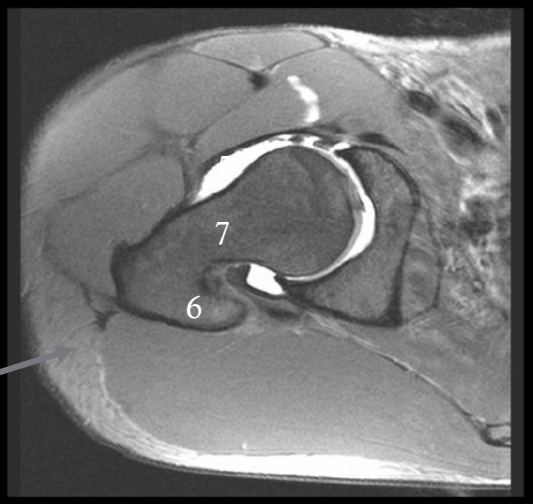
7
6

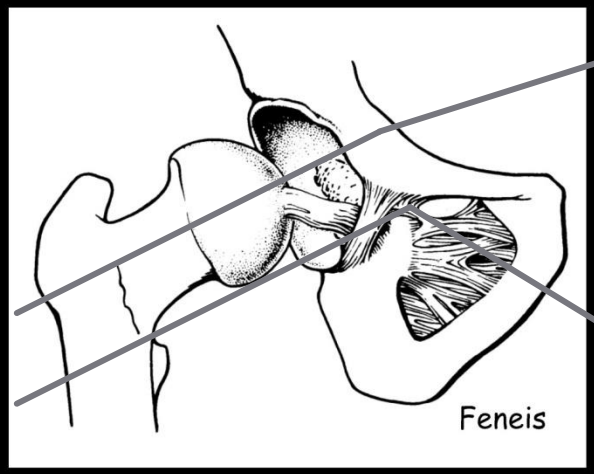
Feneis

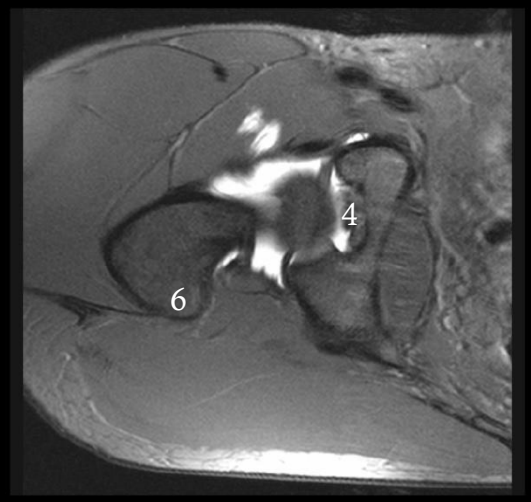
4
6

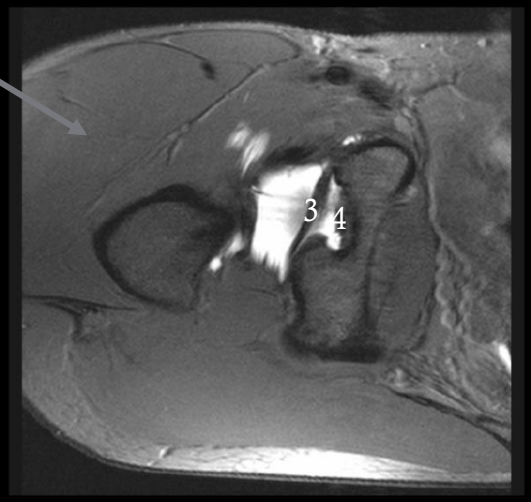
3
4

1. Caput femoris
2. Labrum acetabulare
3. Lig. transversum actabuli
4. Fossa acetabuli
5. MR kontrast i hofteled
6. Trochanter major
7. Collum femoris

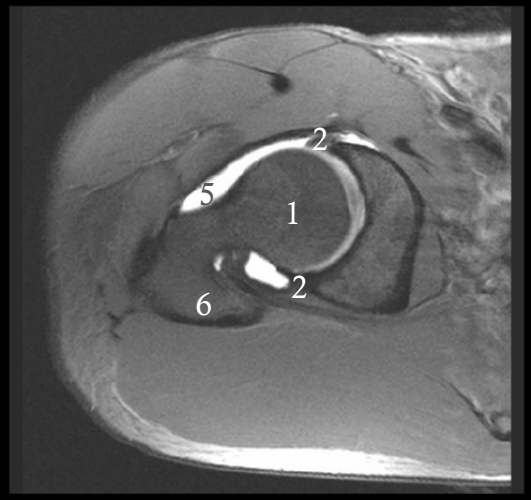

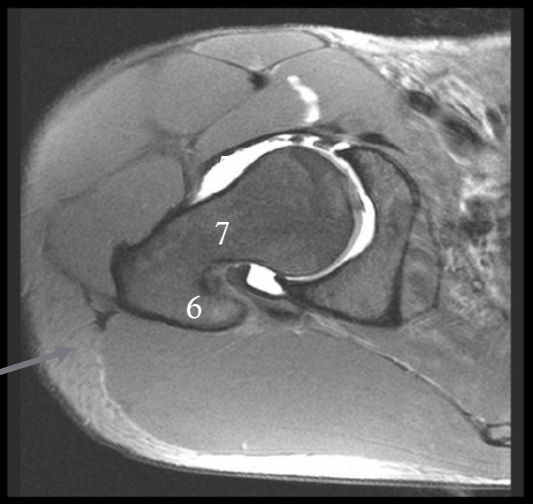

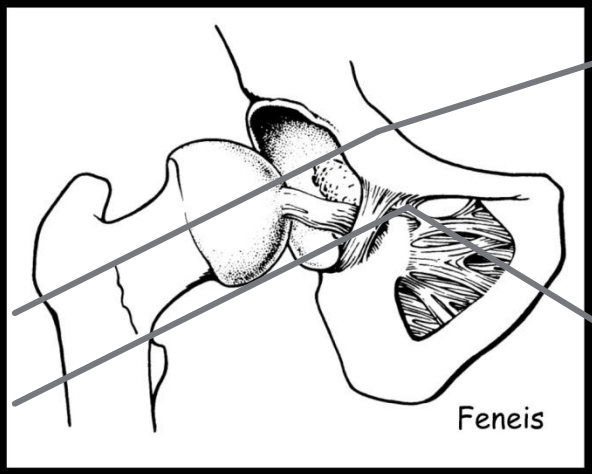

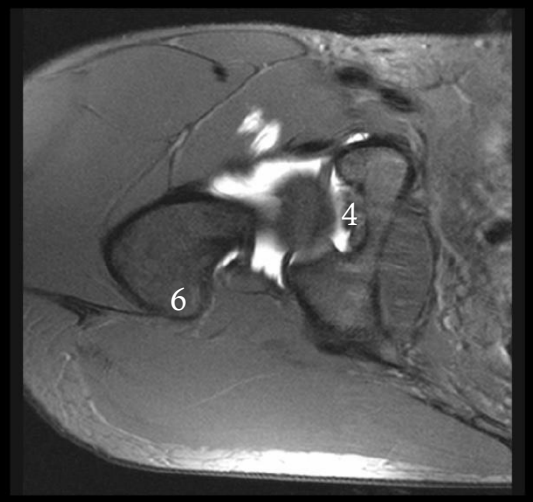

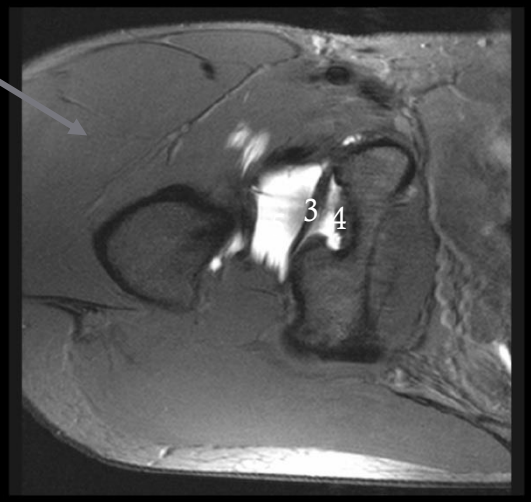

Femurs bløddele

MR: T1

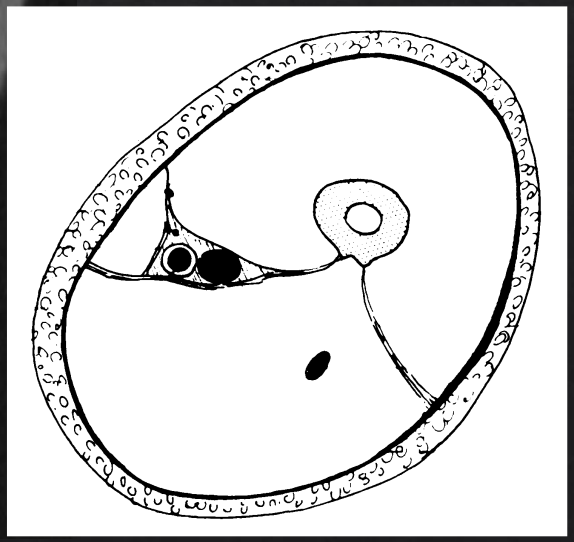

Fascia lata
•Tractus iliotibialis

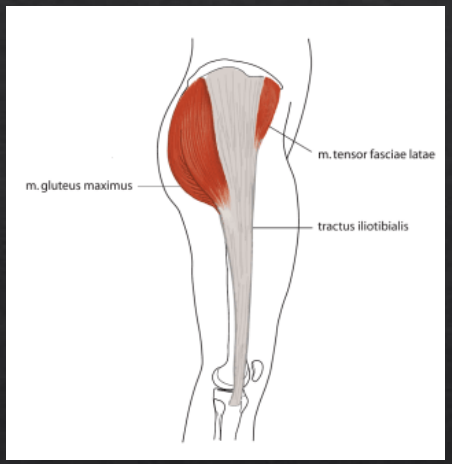

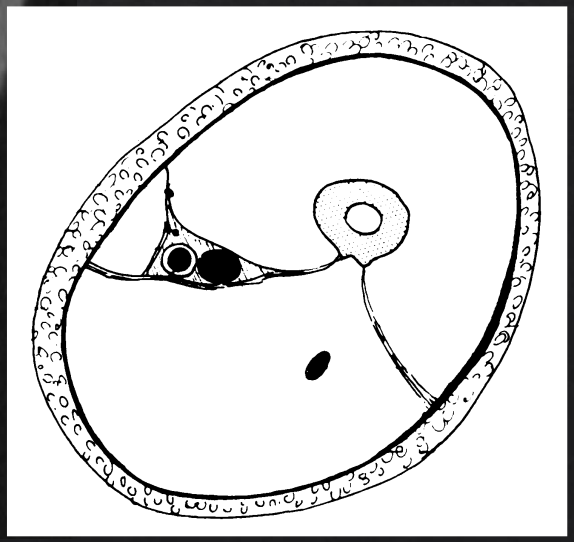

Ekstensorloge
Fleksorloge
Adduktorloge

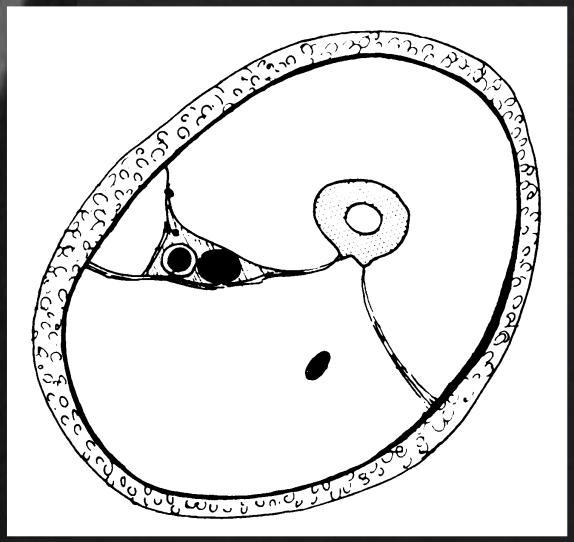

Ekstensorloge
Fleksorloge
Adduktorloge

•Ekstensorer

•Adduktorer

•Fleksorer

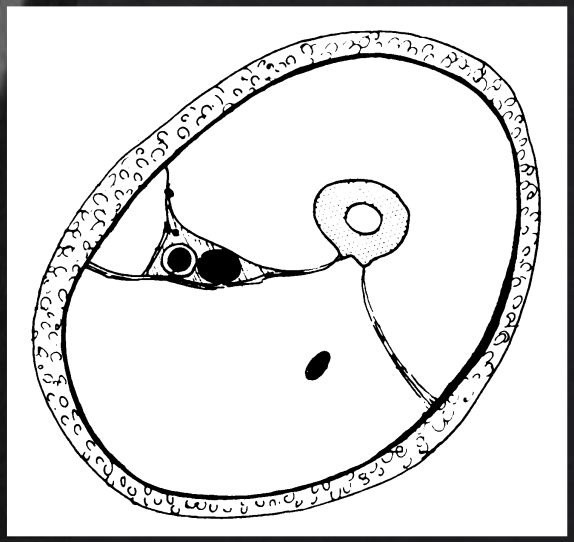

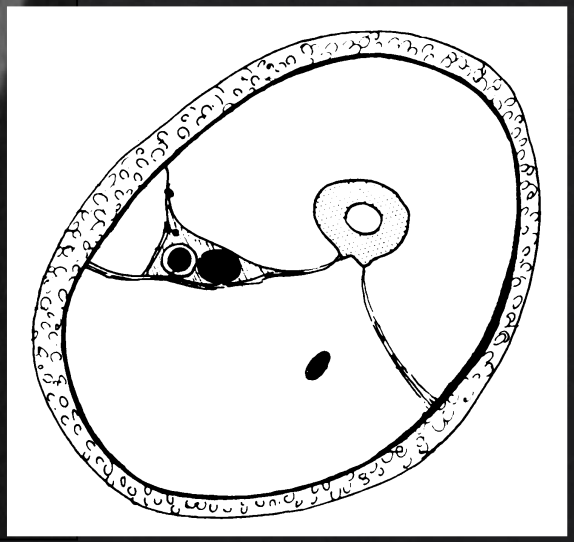

Pulsations
artefakter fra
a. femoralis

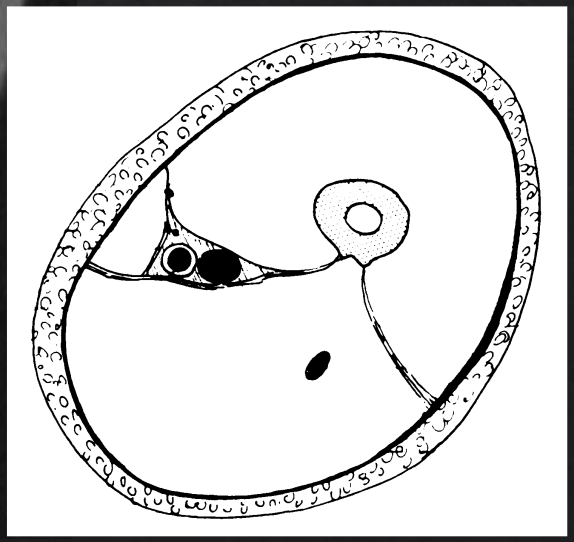

Kar og nerver

1. N. ischiadicus
2. A. femoralis
3. V. saphena magna

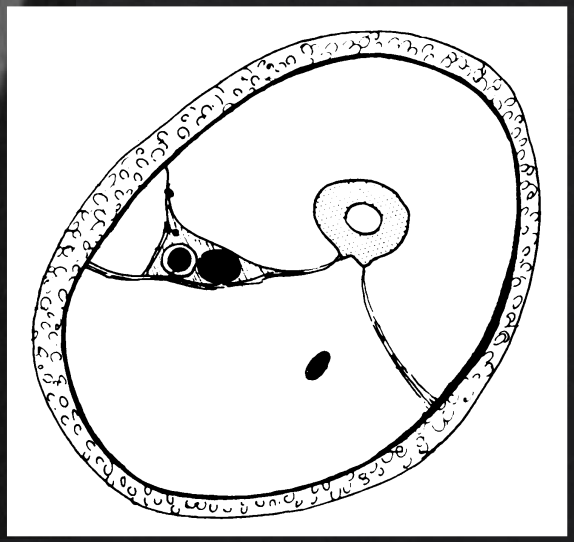

21-årig mand, der har følt smæld i låret under løb

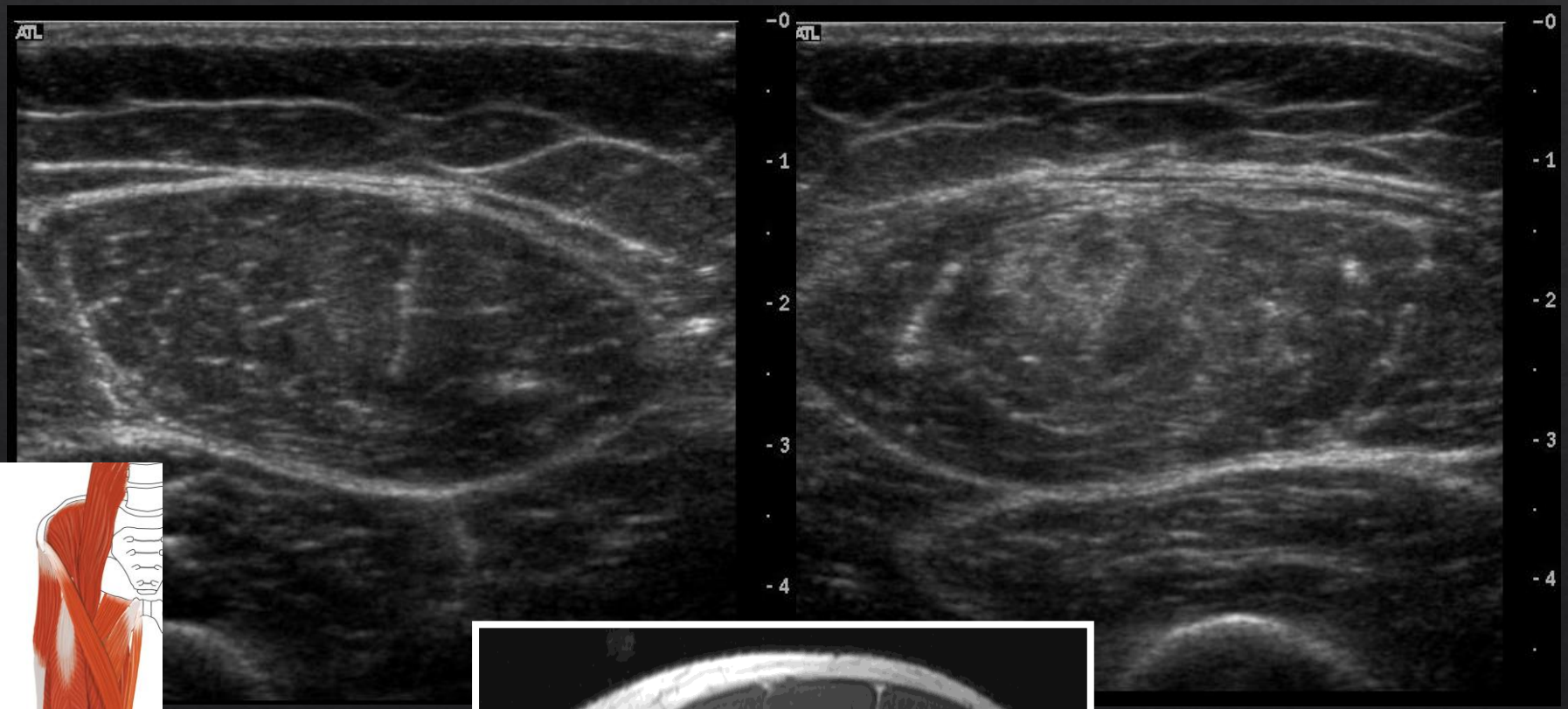

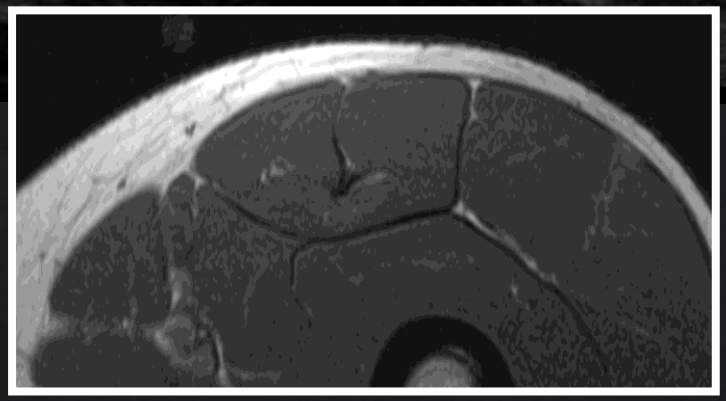

21-årig mand, der har følt smæld i låret under løb

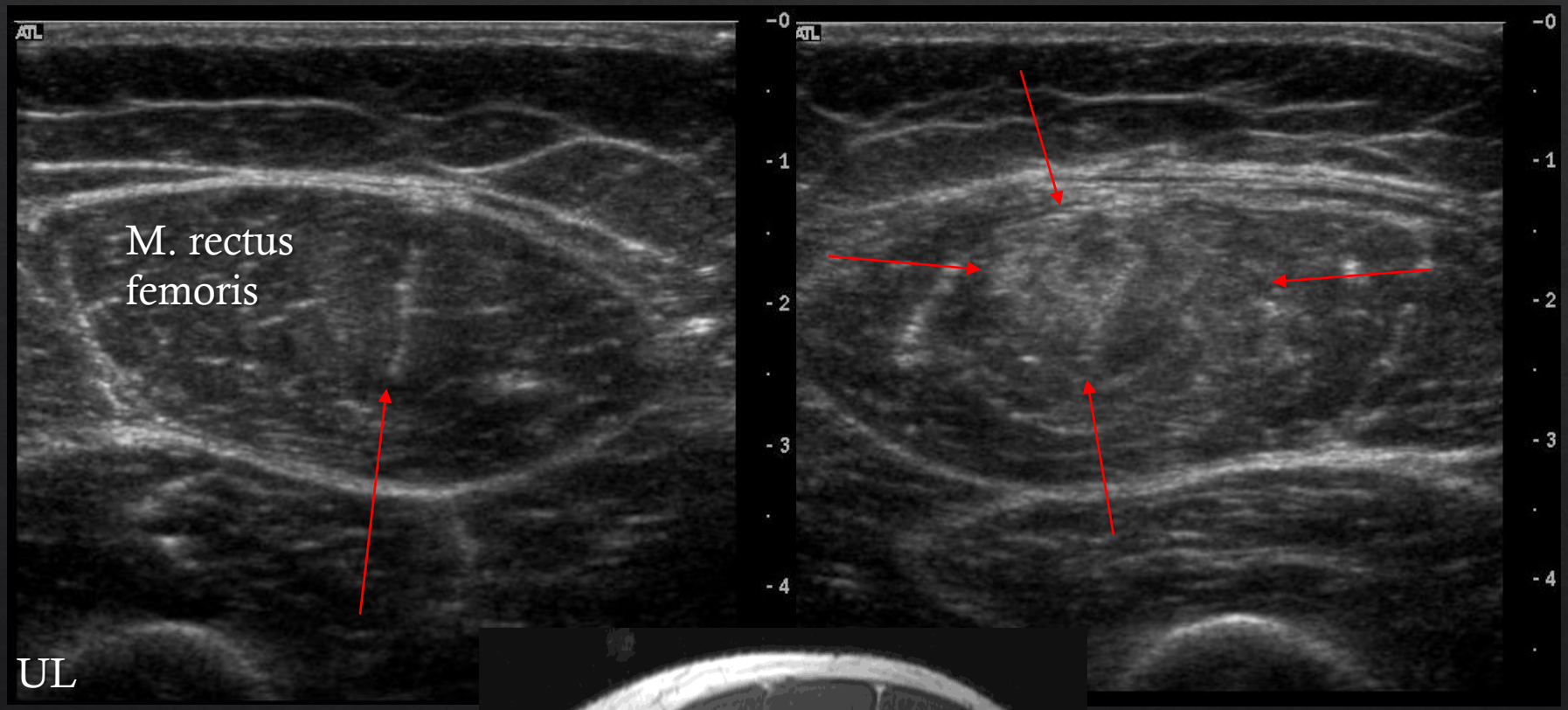

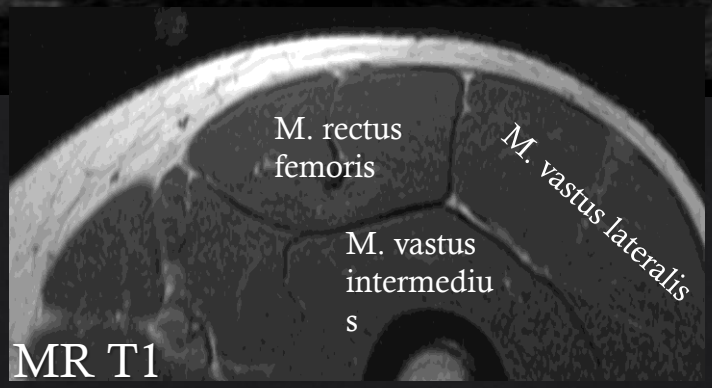

Normal UL og MR

UL med mindre muskelskade

Underekstremitetens kar

Arteriosklerose hos 55 årig kvinde.

Arteriosklerose hos 55 årig kvinde.

Arteriosklerose hos 55 årig kvinde.

1. A. femoralis
2. A. poplitae
3. A. tibialis posterior
4. A. tibialis anterior

Angiografi og Seldinger teknik

Angiografi ad modum Seldinger

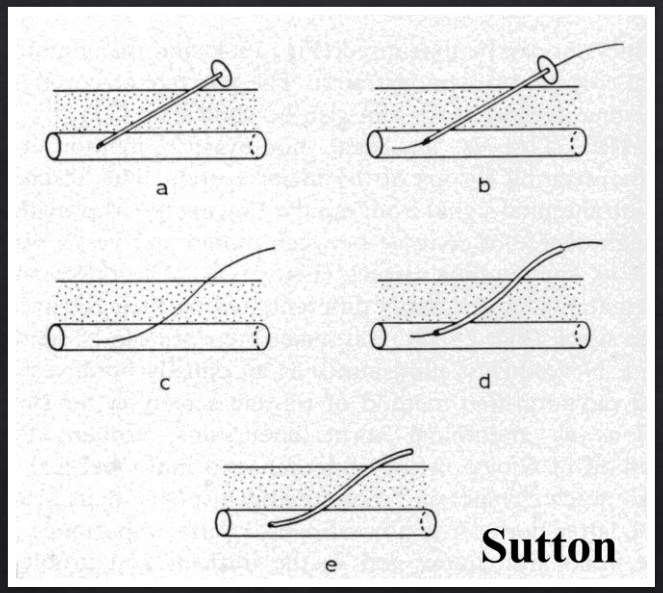

a. En kanyle føres ind i arterien
b. Gennem kanylen indføres en leder bestående af bøjeligt metal
c. Kanylen fjernes
d. Over lederen skubbes nu et plastik kateter
e. Når kateteret ligger med spidsen det korrekte sted sprøjtes kontraststof ind i det.

DSA: Digital subtraktions angiografi

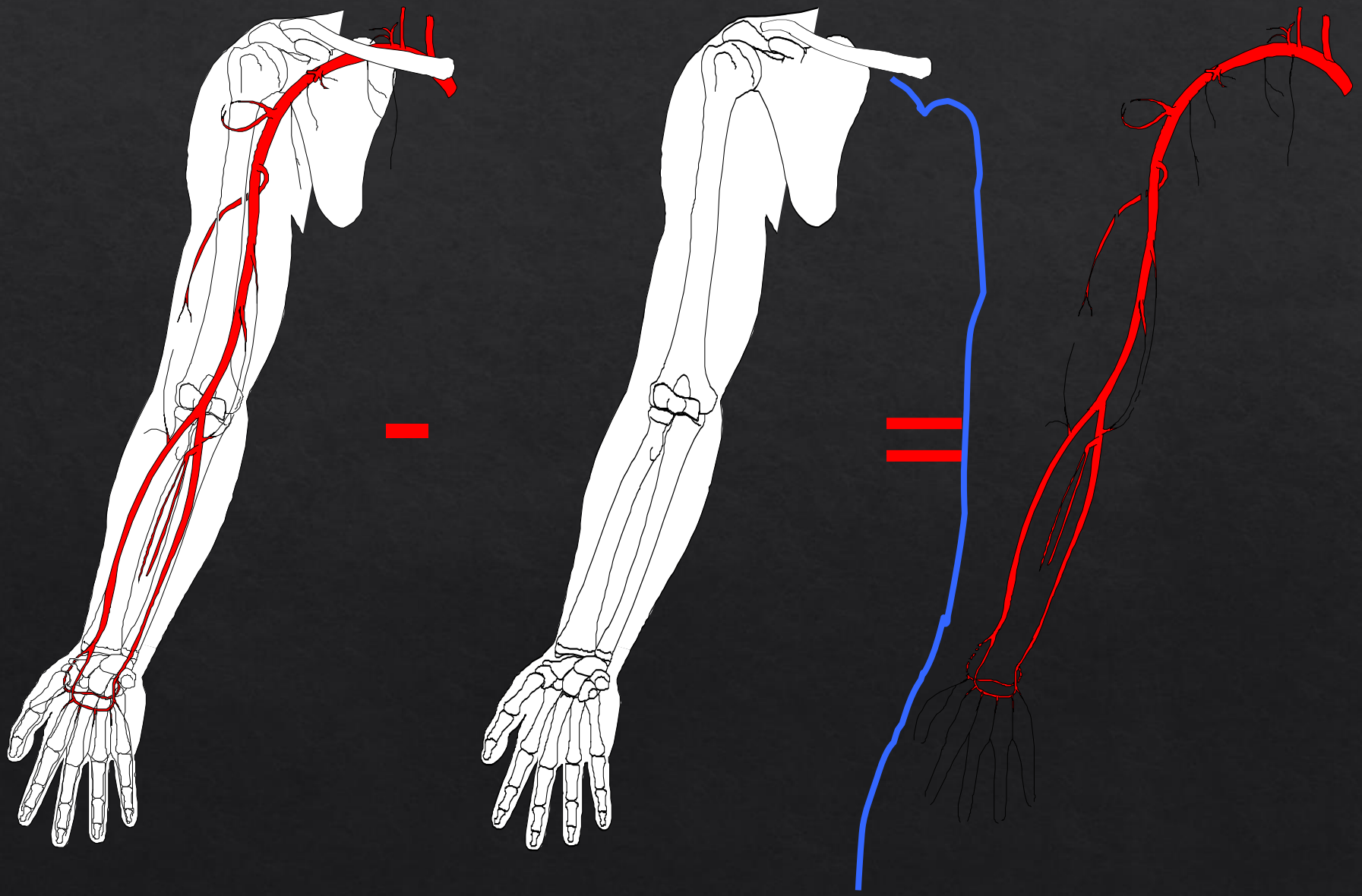

Først tages et oversigtsbillede af regionen med kateteret placeret

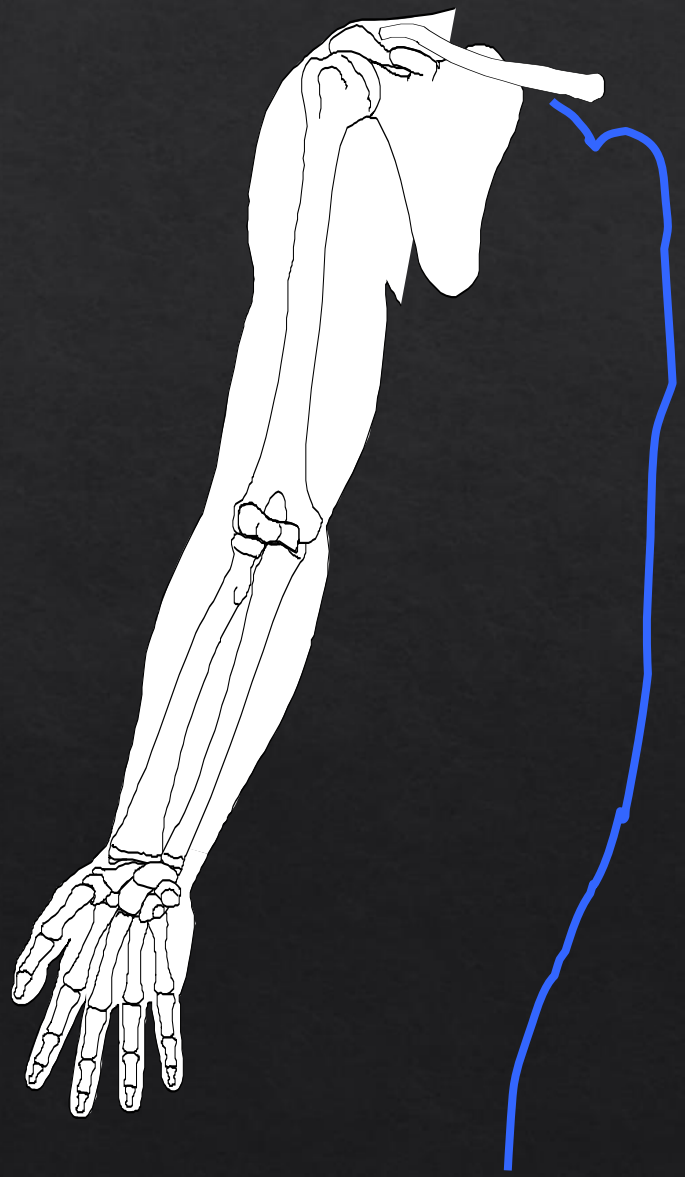

Derefter sprøjtes kontrasten ind i karret og der tages et nyt billede

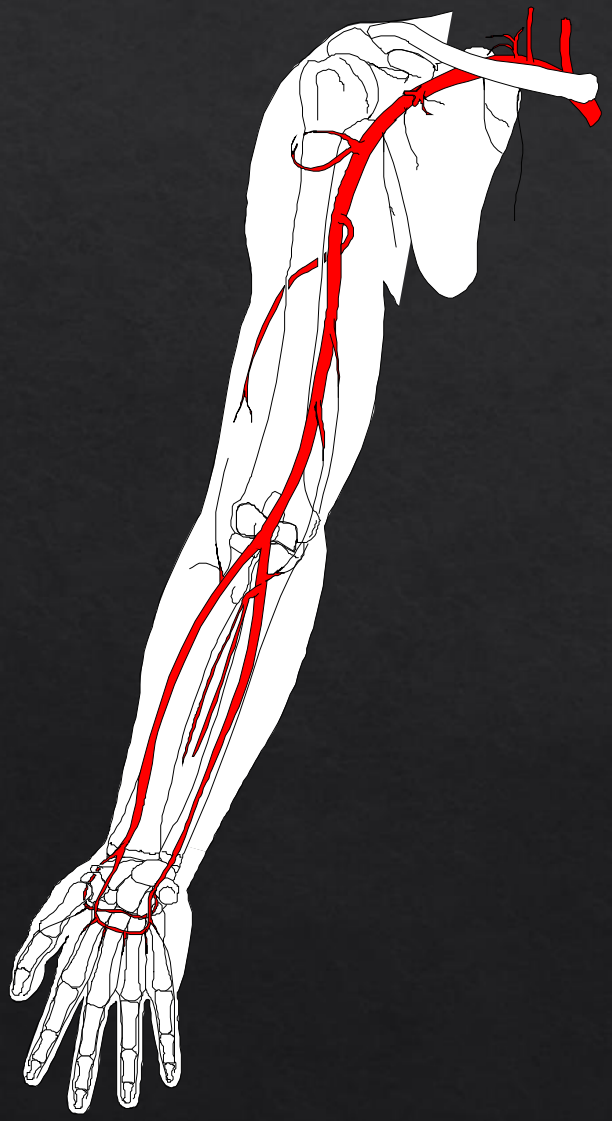

Der er tale om digitale billeder og det første billede trækkes nu fra det andet billede, således at der fås et billede af karrene

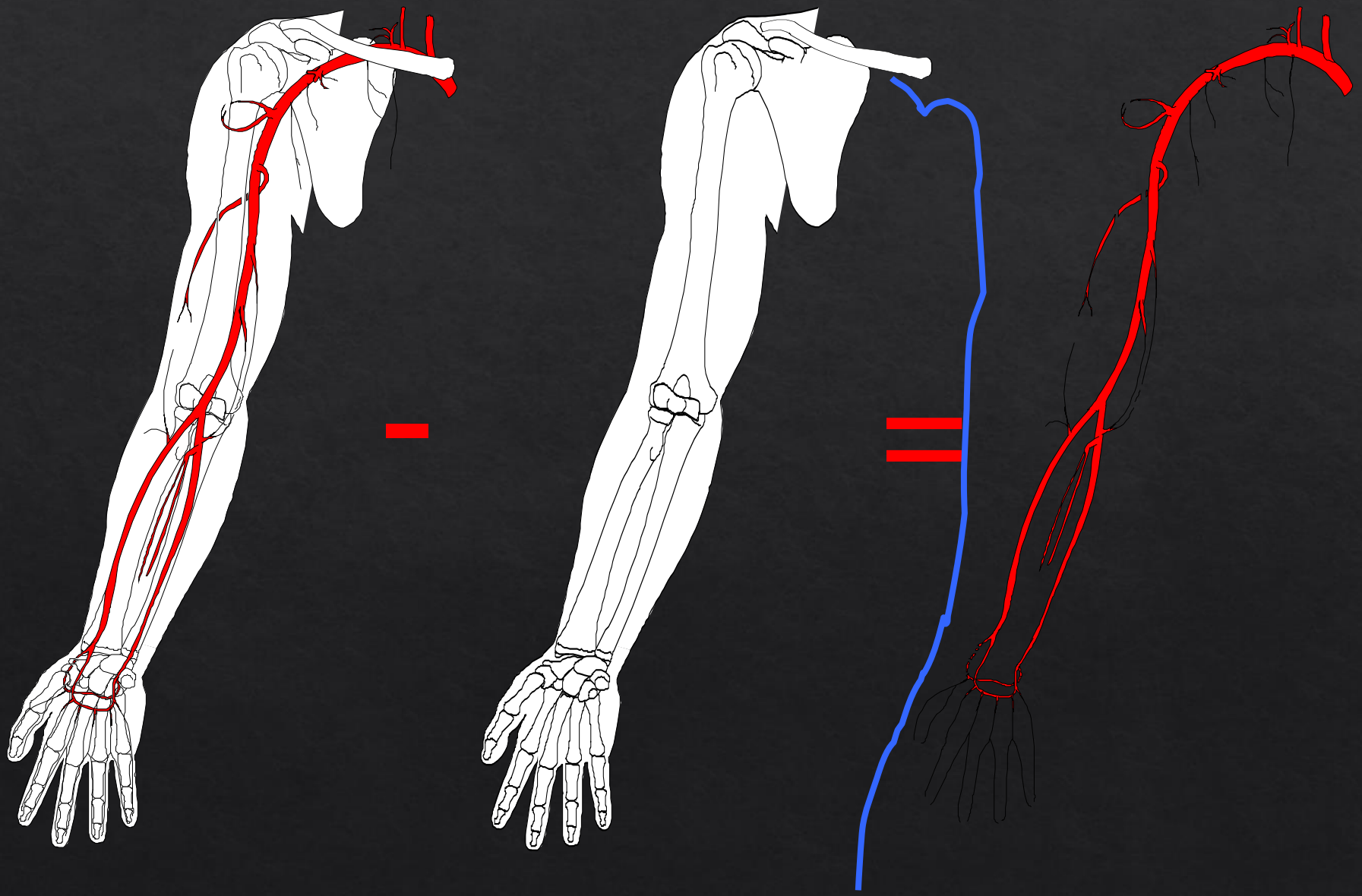

Venstre hofteregion: DSA

Venstre hofteregion: DSA

1. A. iliaca externa
2. A. femoralis
3. A. circumflexa femoris lateralis
4. A. circumflexa femoris medialis
5. A. profunda femoris
6. Aa. perforantes

Venstre hofteregion: DSA

Knæled og knæregionen

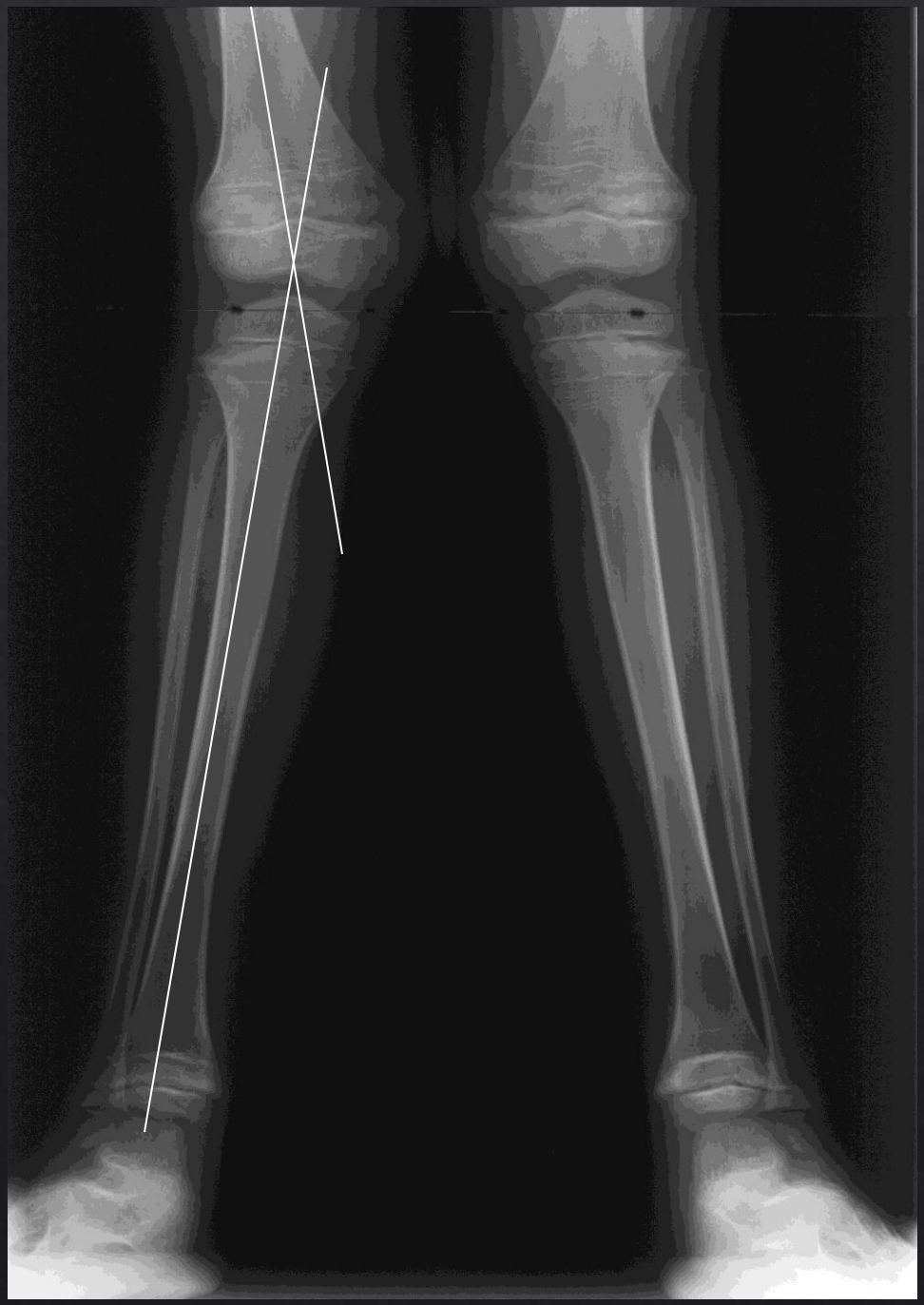

5 årig dreng med genu valgum (Metafysære forandringer skyldes rakit).

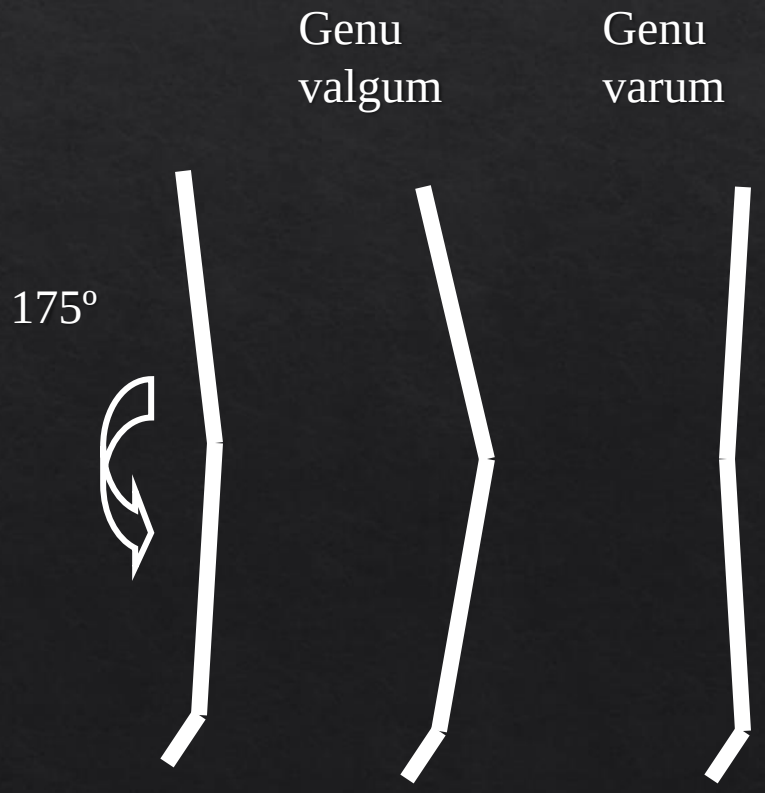

AP røntgenoptagelse af højre knæ

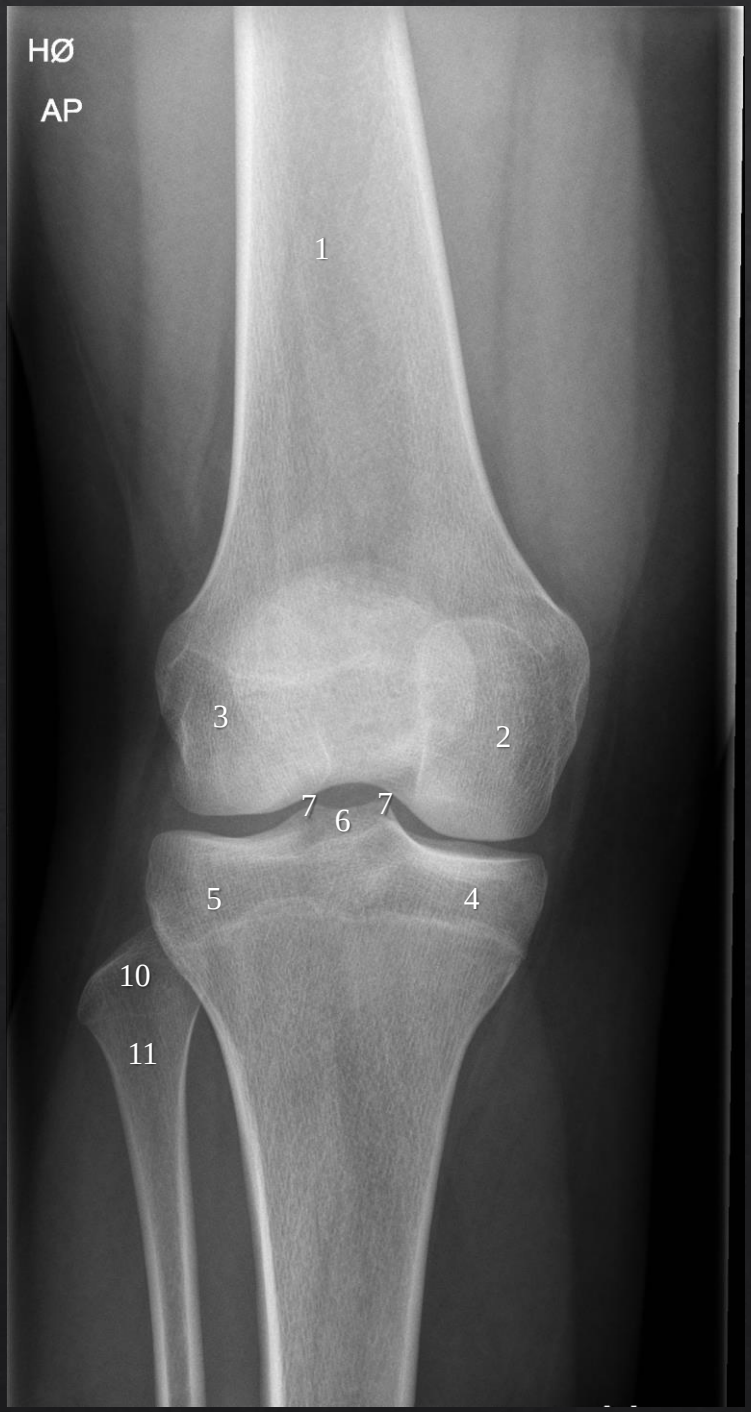
HØ
AP
1
2
3
4
5
6
7
7
10
11

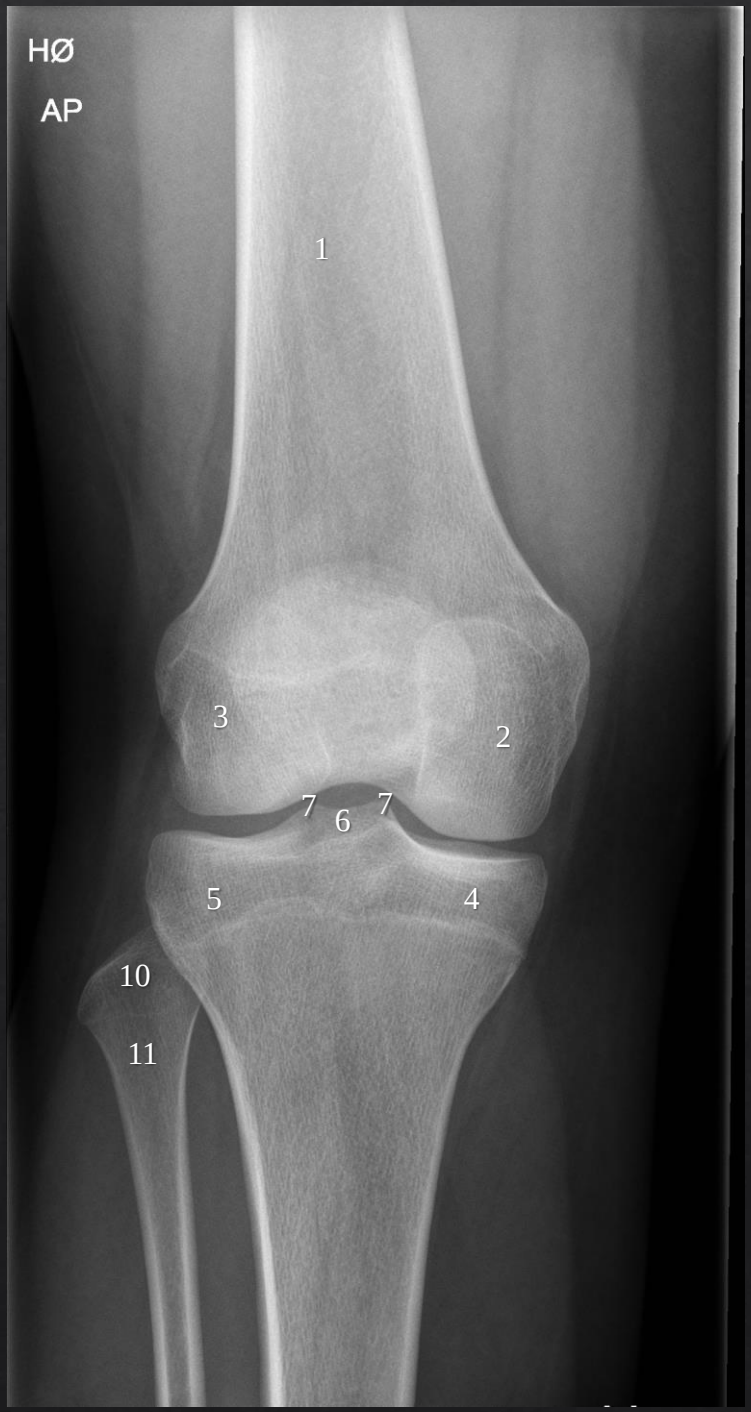

1) Corpus femoris
2) Condylus medialis femoris
3) Condylus lateralis femoris
4) Condylus medialis tibiae
5) Condylus lateralis tibiae
6) Eminentia intercondylaris
7) Tuberculum intercondylare mediale et laterale
8) Area intercondylaris ant. et post. (Ses ej)
9) Tuberositas tibiae (Ses ej)
10) Caput fibulae
11) Collum fibulae

AP røntgenoptagelse af højre knæ:

Patella

Side røntgenoptagelse af højre knæ

HØ
Ligge
12
13
1
5
4
10
8
9
11
Dx

1) Condylus medialis et lateralis
2) Fossa intercondylaris – Ses ej
3) Epicondylus medialis et lateralis –Ses ej
4) Condylus medialis et lateralis tibiae
5) Eminentia intercondylaris
6) Tuberculum intercondylare mediale et laterale
7) Area intercondylaris ant. et post.
8) Tuberositas tibiae
9) Caput fibilae
10) Apex capitis fibulae
11) Collum fibulae
12) Basis patellae
13) Apex patellae

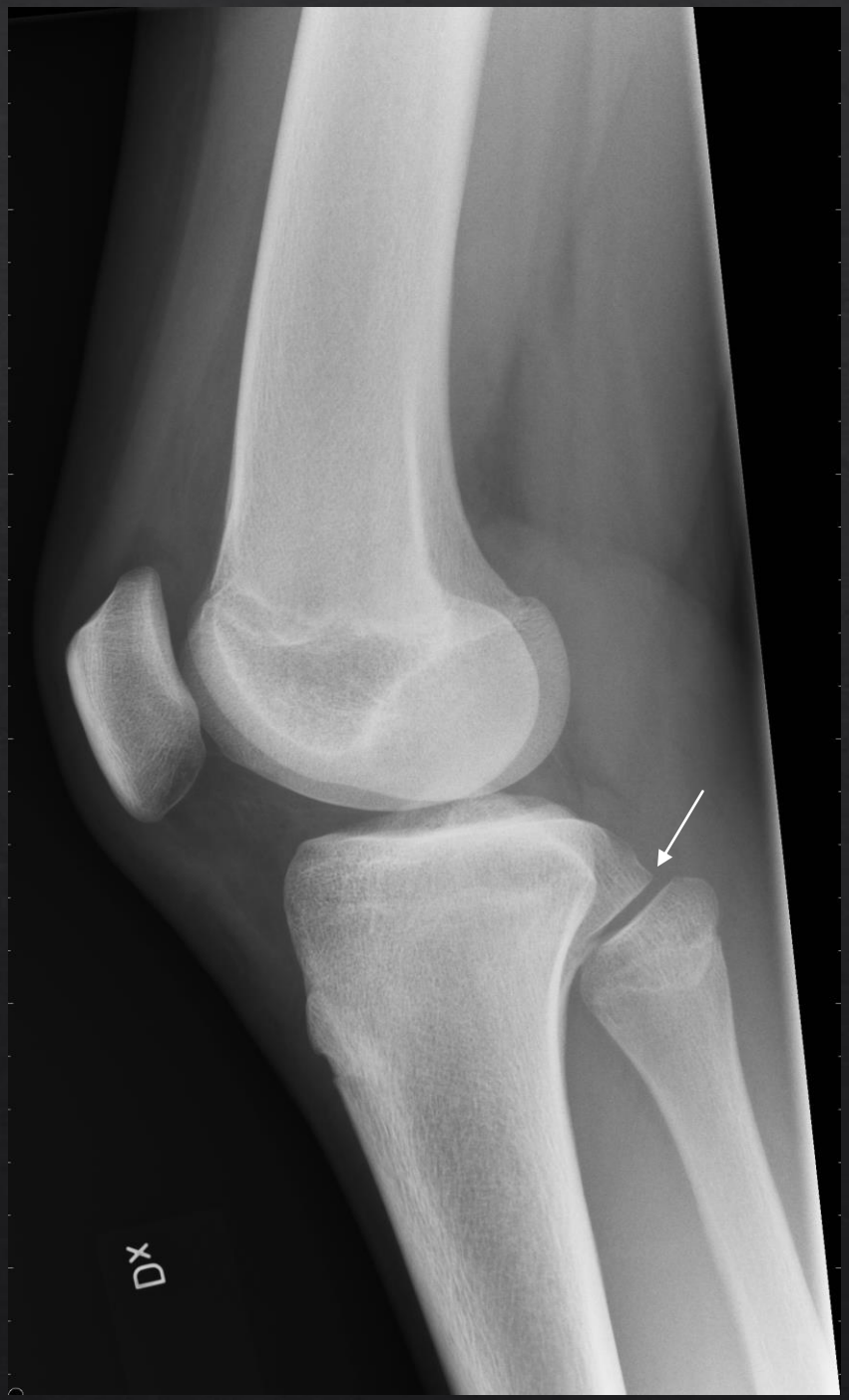

En lidt skrå (udadroteret) optagelse giver flot indblik til articulatio tibiofibularis.

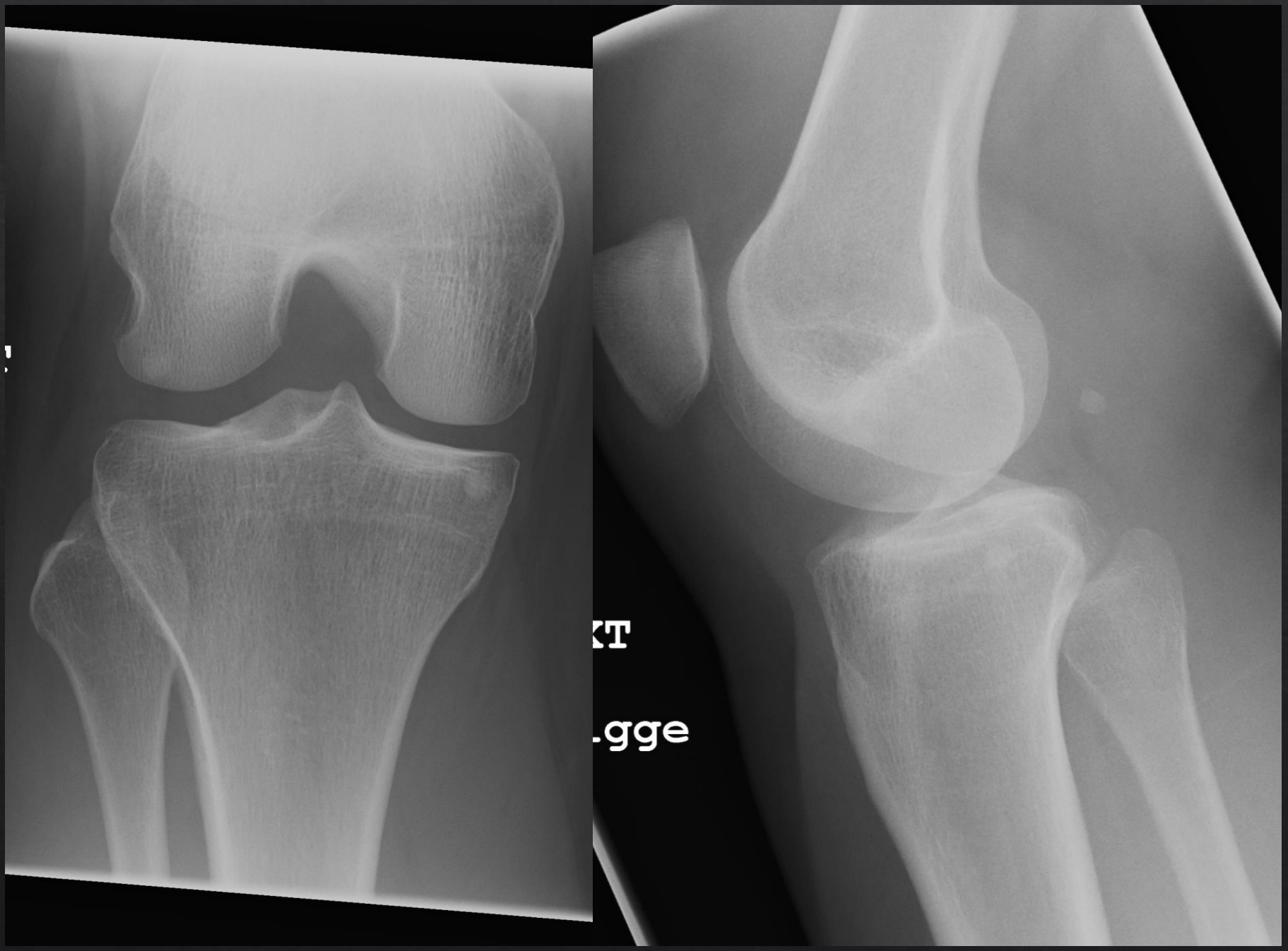

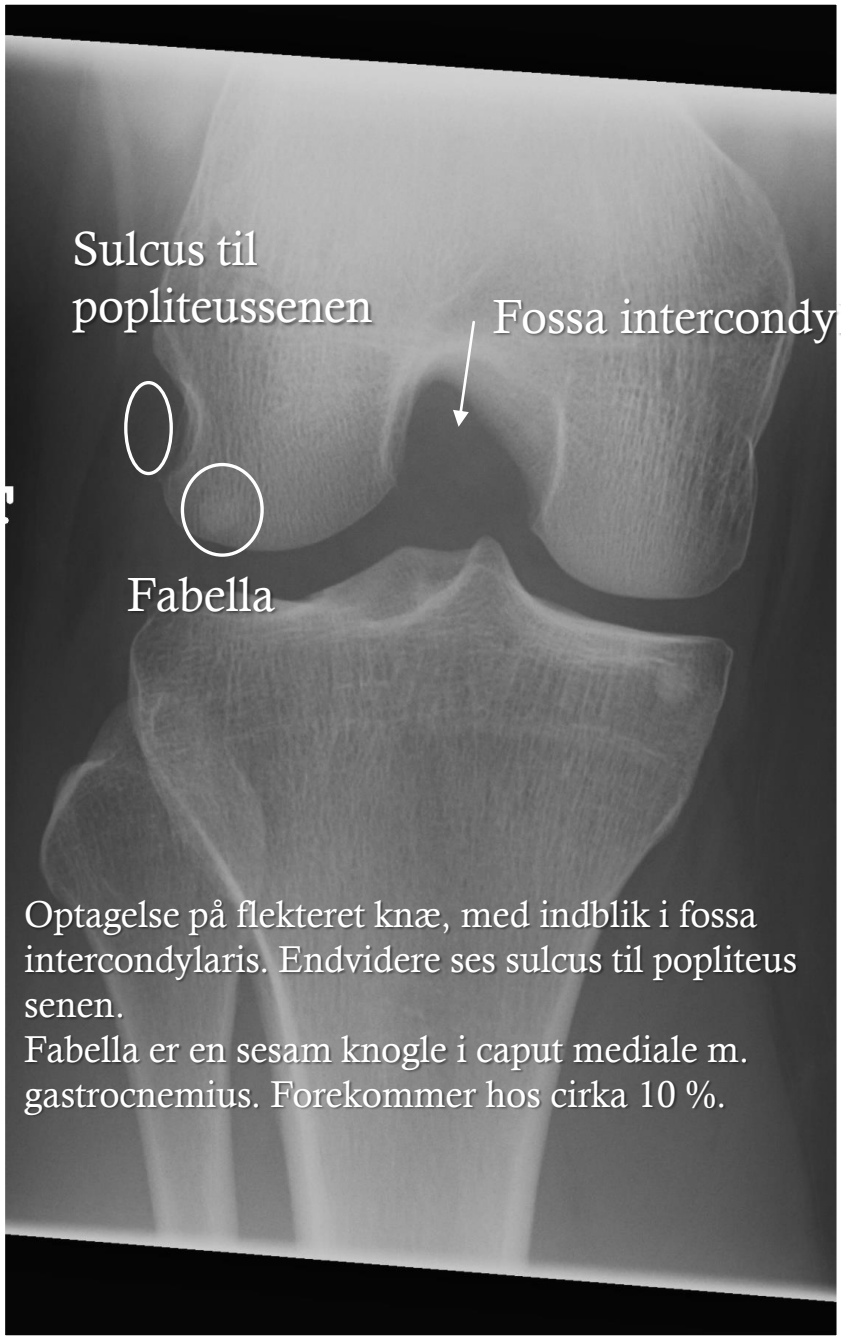

Optagelse på flekteret knæ, med indblik i fossa intercondylaris. Endvidere ses sulcus til popliteus senen.
Fabella er en sesam knogle i caput mediale m. gastrocnemius. Forekommer hos cirka 10 %.

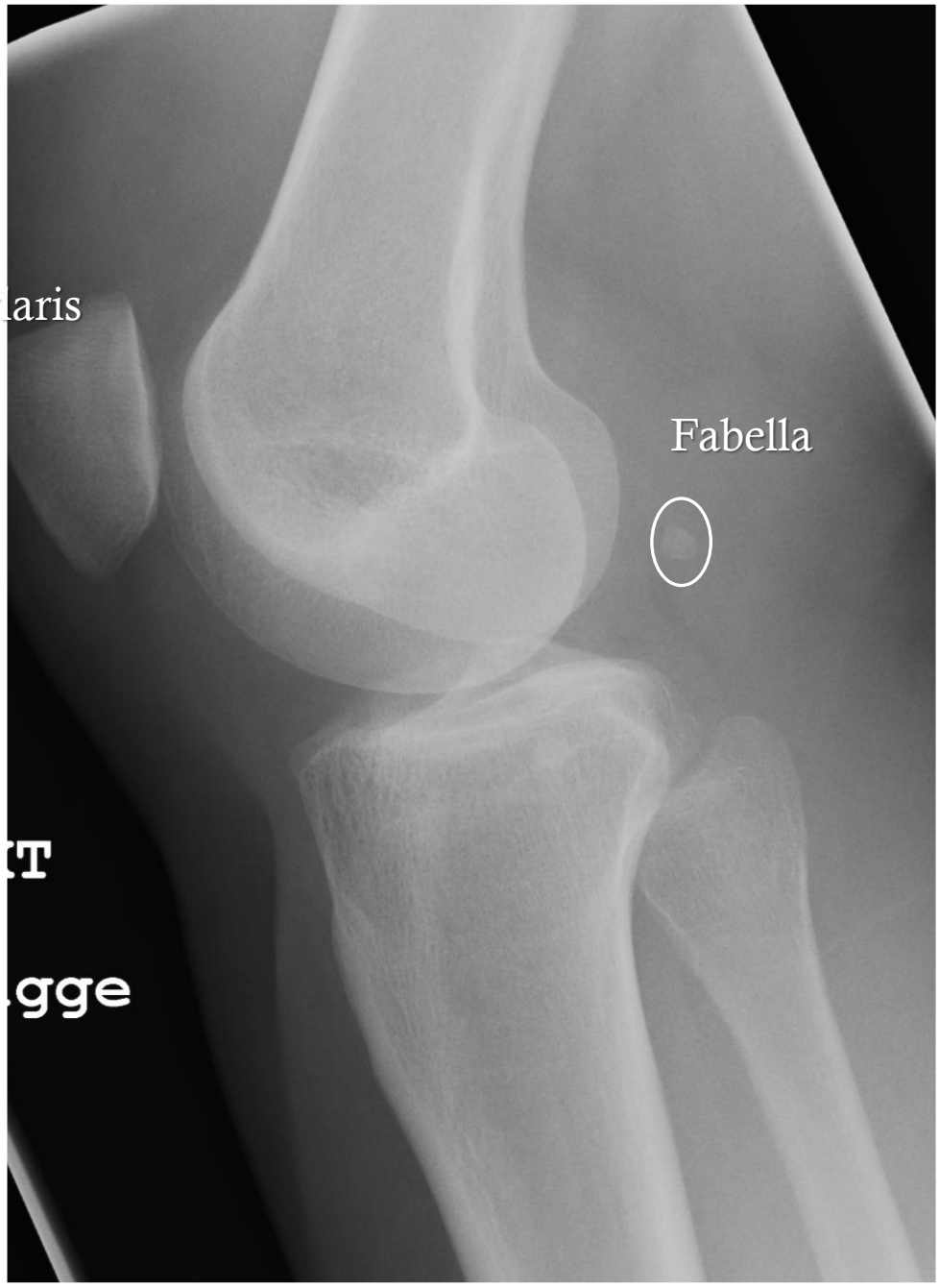

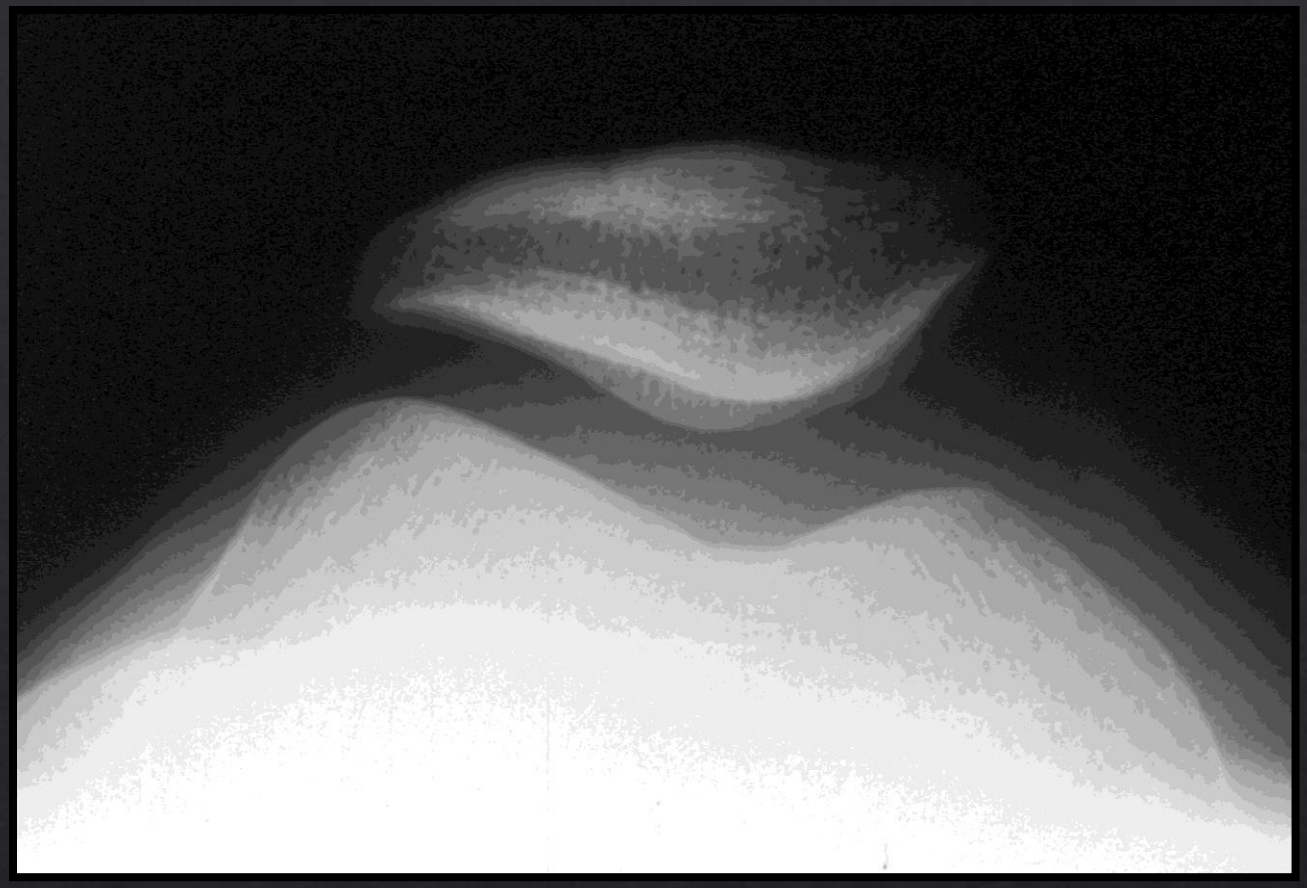

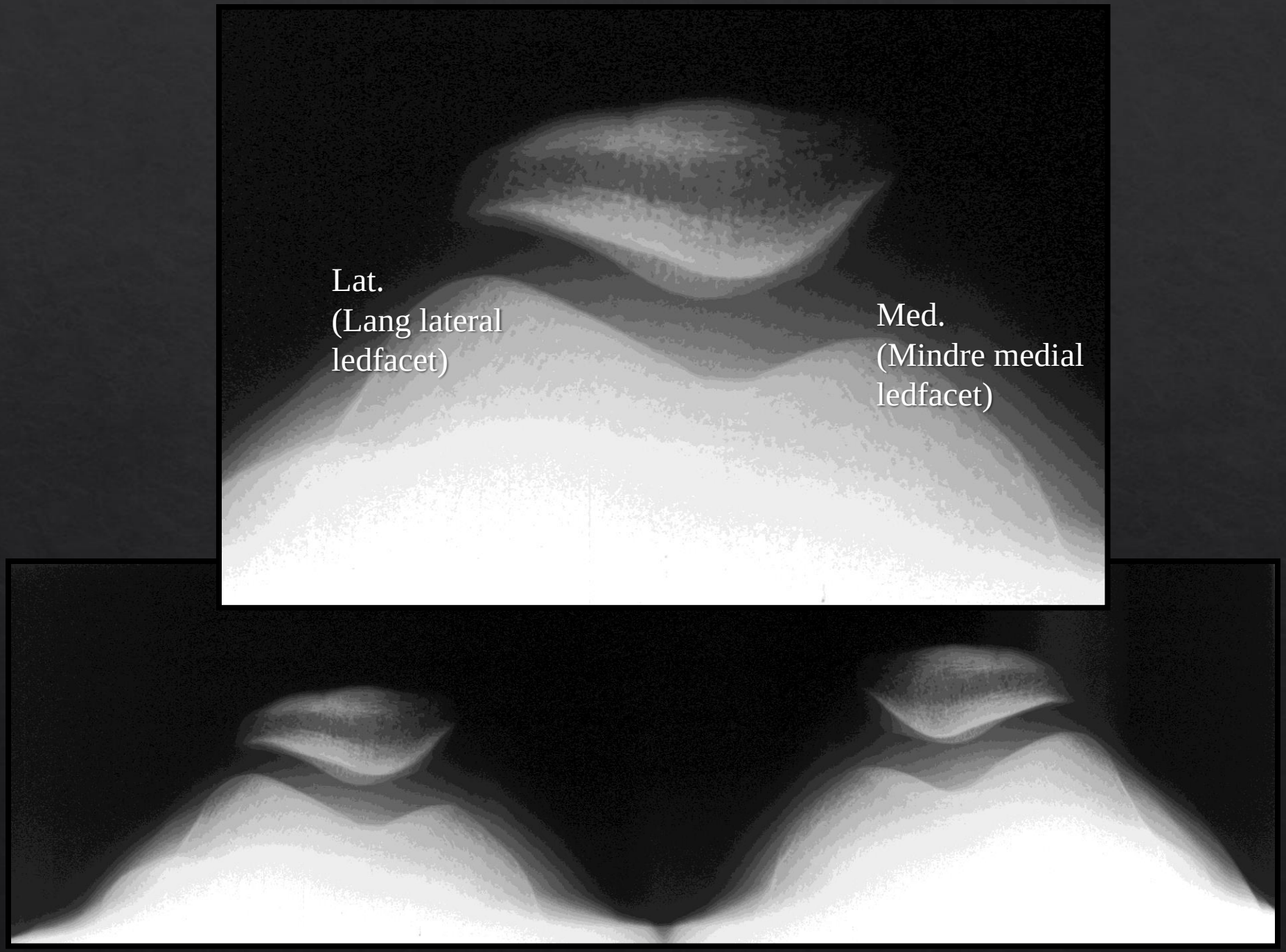
Lat.
(Lang lateral ledfacet)
Med.
(Mindre medial ledfacet)

Knæledsarthrose hos 77 årig mand.

MR knæled

MR: PDfs

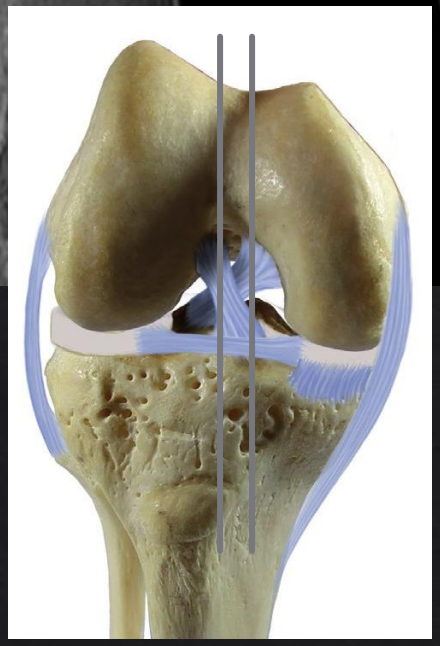

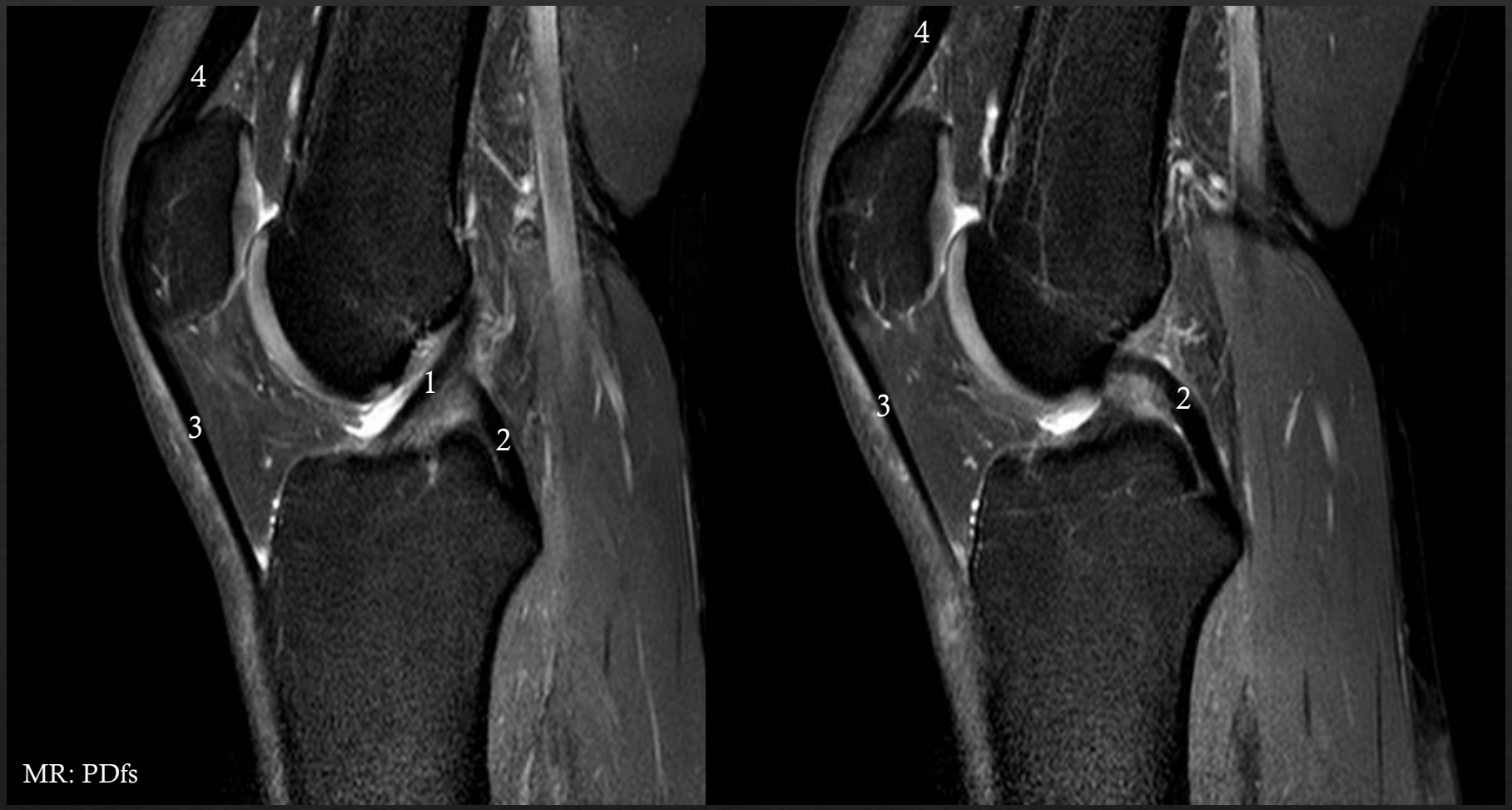
4
1
3
2
MR: PDfs
4
3
2

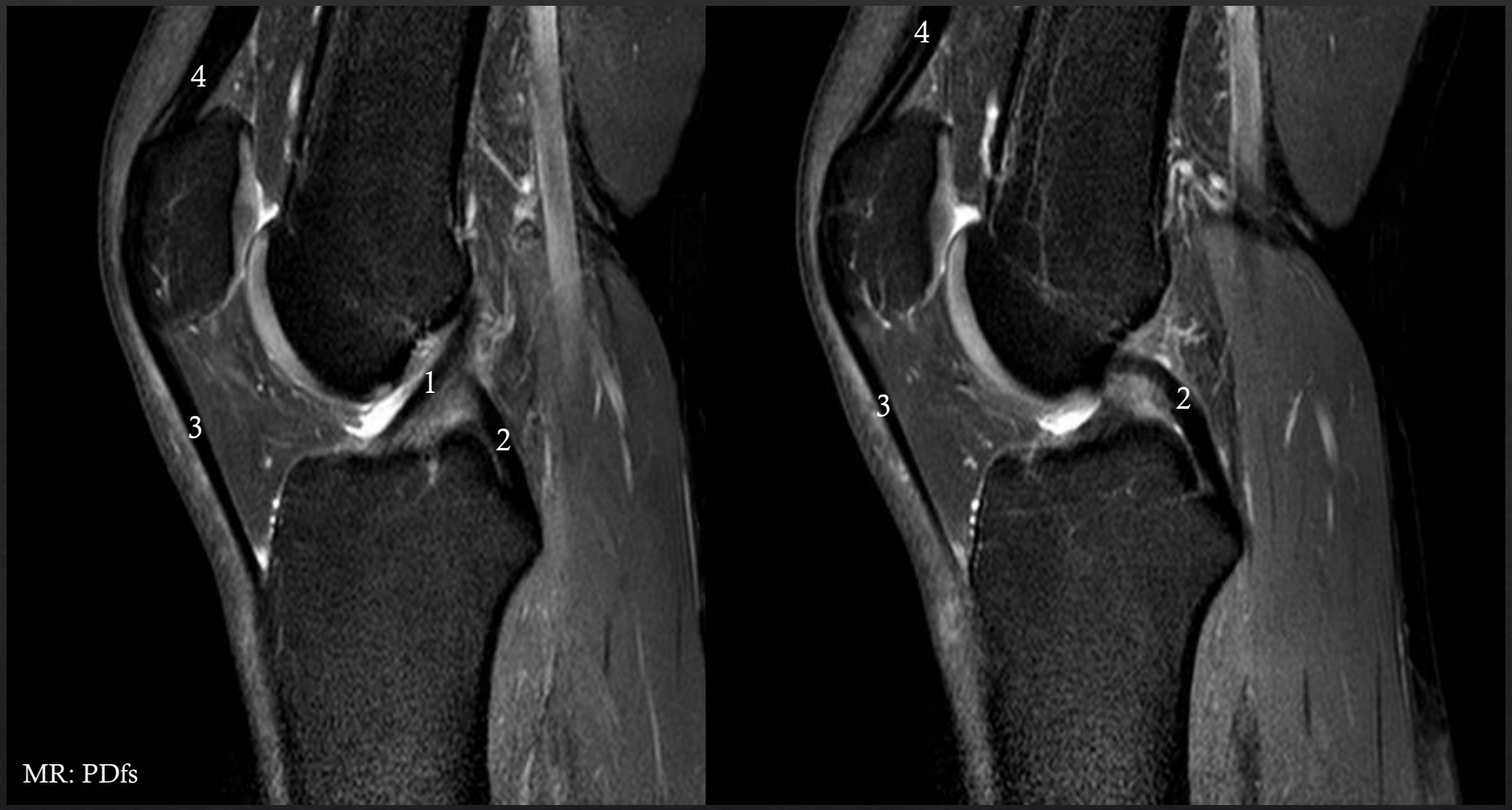

1. Lig. cruciatim anterius (ACL)
2. Lig. cruciatum posterius (PCL)
3. Lig. Patellae
4. Quadricepssene

MR højre knæ

3D model set bagfra

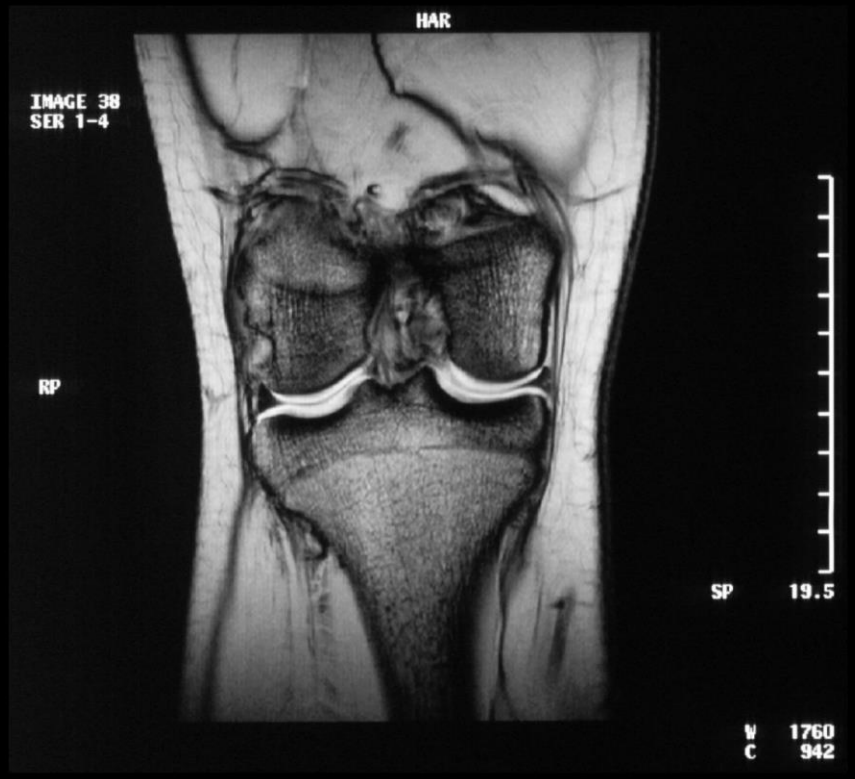
HAR
IMAGE 38
SER 1-4
RP
SP 19.5
W 1760
C 942

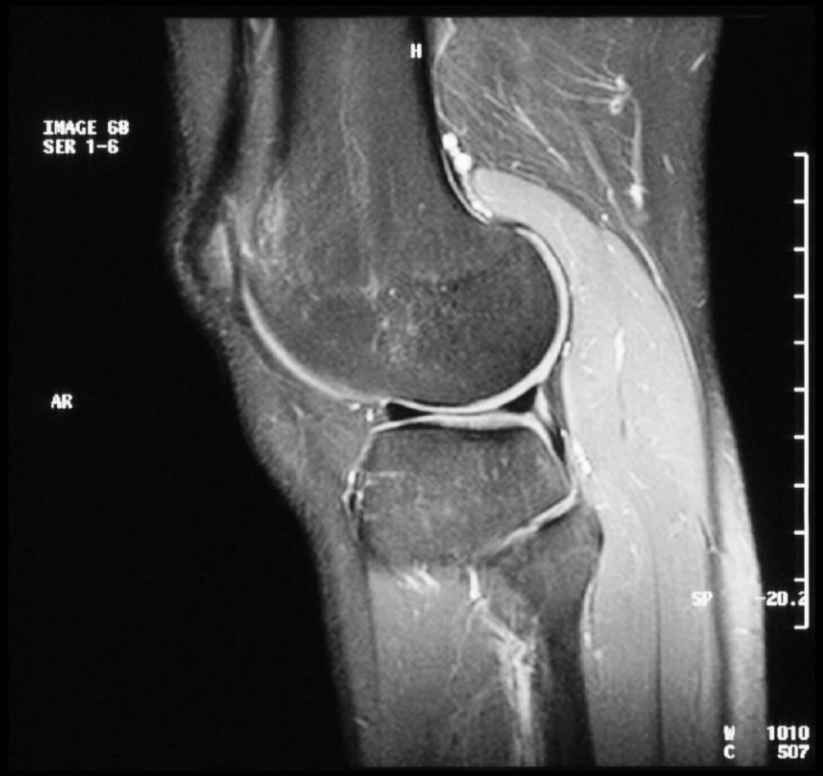
H
IMAGE 68
SER 1-6
AR
SP
W 1010
C 507

MR knæled:
Læsioner

Menisk læsion

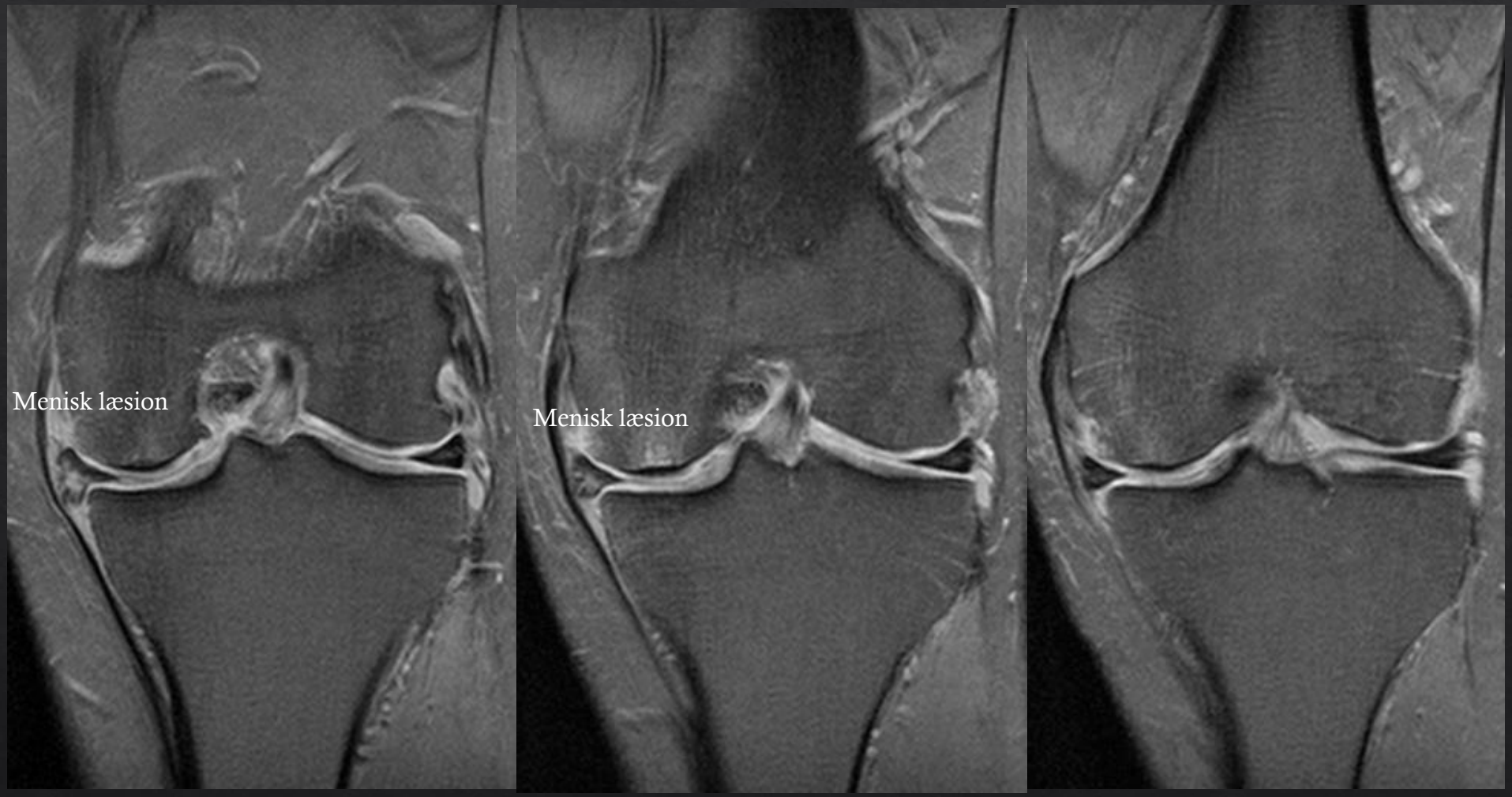
Menisk læsion
Menisk læsion

Epifyseskiver

Pige 3 år

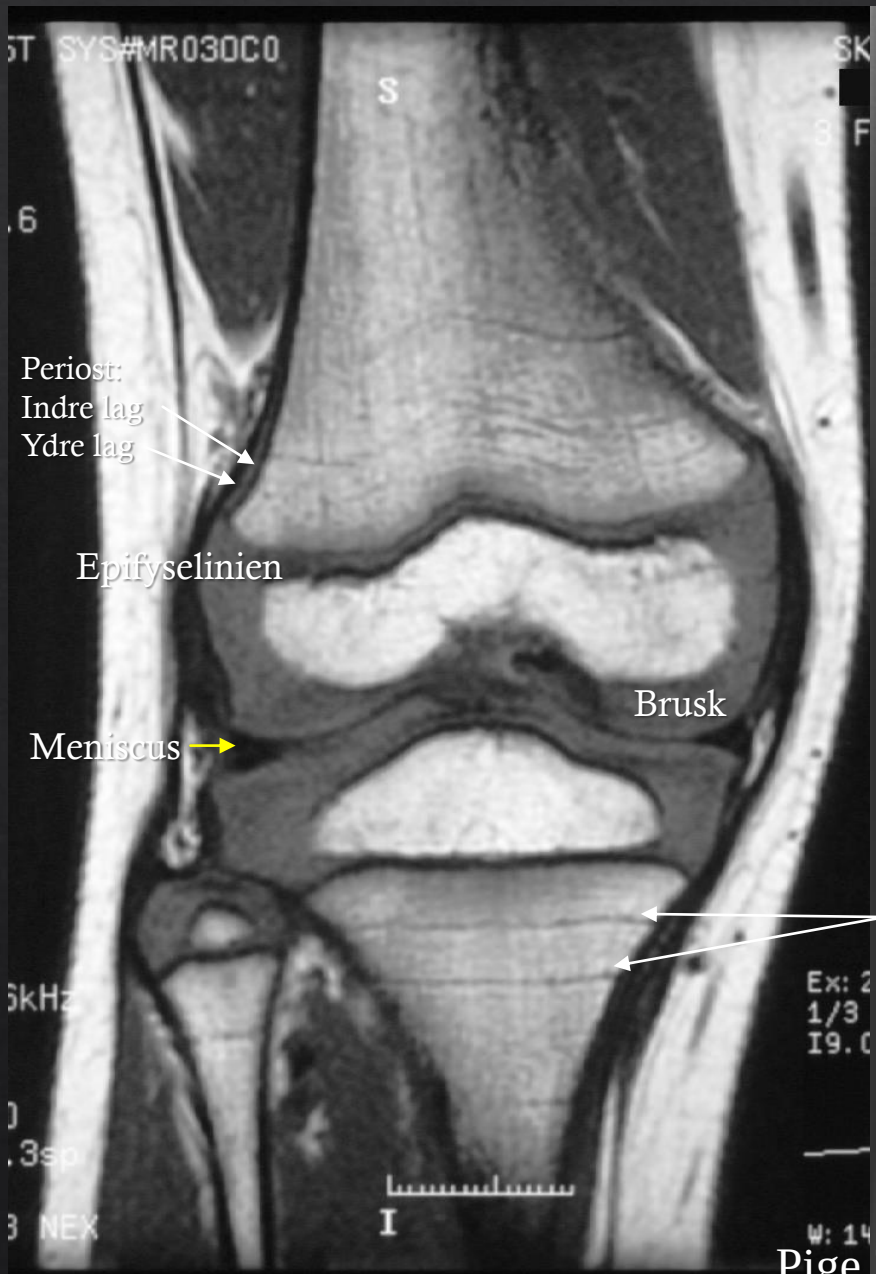

MR

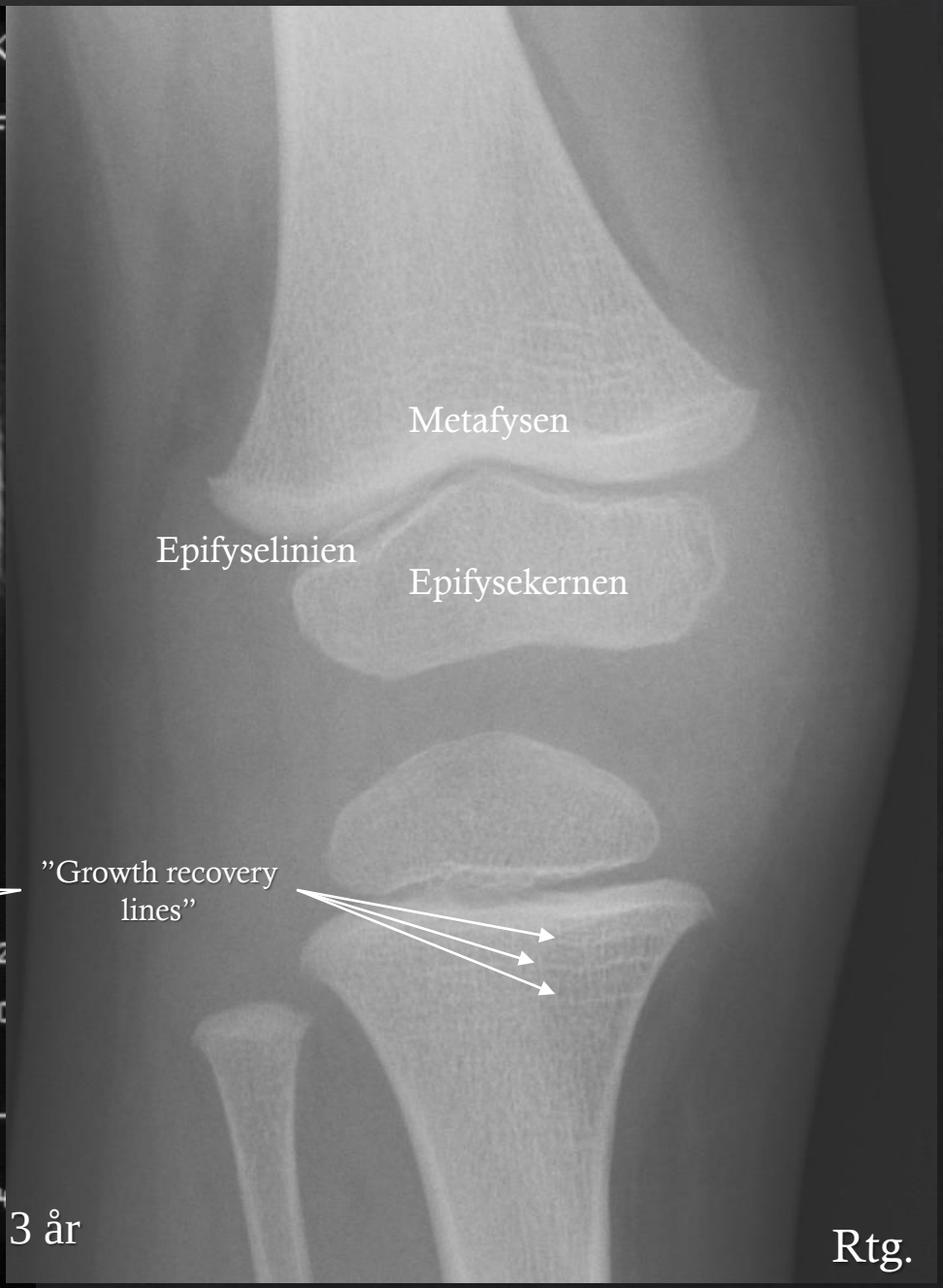

Pige 3 år

Rtg.

Rakit forandringer

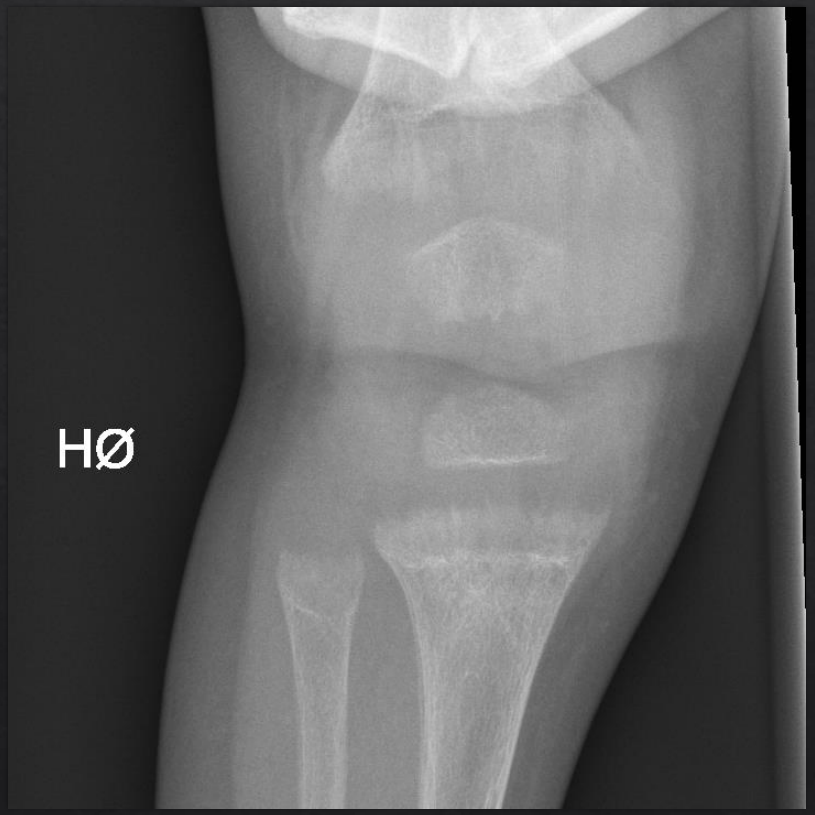

Normal undersøgelse til sammenligning

Crus

Rtg. Af højre crus i AP og sideplan.

Tværsnit gennem midten af crus

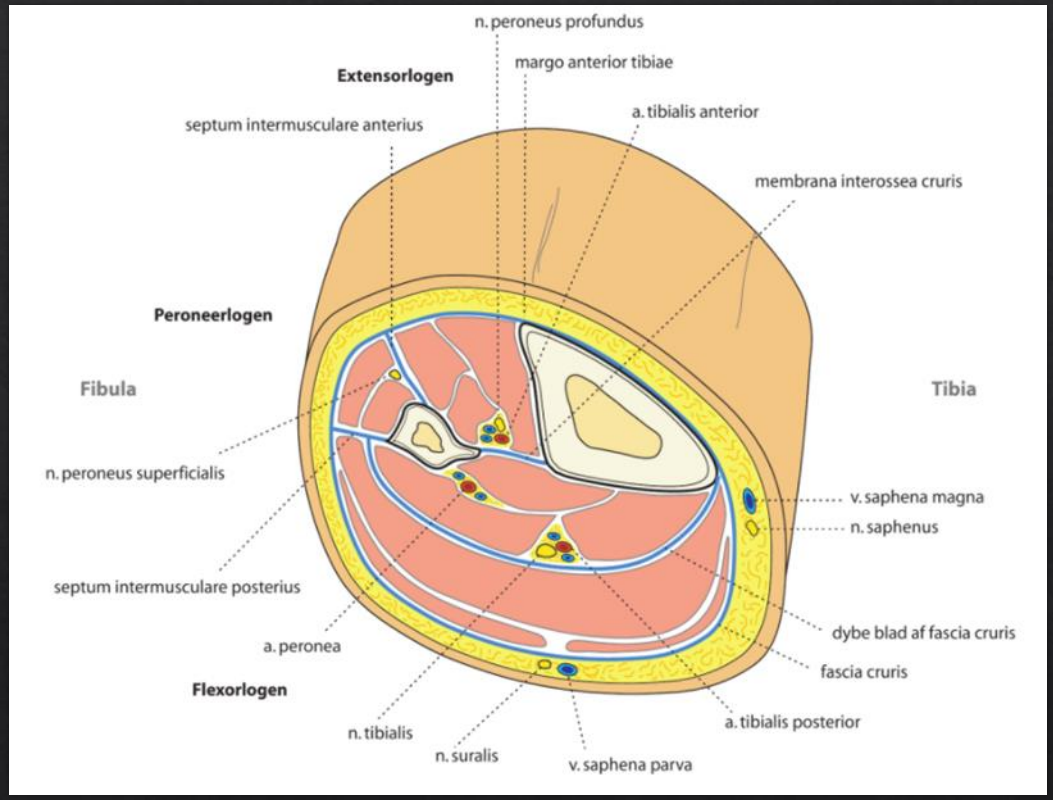

MR T1: Crurae Trv

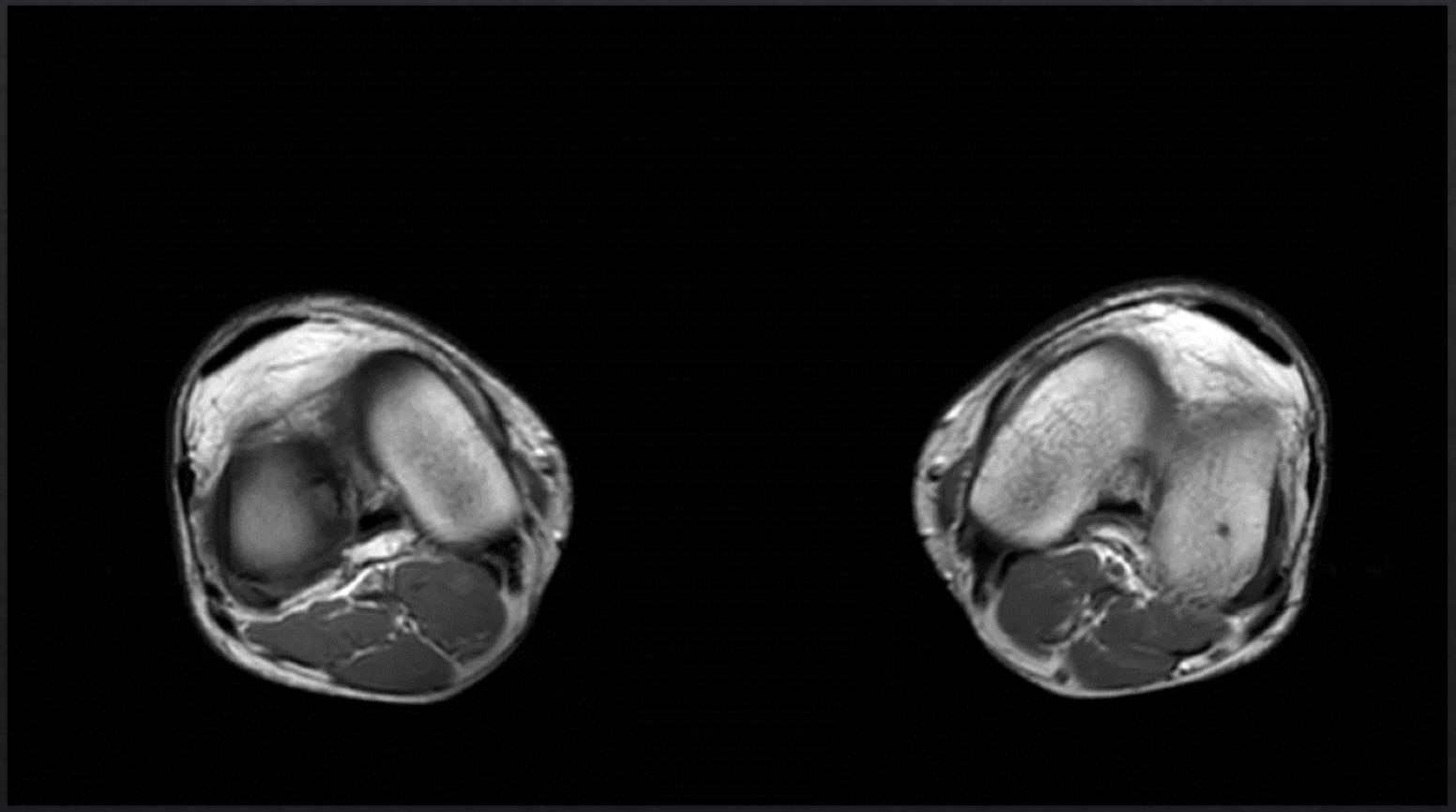

www.radiology.dk

MR T1: Crurae Trv

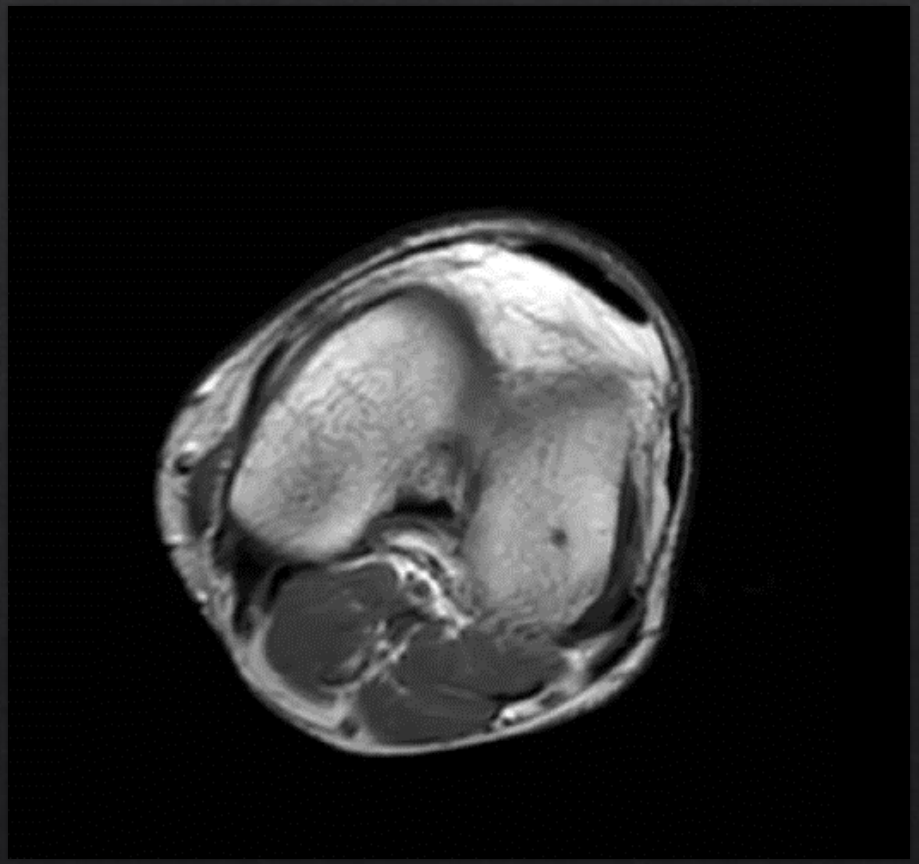

Fod

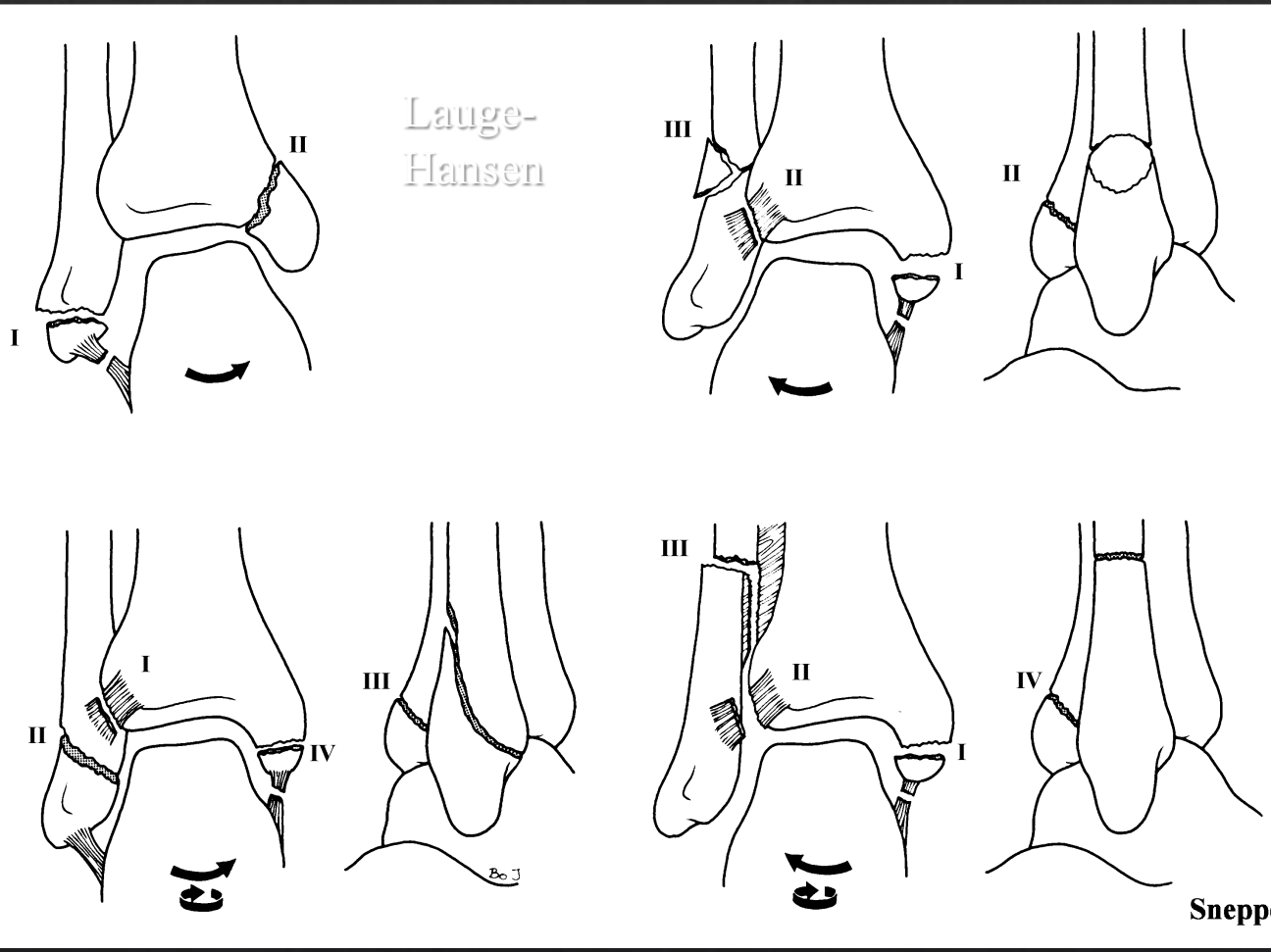
Lauge-
Hansen
II
I
III
II
I
II
II
I
III
II
IV
III
II
I
IV
Sneppen

AP L

skrå L

Lat. L

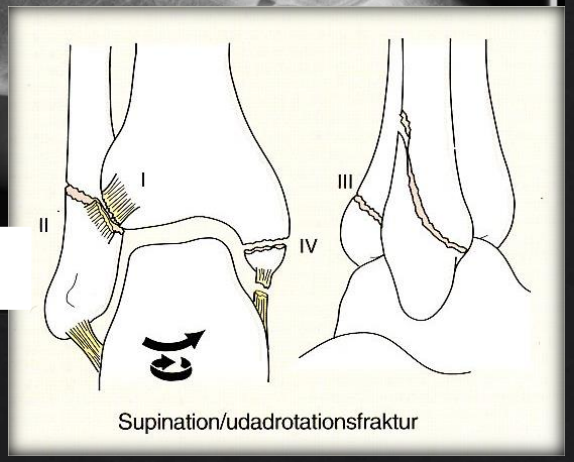

Supination/udadrotationsfraktur

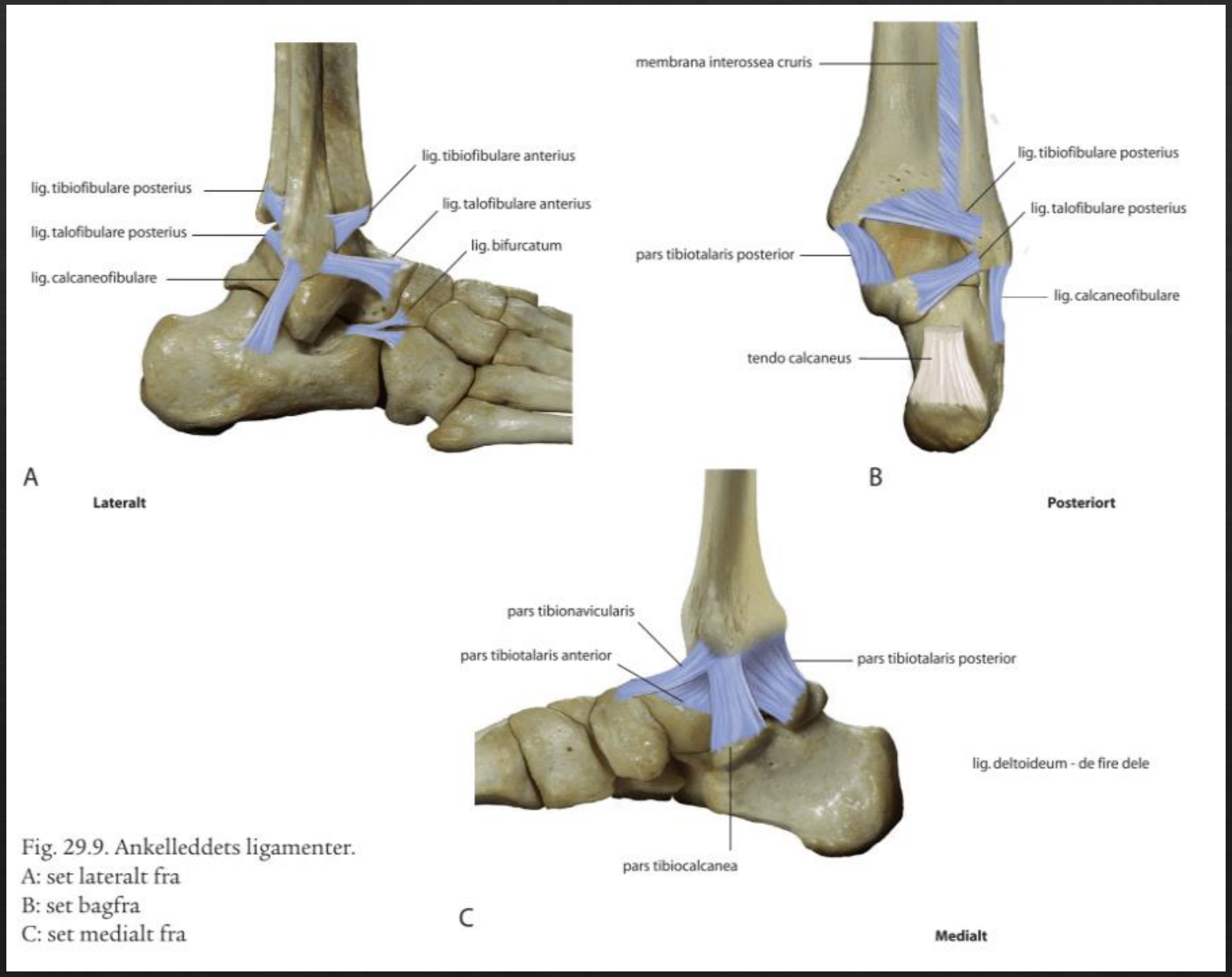

Fig. 29.9. Ankelleddets ligamenter.
A: set lateralt fra
B: set bagfra
C: set medialt fra

MR Trv T2 mDixon af fodled og fodrod

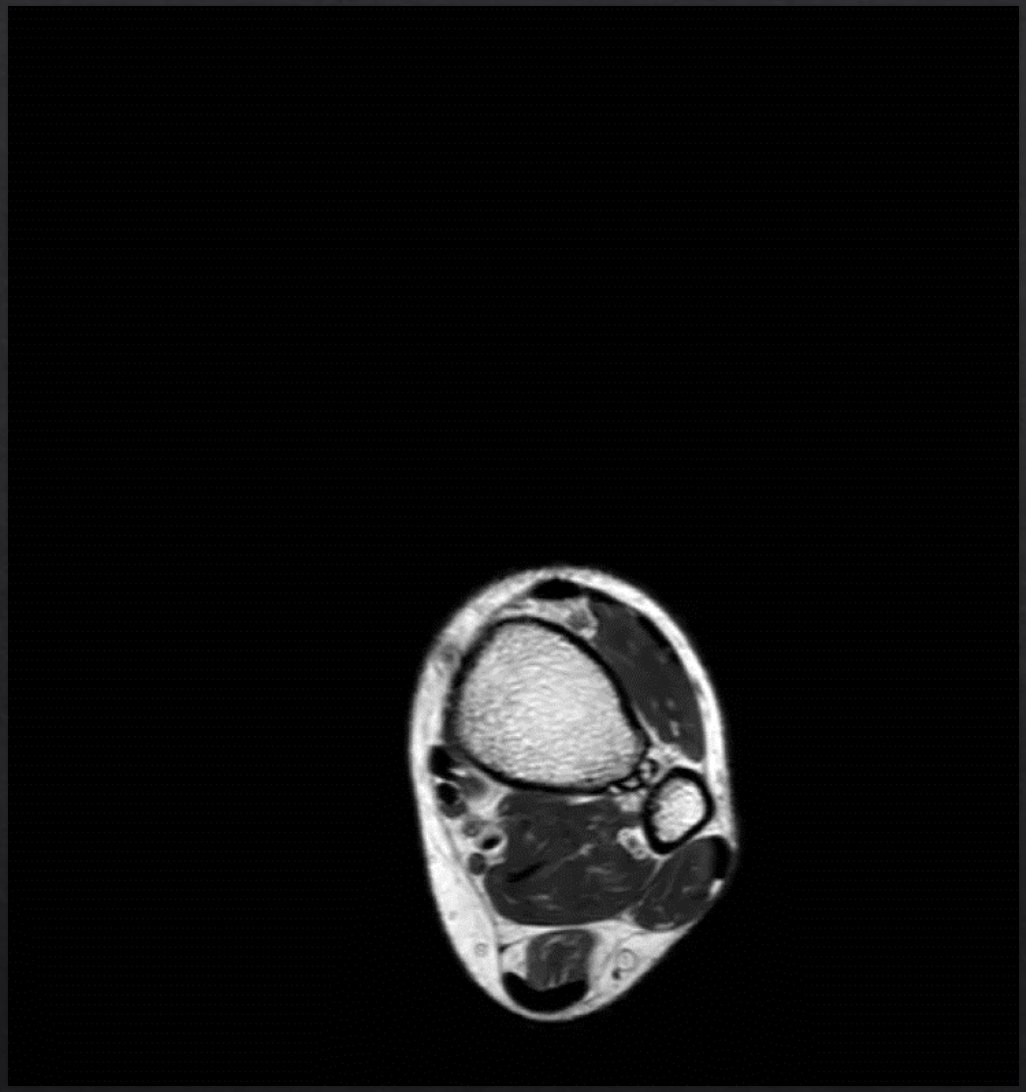

www.radiology.dk

MR Trv T2
mDixon af fodled
og fodrod

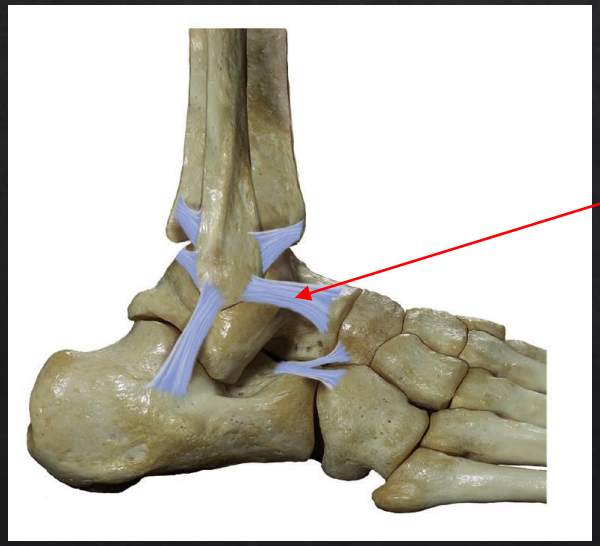

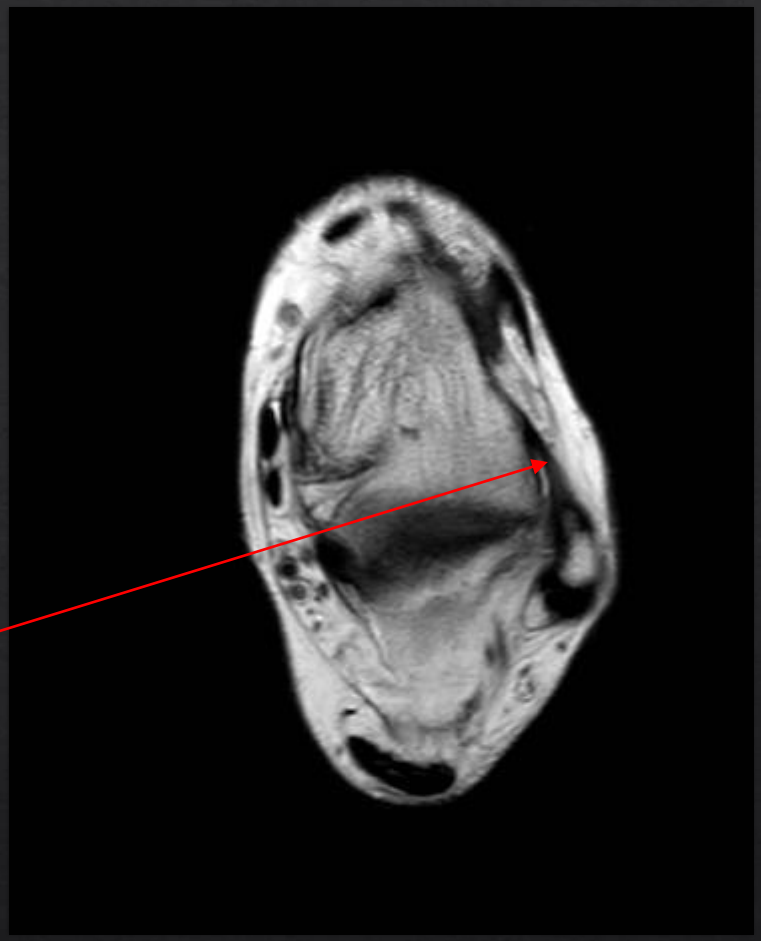

MR Trv T2
mDixon af fodled
og fodrod

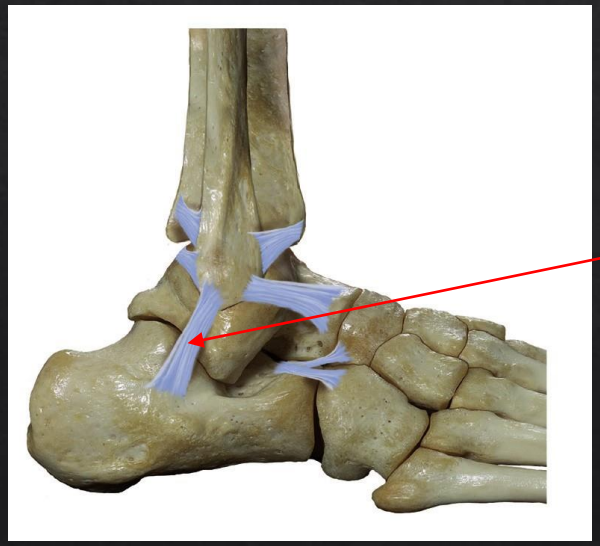

MR Trv T2
mDixon af fodled
og fodrod

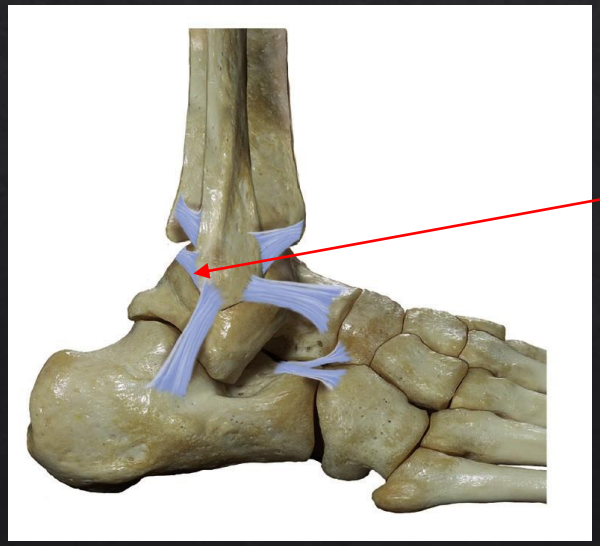

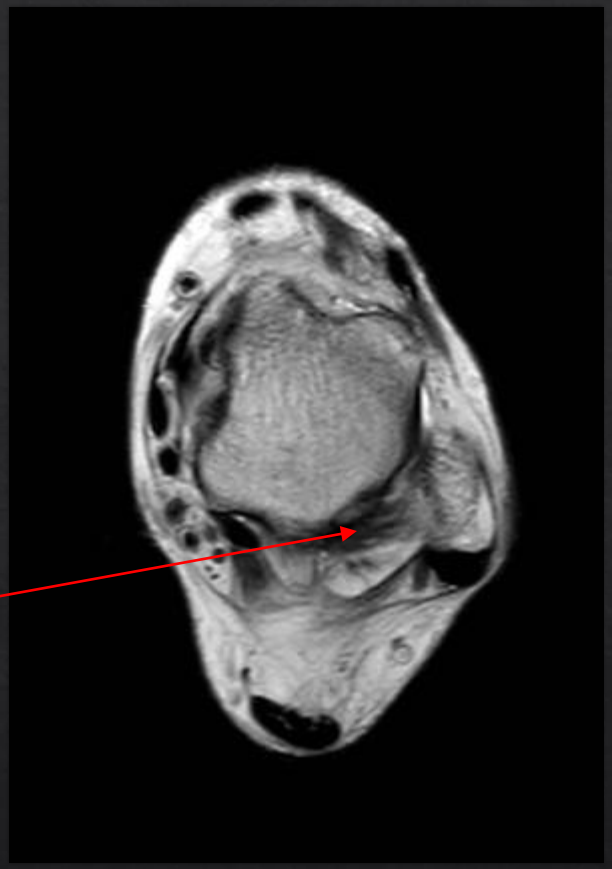

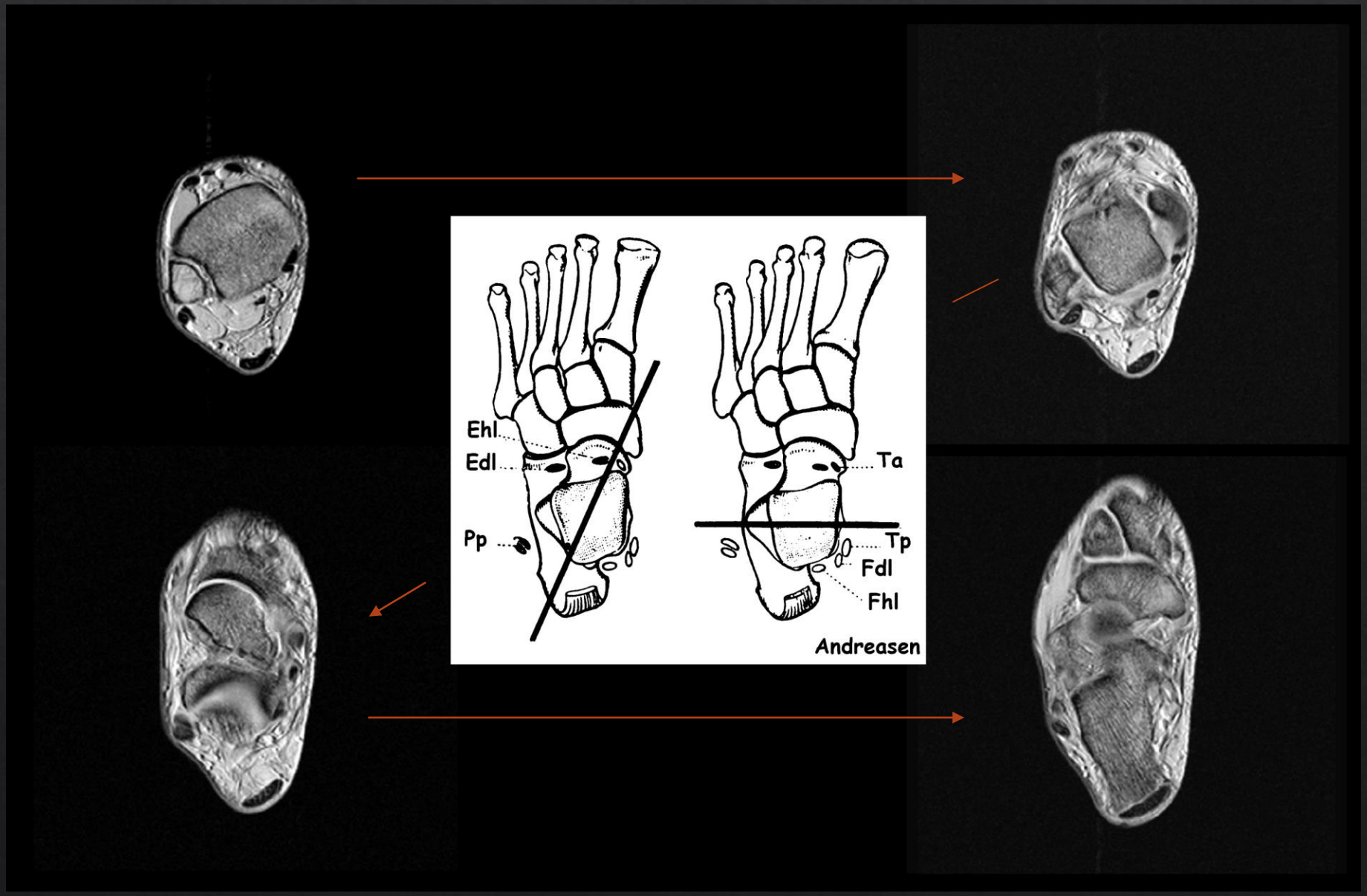
Ehl
Edl
Pp
Ta
Tp
Fdl
Fhl
Andreasen

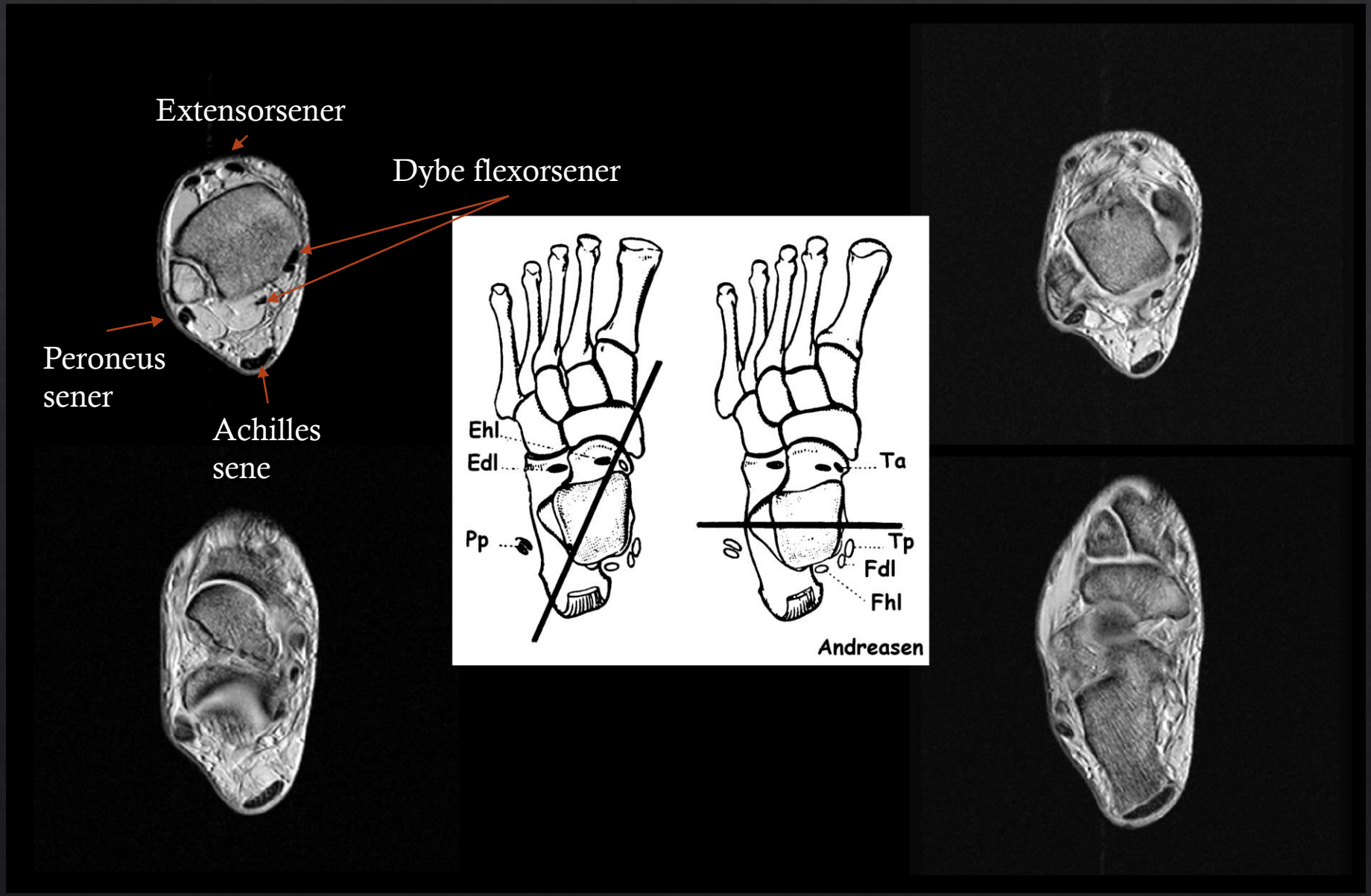
Extensorsener
Dybe flexorsener
Peroneus sener
Achilles sene
Ehl
Edl
Pp
Ta
Tp
Fdl
Fhl
Andreasen

1
2
3
4
5
6

7
8

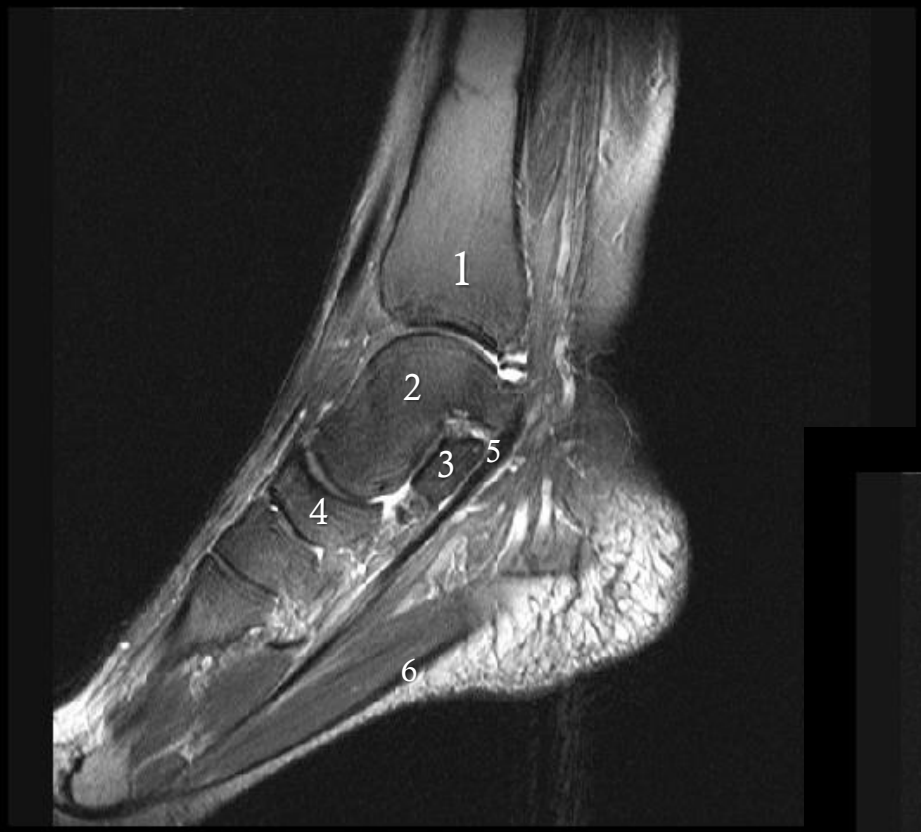

1) Tibia
2) Talus
3) Sustentaculum tali
4) Os naviculare
5) Flexor hallucis longus senen
6) Aponeurosis plantaris
7) Calcaneus
8) Achillessenen

CT højre fod 3D

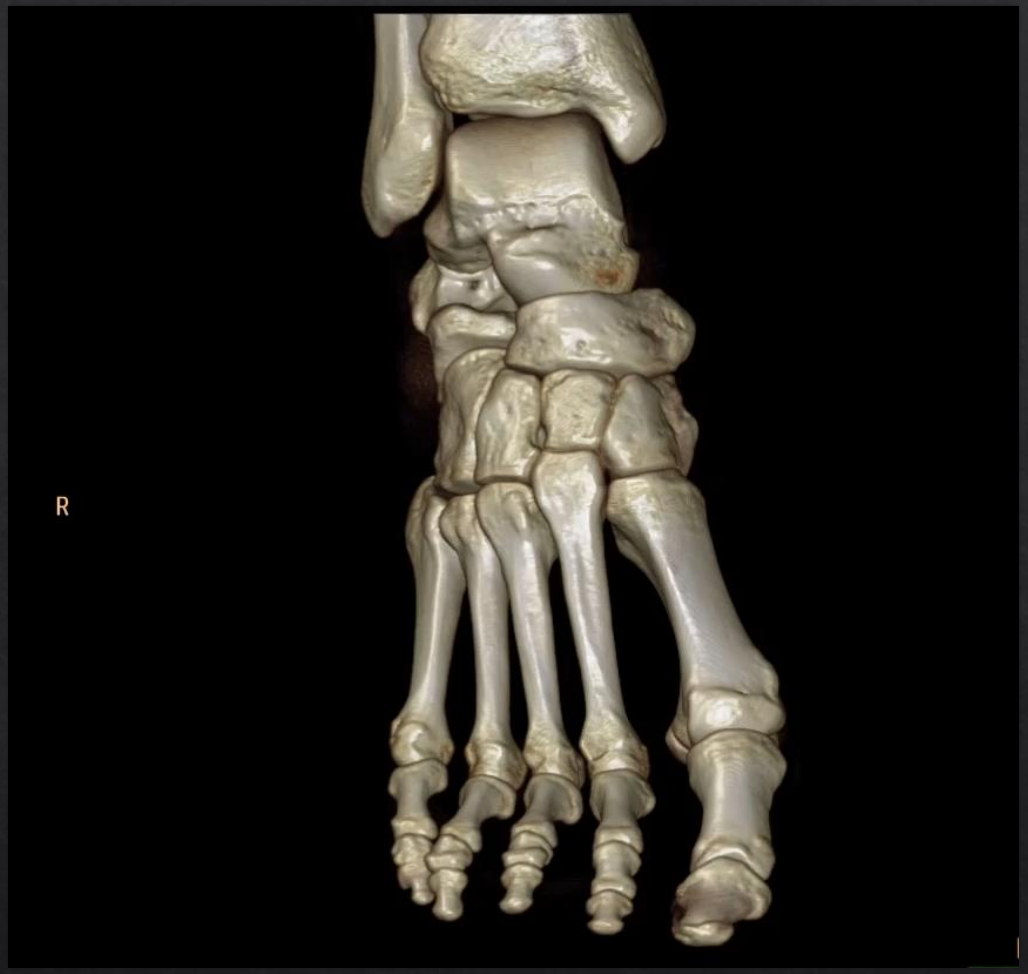

www.radiology.dk

Fodens akser

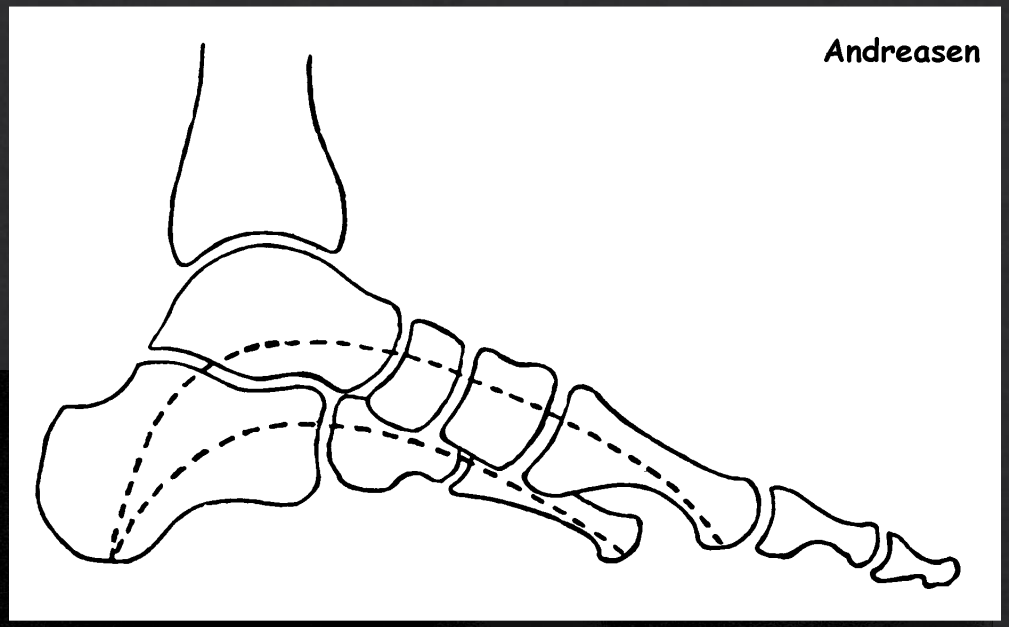
Andreasen

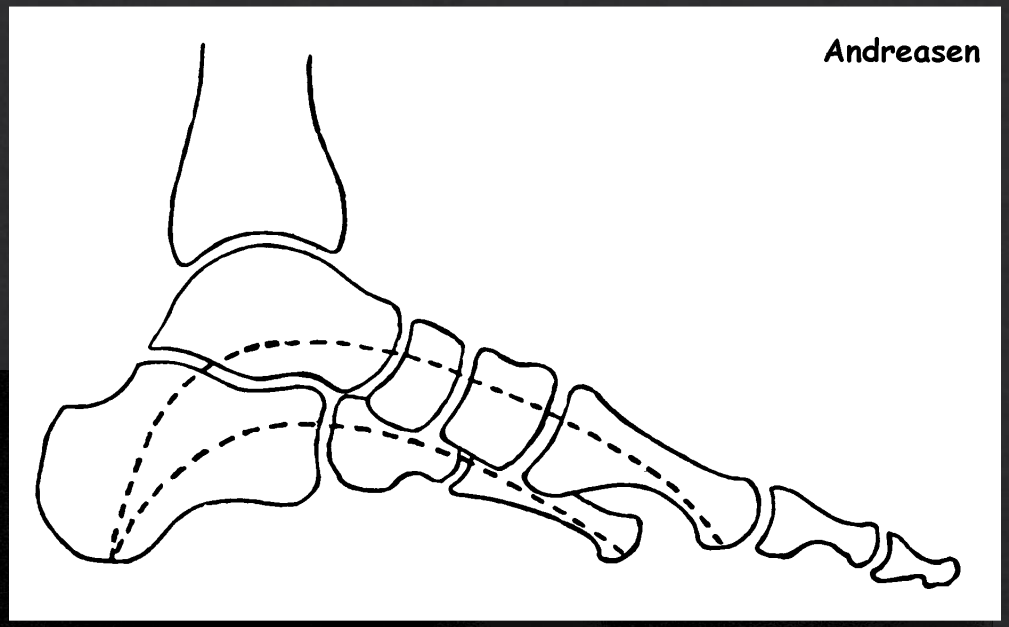
Andreasen

Hulfod (Pes cavus), mand 21 år.

Hulfod (Pes cavus), yngre mand.

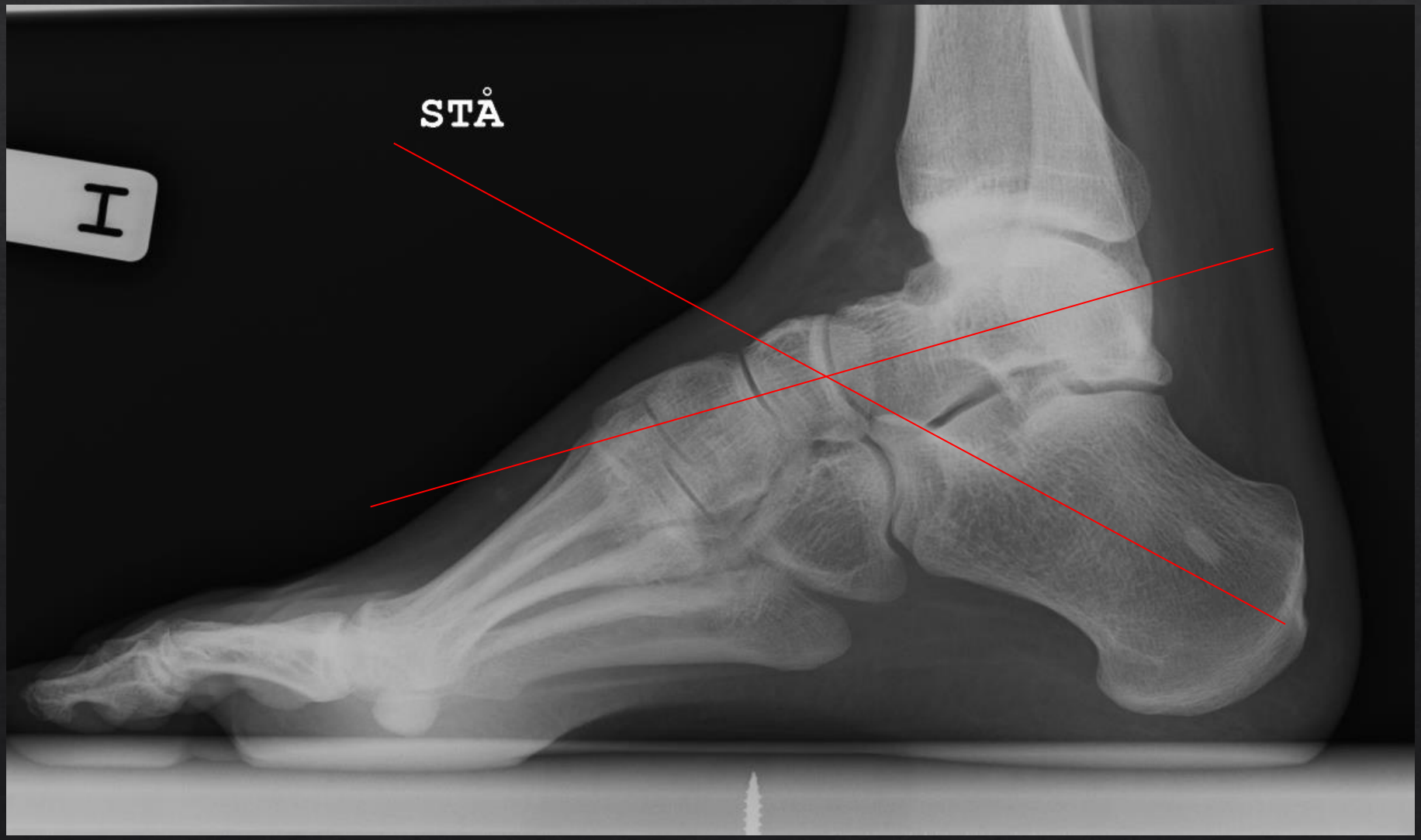

Platfod (Pes planus), dreng 12 år.
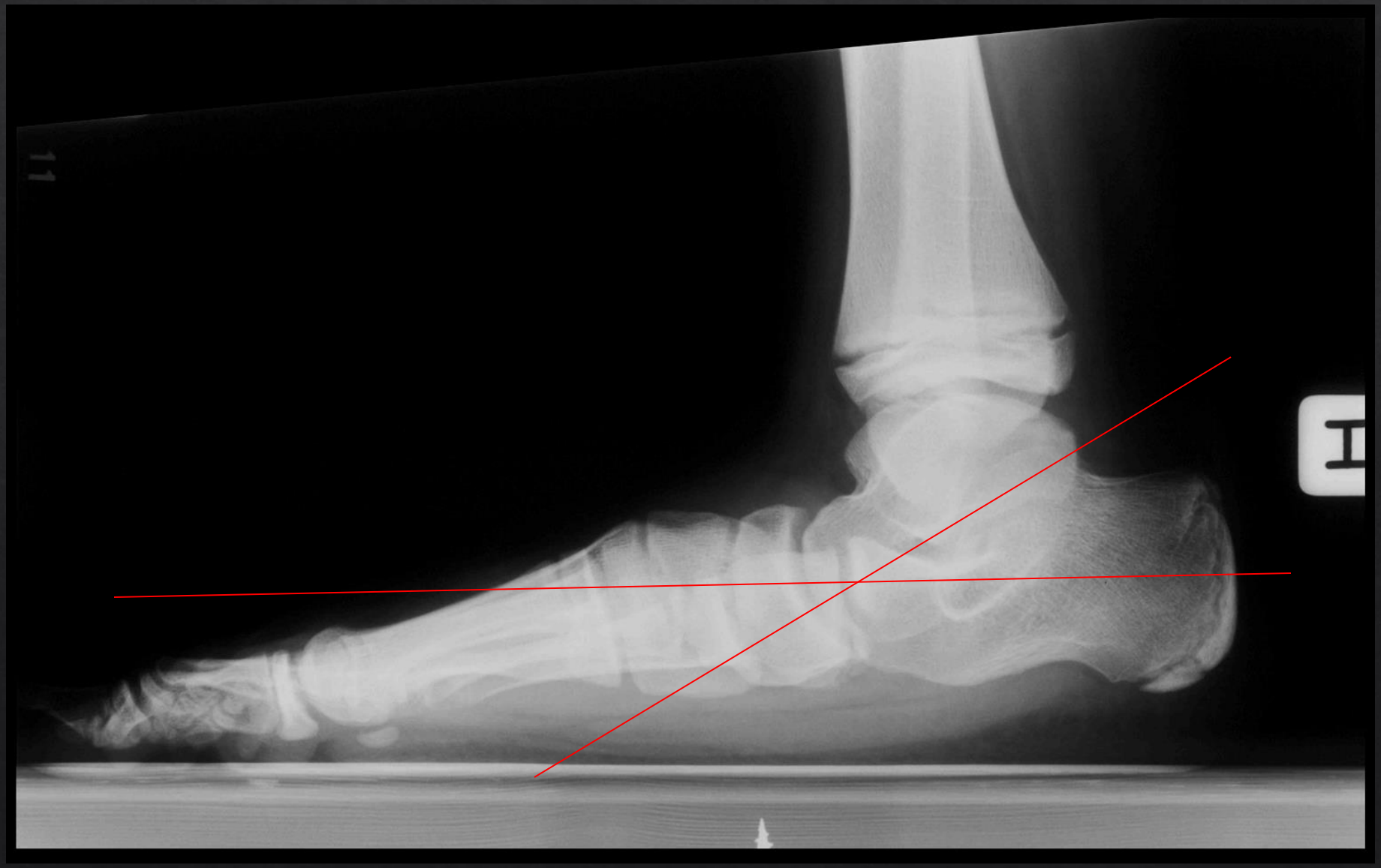
Platfod (Pes planus), dreng 12 år.